

8. A. 31

This work must be consulted
in the Boston Medical Library
8 Fenway

No. 3451.53

7.22



—NOCT 26

A. NOV 2

A TEXT-BOOK
OF
PATHOLOGICAL ANATOMY
AND
PATHOGENESIS

BY

3751.53
Vol. 2

ERNST ZIEGLER

PROFESSOR OF PATHOLOGICAL ANATOMY IN THE
UNIVERSITY OF TÜBINGEN

TRANSLATED AND EDITED FOR ENGLISH STUDENTS

BY

DONALD MAC ALISTER M.A. M.B.

MEMBER OF THE ROYAL COLLEGE OF PHYSICIANS; FELLOW AND MEDICAL
LECTURER OF ST. JOHN'S COLLEGE, CAMBRIDGE.

PART II—SPECIAL PATHOLOGICAL ANATOMY
SECTIONS I—VIII

NEW YORK
WILLIAM WOOD & COMPANY

1884



B. H.

352,028

Sept. 10, 1884

INDUSTRIAL PRINTING COMPANY,
STETINER, LAMBERT & Co.,
129 and 131 Crosby Street, New York.

PREFACE.

THE very rapid sale of Professor Ziegler's text-book in Germany has led to an unforeseen delay in the completion of the Second Part. Two editions of the sections already published having been exhausted, the Professor has been obliged to give to the preparation of a third edition of these the time he hoped to spend in completing the remaining sections. My own purpose was that the second volume of this English version should conclude the book, but in view of the requests which reach me from every side I have thought it better to bring out the first eight sections as an instalment than to put off the publication of the whole for another year. The third and concluding volume is already in hand, and will be of about the same size as the present. It will contain the sections on the Kidney, the Lungs, and the Nervous System, together with general indexes to the whole work.

In the third German edition the arrangement of the articles has been recast, and other changes of form have been made but in order to preserve the continuity of the English version I shall follow throughout the plan of the first volume. This plan has been generally approved, and it appears to be the most convenient for English students.

My renewed acknowledgments are due, and are very heartily rendered, to Professor Klein and Professor Greenfield, who have read and commented on each sheet as it passed through the press. Dr. George Thin has in like manner done me the kindness of reading the chapters on the Skin. Professor Ziegler has given me his ready help on many

points, and has enabled me to utilize his additions to the text of the later sections. Dr. Sims Woodhead courteously placed at my disposal the drawing of *Actinomyces* from which Fig. 174 *B* was engraved.

In view of the generous aid I have thus received I am encouraged to hope that little in recent Pathology has been overlooked which is likely to be of value to English students.

DONALD MAC ALISTER

ST. JOHN'S COLLEGE, CAMBRIDGE,
February 1884.

CONTENTS.

SECTION I.

BLOOD AND LYMPH.

	PAGE
CHAP. I. FUNCTIONS OF BLOOD AND LYMPH (Art. 251)	5
II. INTRAVASCULAR COAGULATION OR THROMBOSIS (Arts. 252-258)	7
III. CHANGES IN THE QUANTITY AND COMPOSITION OF THE BLOOD (Arts. 258-259)	17
IV. CHANGES IN THE BLOOD-CORPUSCLES (Arts. 260-262)	21
V. SOLID IMPURITIES IN THE BLOOD (Arts. 263-268)	27
VI. CHANGES IN THE LYMPH (Art. 269)	33

SECTION II.

THE VASCULAR MECHANISM.

VII. MALFORMATIONS AND MALPOSITIONS OF THE HEART (Arts. 270-272)	37
VIII. ATROPHY AND DEGENERATION OF THE HEART (Arts. 273- 277)	42
IX. HYPERTROPHY AND DILATATION OF THE HEART (Arts. 278- 279)	48
X. ENDOCARDITIS AND MYOCARDITIS (Arts. 280-284)	51
XI. INFECTIVE GRANULOMATA, TUMORS, AND PARASITES OF THE HEART (Art. 285)	57
XII. HYPOPLASIA AND DEGENERATION OF THE VESSELS (Art. 286- 288)	58
XIII. HYPERTROPHY AND HYPERPLASIA OF THE VESSELS (Art. 289)	62
XIV. INFLAMMATIONS OF THE VESSELS (Arts. 290-296)	63
XV. SCLEROSIS AND ATHEROMA (Arts. 297-300)	70
XVI. CHANGES IN THE CALIBRE OF THE VESSELS (Arts. 301-307)	74
XVII. RUPTURE OF THE COATS OF THE VESSELS (Arts. 308-312)	80
XVIII. THE LYMPHATICS (Arts. 313-316)	83

SECTION III.

THE SPLEEN AND THE LYMPHATIC GLANDS.

XIX. STRUCTURE AND FUNCTIONS OF THE SPLEEN (Arts 317-318) .	89
XX. DISORDERS OF CIRCULATION AND INFLAMMATIONS OF THE SPLEEN (Arts. 319-324)	92
XXI. DEGENERATIONS AND INJURIES OF THE SPLEEN (Arts. 325- 326)	97
XXII. INFECTIVE GRANULOMATA OF THE SPLEEN (Art. 327) .	99
XXXIII. HYPERPLASIAS AND TUMORS OF THE SPLEEN (Arts. 328-329)	100
XXIV. ATROPHY AND DEGENERATION OF THE LYMPHATIC GLANDS (Arts. 330-333)	103
[XXV. and XXVI. omitted by misnumbering.]	
XXVII. FOREIGN SUBSTANCES IN THE LYMPHATIC GLANDS (Arts. 334-335)	107
XXVIII. INFLAMMATIONS OF LYMPHATIC GLANDS (Arts. 336-342)	109
XXIX. TUMORS OF LYMPHATIC GLANDS (Arts. 343-347)	116

SECTION IV.

THE SEROUS MEMBRANES.

XXX. DEVELOPMENT OF THE SEROUS CAVITIES (Art. 348) .	123
XXXI. EFFECTS DUE TO DISORDERS OF THE CIRCULATION (Arts. 349-350)	125
XXXII. INFLAMMATIONS OF SEROUS MEMBRANES (Arts. 351-354)	128
XXXIII. TUBERCULOSIS OF SEROUS MEMBRANES (Arts. 355-357)	134
XXXIV. TUMORS AND PARASITES OF SEROUS MEMBRANES (Art. 358)	137

SECTION V.

THE SKIN.

XXXV. INTRODUCTORY (Art. 359)	141
XXXVI. DISORDERS OF CIRCULATION (Arts. 360-361)	143
XXXVII. DISCOLORATION and ATROPHY OF THE SKIN (Arts. 362- 365)	146

XXXVIII. INFLAMMATIONS OF THE SKIN.

- a. *Transitory eruptions with slight exudation: erythema, papulæ, urticæ* (Arts. 366-367) 150
- b. *Eruptions with considerable exudation: tubercula, squamæ, vesiculæ, pustulæ, crustæ* (Arts. 368-388) 152
- c. *Eruptions ending in necrosis, suppuration, ulceration, or granulation* (Arts. 389-392) 174

XXXIX. INFLAMMATORY HYPERTROPHIES OF THE SKIN (Arts. 393-396) 182

XL. NON-INFLAMMATORY HYPERTROPHIES AND TUMORS (Arts. 397-502) 186

XLI. AFFECTIONS OF THE SEBACEOUS GLANDS, HAIR, AND NAILS (Arts. 403-408) 196

XLII. PARASITIC AFFECTIONS (Arts. 409-413) 201

SECTION VI.

THE MUCOUS MEMBRANES.

XLIII. STRUCTURE AND FUNCTIONS (Art. 414) 209

XLIV. HYPERÆMIA AND HÆMORRHAGE (Arts. 415-416) 211

XLV. DEGENERATION, ATROPHY, AND HYPERTROPHY (Arts. 417-418) 213

XLVI. INFLAMMATORY AFFECTIONS (Arts. 419-427) 215

XLVII. INFECTIVE GRANULOMATA AND TUMORS (Arts. 428-431) 225

SECTION VII.

THE ALIMENTARY TRACT.

XLVIII. GENERAL CONSIDERATIONS (Art. 432) 233

XLIX. THE MOUTH.

Inflammatory affections: stomatitis (Arts. 433-435) 234

Parasitic affections (Art. 436) 238

Hypertrophy and Atrophy (Art. 437) 240

Tumors and cysts (Arts. 438-439) 242

Changes affecting the teeth (Arts. 440-441) 244

L. THE THROAT (Arts. 442-446) 247

LI. THE SALIVARY GLANDS (Arts. 447-448) 251

LII. THE ŒSOPHAGUS (Arts. 449-451) 253

LIII. THE STOMACH (Arts. 452-462) 258

LIV. THE INTESTINE (Arts. 463-479) 273

SECTION VIII.

THE LIVER AND PANCREAS.

LV. PIGMENTARY INFILTRATION OF THE LIVER (Arts. 480-481)	. 299
LVI. MALFORMATIONS AND MALPOSITIONS OF THE LIVER (Art. 482)	. 304
LVII. DISORDERS OF THE HEPATIC CIRCULATION (Arts. 483-484)	306
LVIII. ATROPHY AND DEGENERATION OF THE LIVER (Arts. 485-491)	. 309
LIX. HYPERTROPHY AND REGENERATION OF LIVER-TISSUE (Art. 492)	. 317
LX. INFLAMMATIONS OF THE LIVER.	
<i>Purulent hepatitis and Hepatic abscess</i> (Arts. 493-495)	. 319
<i>Chronic indurative hepatitis and Cirrhosis</i> (Arts. 496-498)	. 322
<i>Syphilitic hepatitis</i> (Arts. 499-500)	. 329
<i>Tuberculosis of the liver</i> (Art. 501)	. 332
LXI. TUMORS AND PARASITES OF THE LIVER.	
<i>Primary tumors</i> (Arts. 502-504)	. 335
<i>Secondary tumors</i> (Arts. 505-506)	. 338
<i>Animal parasites</i> (Art. 507)	. 340
LXII. THE GALL-BLADDER AND BILIARY DUCTS (Arts. 508-512)	. 341
LXIII. THE PANCREAS (Arts. 513-515)	. 345
INDEX OF AUTHORS CITED	. 349
INDEX OF SUBJECTS	. 354

INDEX OF FIGURES.

FIG.	PAGE.
118. Thrombus in process of organization	12
119. Diagrammatic section of a ligatured vessel	13
120. Section through a degenerating patch from the brain	33
121. Brown atrophy of the muscles of the heart	42
122. Fatty degeneration of the muscles of the heart	43
123. Fatty endocardium	43
124. Myomalacia cordis	46
125. Endocarditic vegetation	52
126. Sclerosis resulting from myocarditis	55
127. Fatty degeneration of the aorta and of a cerebral capillary	59
128. Calcification of the aorta	61
129. Acute aortitis	64
130. Syphilitic arteritis	68
131. Atheromatous cerebral artery	71
132. Dilated capillaries from the brain	77
133. Amyloid swelling of the adenoid reticulum	104
134. Chalky concretions	106
135. Lymphatic gland containing pigment-granule cells	107
136. Slate-colored bronchial gland	108
137. Large-celled hyperplasia of a lymphatic gland	112
138. Fibrous hyperplasia of a lymphatic gland	113
139. Tuberculosis of a lymphatic gland	114
140. Inflamed omentum	128
141. Adhesive pericarditis	131
142. Tuberculosis of the omentum	135
143. Senile atrophy of the skin	148
144. Syphilitic mucous patch	153
145. Blister due to a burn	155
146. Skin in erysipelas bullosum	156
147. Vesicle of herpes zoster	157
148. Vesicle of small-pox	158
149. Blister from a burn in process of healing	160
150. Skin in erysipelas bullosum	161
151. Syphilitic mucous patch	165
152. Infantile syphilitic pemphigus	171
153. Vesicle of small-pox becoming pustular	173
154. Lupus vulgaris	180
155. Venereal wart	183
156. Ichthyosis hystrix	187
157. Papillæ from a cutaneous wart	188
158. Section through a soft wart	189
159. Fibroma (neurofibroma) molluscum	190

	EACH.
160. Pustule of acne	193
161. Fungi from a favus patch	202
162. Cup or scutulum of favus	202
163. Hair affected with favus	203
164. Skin in scabies	205
165. Atrophy of the intestine	214
166. Catarrhal secretions	216
167. Colon in dysentery	218
168. Glandular atrophy and fibrous hyperplasia of the stomach	219
169. Croupous membrane from the trachea	220
170. Uvula in diphtheritis faucium	221
171. Uvula in diphtheritis faucium	222
172. Tuberculosis of the bronchial mucous membrane	225
173. Tuberculosis of the large intestine	226
174. <i>A</i> Destructive adenoma of the stomach	228
174. <i>B</i> Actinomyces from the tongue of a cow	239
175. Fibroid fold (état mamelonné) of the stomach	264
176. Gastric polypus	264
177. Colon in dysentery	285
178. Peyer's patch in typhoid	287
179. Tuberculosis of the large intestine	290
180. Pigmentary infiltration of the liver	300
181. Infiltrated liver-cells in pernicious anæmia	302
182. Simple atrophy of the liver	310
183. Atrophied liver-cells	311
184. Fatty liver-cells	311
185. Amyloid lobular capillaries	315
186. Micrococcus septicus in hepatic capillaries	320
187. Hepatic abscess: first stage	321
188. Recent interstitial hepatitis	323
189. Extravascular development of fibrous tissue	323
190. Intravascular development of fibrous tissue	323
191. Granular atrophic cirrhosis of the liver	324
192. Atrophic cirrhosis of the liver	327
193. Gumma of the liver	329
194. Syphilitic scar and gumma of the liver	330
195. Diffuse fibroid induration of the liver from congenital syphilis	331
196. Miliary tuberculosis of the liver	333
197. Carcinoma of the bile-ducts	336
198. Cavernous angioma of the liver	337
199. Cancerous embolus of a liver-capillary	339
200. Metastatic growth of cancer in the liver	339

SPECIAL
PATHOLOGICAL ANATOMY.

SECTION I.

BLOOD AND LYMPH.

CHAPTER I.

FUNCTIONS OF BLOOD AND LYMPH.

251. **Blood** and **lymph** are the essential juices of the body. They stand in the closest relation to the vital processes which go on in the tissues. By means of the blood, the constituent elements of the body are supplied with the nutrient substances and the oxygen which they require. By the blood and the lymph are conveyed away the waste and surplus matters which have ceased to be useful to the tissues.

The nutrient substances and the oxygen are derived from without. The former usually enter the body from the alimentary canal, the latter usually through the lungs. But most parts of the body are under certain conditions capable of directly assimilating both nutriment and oxygen. The channels of entrance are in such cases the smaller blood-vessels and lymphatics.

The matters which have to be removed from the tissues are partly surplus nutriment, partly the products of tissue-waste and metabolism. These matters are carried off either to be utilized elsewhere within the system, or to be ejected altogether.

Under normal conditions, the incomings and outgoings balance each other in amount.

The channels by which the normal constituents gain access to the blood and lymph may also serve to admit matters which are noxious or at least abnormal. These matters may be either wholly extraneous, or produced within the body itself in virtue of some morbid or abnormal metabolism. The result of their admission is a more or less enduring pollution of the blood and lymph. In many cases, the blood is able to eliminate them harmlessly and speedily, chiefly by means of the kidneys and the liver; but in other cases, the pollution is more permanent. The composition of the blood often suffers in consequence, and its renovation may not be effected until some of the tissues or organs have been more or less injured by malnutrition.

The abnormal matters which gain access to the blood may be in very various states of aggregation. Most commonly they are in the form of gases or liquids; but the blood is likewise not infrequently polluted by the admission of solid corpuscular matters. These latter have by far the greatest interest to the pathologist, for they are demonstrable by means of the microscope.

We cannot regard the blood as a liquid whose chemical composition is variable or indefinite. Experiment shows that the proportions of albuminoids, salts, iron, etc., which it contains are constant within narrow limits, and that its composition is maintained by nicely-adjusted assimilation and elimination of material. We must therefore look upon any serious variation from the normal in the composition of the blood as a pathological phenomenon.

The blood is in fact a definite living tissue.

Although the changes that occur in the composition of the blood are by no means so important as were formerly believed, though we no longer consider the juices and "humors" to be the seat of all diseases, yet we should be in error if we regarded the blood as nothing more than a solution of various chemical substances. The blood always contains living cells, and these fulfil definite vital functions. And even if the red corpuscles are so transformed from the ordinary cell-type that some deny their right to the title of living cells, the life and activity of the white blood-cells is unmistakable, and they are an essential constituent of the blood.

In disease, too, the blood comports itself as a living tissue. We may have localized death or necrosis in a solid tissue, and we may likewise have a localized death of the blood. The retrogressive and formative changes in cells and intercellular substance, which we have recognized as the manifestation of diseased function in the solid tissues, have their analogues in the elements of the blood. Many of the morbid processes affecting the blood are thus manifested not merely by changes in its chemical composition, but by simultaneous changes in the form and quantity of its morphological elements; and in many diseases the morbid activity of the white blood-cells plays a highly important part.

CHAPTER II.

INTRAVASCULAR COAGULATION OR THROMBOSIS.

252. We have already seen (Art. 35) that when blood dies it usually coagulates, that is to say—solid masses of fibrin are formed in the plasma, the masses consisting of granules or granular fibrils or homogeneous flakes. When coagulation occurs within the vessels during life the process is called **thrombosis**, and the coagulum is called a **thrombus**.

On SCHMIDT'S hypothesis the coagulation of the blood depends on the union of two albuminoid bodies, fibrinogen and fibrinoplastin (or paraglobulin), in presence of a third factor or ferment (Art. 35). Taking the fibrinogen as furnished by the plasma, and the other factors as furnished by the colorless elements of the blood, coagulation is evidence of the death of the latter in whole or in part.

Coagulation may take place in blood which is at rest, or in blood which is in motion; and the appearance of the thrombus is different in the two cases. In blood at rest coagulation takes place throughout the entire mass simultaneously. The thrombus is thus dark-red or brown in color, and consists of granular and fibrous clots of fibrin containing multitudes of red corpuscles and a few white corpuscles. **Red thrombi** of this kind are most commonly formed in occluded or highly engorged vessels. When recent they are soft and full of serum. Afterwards they become firmer, tougher, and drier, the fibrin contracting and squeezing out the serum. They become at the same time paler and grayer; the decolorization proceeds in fact by the same steps as in extravasated blood (Art. 68).

When coagulation begins in blood which is still flowing, the entire mass does not coagulate at once; minute flakes separate out, consisting chiefly (according to ZAHN) of white blood-cells with a varying number of red blood-cells. According to the number and arrangement of these latter the thrombus may be white or gray, or pale reddish, or mottled and stratified.

In the case of pure **white thrombi**, only the colorless elements of the blood separate out. When the necessary local conditions for coagulation are set up at any spot (on the intima of the heart or of a vessel) the clots adhere to the surface, and gradually increase in size by successive additions. At first the cellular elements of the mass are distinguishable; but in twenty-four hours the outlines of the cells disappear,

and the mass is transformed into homogeneous or finely-granular fibrin.

The thrombus grows by the addition of colorless elements like those in which it began. If red corpuscles are entangled with the others, it may gradually become more and more tinged with red. If the red corpuscles are precipitated *per saltum* or intermittently, the thrombus will exhibit strata of red and white. This alternate precipitation, which leads to the formation of **mottled thrombi**, is most likely to happen if the blood is alternately at rest and in motion at the site of the deposit.

The fundamental investigations on the subject of thrombosis are those of VIRCHOW (*Gesamm. Abhandl.* 1856, *Hand d. spec. Path.* 1.), who made out by experiment the conditions of intravascular coagulation and its effects on the circulation. ZAHN has shown (*Virch. Arch.* vol. 62, and *Rev. méd. de la Suisse rom.* 1881) that the formation of a thrombus in the blood-vessel of a frog may be directly observed under the microscope; one has only to injure the vessel mechanically or place on it a crystal of common salt; and coagulation at once begins. In this way the behavior of the white corpuscles has chiefly been made out. Quite recently BIZZOZERO (*Centralb. f. d. med. Wiss.* 1882, *Arch. ital. de biologie* 1., and *Virch. Arch.* vol. 90) has observed in living blood certain small colorless disc-like bodies, about half the size of the ordinary white corpuscles. These he calls "*Blutplättchen*" or blood-plates, and regards as identical with HAYEM'S hæmatoblasts (Art. 35). In blood taken from the vessels in the usual way they break up into the knots of granules described by MAX SCHULTZE and others. According to BIZZOZERO coagulation takes place when the blood-plates begin to break up in a liquid containing fibrinogen; and he maintains that they form the essential constituent of white and mottled thrombi. RAUSCHENBACH, a pupil of SCHMIDT'S, has criticised these statements in a recent inaugural dissertation (Dorpat 1882). See also WOOLDRIDGE, *Du Bois-Reymond's Arch.* 1883.

253. Thrombosis depends upon two factors; one is the morbid alteration of the vessel-wall, the other the retardation or stoppage of the blood-current. In most cases the two factors are in action simultaneously.

In normal conditions coagulation is prevented by the ever-renewed contact of the blood with the living endothelium of the vessel-wall (BRÜCKE). If the endothelium die in consequence of disease of the inner coat of the vessel, or if the blood is in part prevented from fresh contact with the endothelium by stagnation or cessation of the current, the influences which inhibit coagulation are interfered with. In accordance with this view we find that thrombosis is commonest where there is degeneration or inflammation of the lining membrane of the vessels or the heart, or where the circulation is impeded by such causes as compression or occlusion or dilatation of the vessels, fatty change in the heart, etc. Direct injury of the vessel-wall, if it extend to the intima, likewise leads to thrombosis. If a vessel be perforated by a small opening, the wound is quickly closed by white corpuscles which deposit themselves around and over the opening, while a white thrombus gradually forms and projects into the lumen of the vessel.

The various forms of thrombus are distinguished according to their relation to the lumen of the vessel. **Parietal thrombi** are seated on the walls, **valvular** thrombi on the valves of the heart or of the veins. If the thrombus occludes the vessel it is called **obliterating**. The first deposit is spoken of as primary or autochthonous, the accretions superimposed on it as secondary or induced. By such accretions a parietal thrombus may grow into an obliterating one. In this way, too, it not seldom happens that a thrombus originally white or mottled is covered over with a red thrombus: the first deposit takes place in blood which is still moving, this by degrees occludes the vessel, the current is stayed, and the blood then coagulates as a whole. The reverse occurs when an obliterating red thrombus contracts, and leaves the channel partly free again. Both cases are illustrated in the **marasmic thrombosis** of cachectic anæmic patients; in them the vascular system seems too capacious for the diminished quantity of blood in circulation, and in consequence the current is here and there abnormally slow or ceases altogether.

Thrombosis may occur in any part of the vascular system. Cardiac thrombosis usually begins in the auricles, or in the crevices between the trabeculæ carneæ. In both sites the thrombi start from the deeper folds and involutions of the endocardium, but by continued apposition of fibrin they may grow into large polypoid masses projecting into the cavity, and are then spoken of as **cardiac polypi**. Coagula form in like manner upon the surfaces of inflamed valves. Both the parietal and the valvular forms of cardiac thrombi may grow to a very large size, and fill out the greater part of the auriculo-ventricular cavity.

Thrombosis of the larger arteries may occur in the most various situations. In marasmic patients with highly degenerate arteries parietal thrombi, both white and mottled, may be formed in the aorta and adhere firmly to the inner coat. In the veins thrombi are most commonly formed in the pockets of the valves; whence they grow out and become obliterating thrombi. Or a thrombus primarily formed in a small tributary vein may grow out into the lumen of a larger vein. For example, thrombosis originating in a small vein of the lower limb may ultimately extend continuously till it reaches the vena cava inferior or even the heart itself. Thrombosis of the smallest vessels is usually the result of some disorder of the tissues, chiefly of the nature of inflammation or necrosis.

Post-mortem clots. Thrombi which have been formed during life are in general easily distinguished from clots formed *in articulo mortis* or *post-mortem*. After death the blood usually coagulates in such a way that the red corpuscles are entangled and included in the clots; on post-mortem examination we find the vessels containing soft dark-red gory masses. Sometimes however the corpuscles have time to separate from the plasma before the fibrin is formed; in such cases the clots are soft, moist, somewhat elastic, yellowish, and faintly opalescent. From these somewhat bacon-like clots the true white or mottled thrombi are distinguished by their grayish and more opaque appearance, and by their more or less marked stratification. They are moreover firmer, drier, and less elastic;

when torn across the surface is corrugated or step-like; and finally they adhere to the wall of the vessel and generally distend it (HUMPHREY), while the post-mortem clots are free. Under the microscope the thrombi are seen to contain a larger proportion of white blood-cells than the post-mortem clots.

It is less easy to distinguish red thrombi from red post-mortem clots. The chief characters of the former are their greater firmness and dryness, and their adhesion to the vessel-wall. In less recent thrombi signs of decolorization appear, by which the dark-red of freshly coagulated blood passes into a lighter and brownish-red. Not uncommonly we may find true thrombi overlaid and concealed by post-mortem coagulations.

With regard to the effects of thrombosis upon the circulation see Arts. 22-25 and 30.

254. Issues of thrombosis. The fully-developed thrombus is a somewhat firm and dry mass adhering to the lining membrane of a vessel or of the heart, its color and structure varying as we have described. The comparatively small quantity of liquid it encloses is explained by the fact that the fibrin after its separation always shrinks, and so squeezes out the liquid from its meshes. This shrinking, when it occurs in an obliterating thrombus, may leave the channel of the vessel open once more. In many instances the contraction due to shrinking is very considerable. The fibrin is transformed into a dense mass, which may persist unchanged for a long time and ultimately becomes calcified. It is thus that the chalky concretions called **phleboliths** are formed in the veins. In the same way thrombi which are seated on roughened surfaces in the aorta or valves of the heart may become calcified; and may become sheltered from secondary deposits by the growth of an endothelial covering over them.

Contraction with calcification is what we may call a favorable issue of thrombosis. The very common issue of thrombosis in softening is much less favorable. Softening is distinguished as simple or red softening, and puriform or yellow softening. In **simple or red softening** the central parts of the thrombus are first of all changed into a grayish or reddish pulp, consisting of broken-down and shrunken red corpuscles, pigment granules, and colorless granular detritus. If the softening then extends to the surface layers, and if the blood-current is still flowing over the thrombus, the products of disintegration may be carried into the general circulation. This occurs both in the case of cardiac polypi and in venous thrombosis, especially when the tip of a thrombus projects from the orifice of a small vein into the channel of a larger in which the blood is still flowing. The result is the formation of emboli (Arts. 30 and 37; and 257).

The most unfavorable issue of all is the **puriform or yellow softening** of the thrombus. In this case the thrombus is transformed into a dirty or reddish yellow, fœtid, pus-like cream or pulp. This contains a multitude of pus-corpuscles and a large proportion of a finely-granular matter, which consists in part of fatty and albuminous detritus and

in part of micrococci. The latter frequently form groups or colonies, and are probably to be regarded as the exciting cause of the softening process. Such puriform thrombi act destructively on the surrounding tissues and set up inflammation. The intima of the vessel becomes turbid or opaque; and suppurative inflammation begins in the tunica media and tunica adventitia, extending to the tissue inclosing the vessel. Soon the entire thickness of the vessel-wall is infiltrated, and takes on a dirty-yellowish or grayish appearance. Ultimately the tissues undergo putrid disintegration (Art. 291). If the puriform matters are carried by the blood-current to distant spots, they there produce necrotic and putrefactive changes in the tissues, and set up suppurative inflammation.

The entire process, in which puriform softening of a venous thrombus is associated with suppurative inflammation of the vessel-wall, is described as purulent **thrombophlebitis**. It is due in the first instance to the causes which lead to thrombosis, and in the second, to the access of micrococci to the thrombus. In other cases, the inflammation of the vessel-wall is primary, and the thrombosis a secondary effect. The purulent form is most commonly met with in the neighborhood of septic wounds and ulcers.

255. The most favorable issue of thrombosis is in **organization** of the thrombus. By this is meant the replacement of the fibrin and corpuscles by vascularized fibrous tissue.

The new fibrous tissue is mainly the product of an inflammatory process; it is developed from migrated white blood-cells. Regenerative multiplication of the endothelial cells plays but a subordinate part or none at all. The thrombus itself takes no active share in the process; it is a lifeless mass, a foreign body, and as such sets up inflammation in its neighborhood. The inflammation runs the same course as other constructive or plastic inflammations. The histological changes follow exactly on the lines of those described in the Arts. 108-111; and the behavior of the tissues towards the foreign body (the thrombus) is identical with that described in Arts. 112-116. The process by which a thrombus is organized resembles most closely the plastic inflammation of a serous membrane. A blood-vessel has indeed a certain anatomical analogy to the serous cavities, being mainly distinguished by its particular configuration and by the special structure of its walls.

In the first stages of the organizing process we observe that the vessel-wall is here and there infiltrated with small leucocytes, the infiltration appearing in the outer and middle coats (Fig. 118 *e*), as well as in the inner coat (*f*). Presently migratory cells begin to accumulate, partly within the lumen of the vessel (*g*), partly within the substance of the thrombus, and partly between the latter and the vessel-wall. The first cells which migrate are small and round, and their nuclei are strongly stained by coloring reagents. Presently larger cells appear, with clear

vesicular nuclei (*h*); these have been developed out of the migratory cells. They are of various forms, rounded, elongated, or ramified (*h*). These larger cells are the formative or fibroplastic cells. When they have multiplied sufficiently, so that they become contiguous, they are gradually transformed into fibrous tissue. New blood-vessels are simultaneously developed, and at length the new-formed tissue is vascularized throughout.

This is the general course of the process, but considerable variation may take place in details. Thus, if the thrombus result from ligature, in a young and healthy patient, the accumulation of leucocytes will be

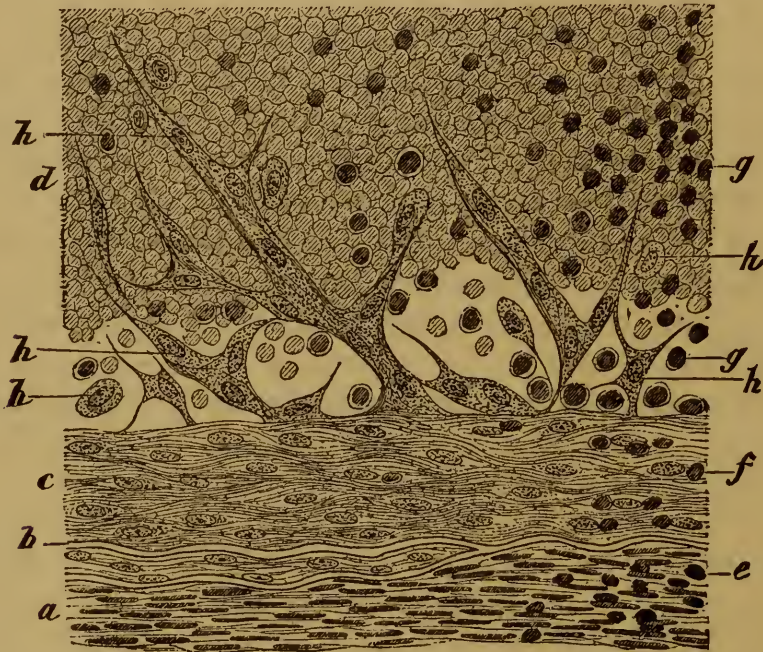


FIG. 118.—SECTION OF A THROMBUS IN PROCESS OF ORGANIZATION.

(From the femoral artery of an aged man three weeks after ligature : hæmatoxylin staining : $\times 350$.)

- | | |
|---|--|
| <i>a</i> , tunica media. | <i>e</i> , cells infiltrating the media. |
| <i>b</i> , fenestrated elastic membrane. | <i>f</i> , cells infiltrating the intima. |
| <i>c</i> , intima thickened by previous inflammation. | <i>g</i> , leucocytes, partly within the thrombus, partly between it and the intima. |
| <i>d</i> , coagulated blood. | <i>h</i> , various kinds of formative cells. |

much more marked than in such a case as is represented in Fig. 118 : in this case the patient was old, and his arteries had already undergone a certain amount of morbid change. The accumulation of leucocytes may become so great as to give the thrombus the appearance of a mass of granulation tissue. The duration of the process also varies greatly. By operating on one of the lower animals, we can be sure of finding the thrombus completely vascularized in twelve days. In the case figured above, the first formative cells are developing three weeks after the ligature.

The leucocytes are derived from the *vasa vasorum* and the vessels in the neighborhood of the occluded vessel. They enter chiefly from the

zone of ligature, at the points where the inner coat is torn through and where the injury to the vessel-wall is greatest. The new vessels are likewise derived from the *vasa vasorum*, though blood channels are also opened up from the side of the unoccluded lumen of the old vessel. The diagram (Fig. 119) may help to make clearer the appearance of an organized thrombus after ligature, and its relation to the walls of the vessel. It represents in a general way a longitudinal section through the cicatrix resulting from ligature.

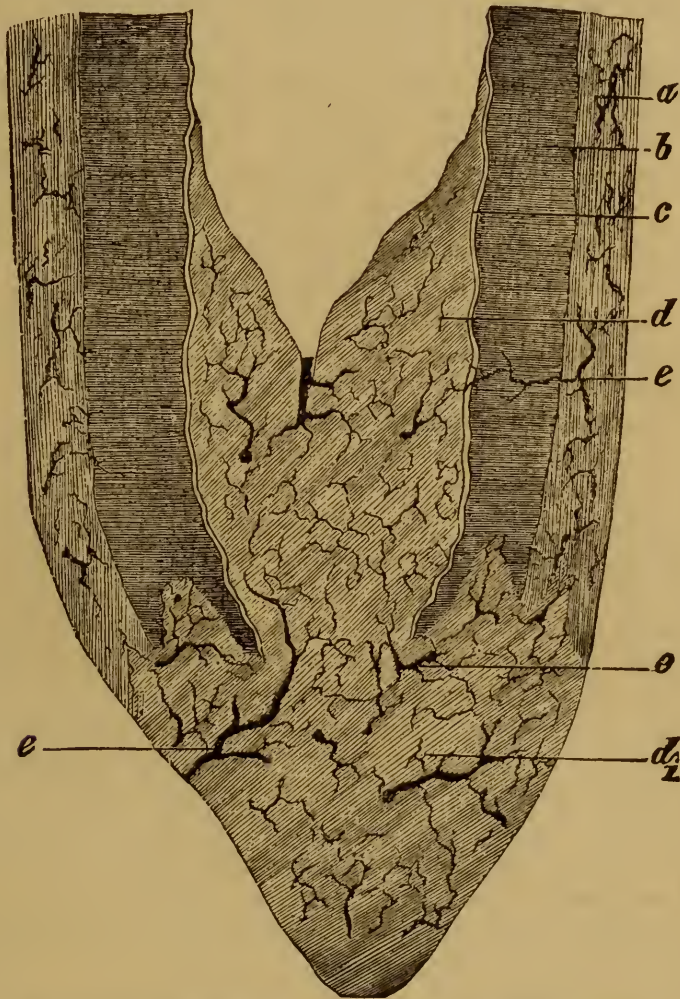


FIG. 119.—DIAGRAMMATIC SECTION OF A LIGATURED VESSEL.

(The thrombus is supposed to be entirely replaced by vascular fibrous tissue.)

a, adventitia.

b, media.

c, intima.

d, new-formed fibrous tissue within the lumen.

*d*₁, new-formed fibrous tissue outside the lumen.

e, new blood-vessels.

The site of the ligature is seen to be occupied by highly vascular scar-tissue, which is connected with the adventitia outside the vessel (*d*₁), but is also prolonged into the lumen of the vessel (*d*), so as effectually to occlude it. Close to the site of the ligature the various coats of the artery blend with the cicatrix. The vessels (*e*) of the fibrous plug are

chiefly derived from without, but there are also openings in connection with the lumen of the ligatured vessel itself.

As we have said, the endothelial cells take little share in the formation of the cicatrix. At the site of the thrombus itself the endothelial cells have disappeared; there can, therefore, be no question of their multiplication. They can only multiply, if at all, along the line where the thrombus bounds the free lumen of the vessel. From this line they may proceed to cover over the upper surface of the thrombus with an endothelial layer; and it is possible that they may there take some part in the development of the new fibrous tissue.

The organization of thrombi has long been a subject of minute investigation both anatomical and experimental. Of the more recent researches, the following may be named: SCHULTZ, *Deutsch. Zeitschr. f. Chir.* IX., and *Ueb. d. Vernarbung d. Arter.* In Diss. Berne 1877; RAAB, *Arch. f. klin. Chir.* XXIII. (with full references), and *Virch. Arch.* vol. 75; RIEDEL, *Deutsch. Zeitschr. f. Chir.* VI. (1875); BAUMGARTEN, *Die sogen. Organisation d. Thrombus* Leipzig 1877; DURANTE, *Wiener med. Jahrb.* III., IV.; SENFTLEBEN, *Virch. Arch.* vol. 77; TILLMANN'S, *Virch. Arch.*, vol. 78; AUERBACH, *Ueber d. Obliteration d. Arterien nach Ligatur*, In. Diss. Bonn 1877; FOÀ, *Arch. p. l. sci. med.* III.; HAMILTON, *Edin. med. Journ.*, 1880-81.

The question most hotly discussed has been whether the white blood-cells are or are not the generators of the new fibrous tissue, and to this various answers have been given. ZIEGLER, from his own investigations, is constrained to side with those who assign the chief share in the formative process to the extravasated leucocytes. The process has been too often regarded as something *sui generis*; the only characters which distinguish it from other pathological tissue formations are that the process takes place within a tube, and that dead tissue is being absorbed as new is being formed. Again the question is asked whether the new tissue is formed by inflammatory granulations or by regenerative or hyperplastic proliferation. The view taken above is that the former is the commoner and the more important mode; but the active participation of the endothelial cells is not excluded. RIEDEL'S observation is of interest in this connection; he states that the inner surfaces of an artery may be made to cohere without the formation of a clot, and that, in this case, the vessel is occluded simply by the multiplication of the apposed endothelial cells. This seems to confirm the view we have taken, that it is the presence of the thrombus, together with the mechanical injury to the vessel-wall, which sets up the plastic inflammation.

With regard to the canalization of the thrombus from the lumen of the occluded vessel (a fact insisted on by SCHULTZ), it seems probable that this is not at first a true vascularization; it is rather to be referred to the shrinking of the fibrin, which may give rise to lacunæ in the thrombus. These lacunæ become transformed into blood channels, which by and by become connected with the capillaries originating in the *vasa vasorum*.

256. The account just given applies in the first instance to the organization of thrombi in ligatured arteries. But the process in other cases is exactly similar. If a marasmic venous thrombus of some standing is examined, the inner coating of the vein is found infiltrated with cells, and the margins of the clot are transformed into granulation-like tissue, or even into vascular fibrous tissue. In the case of parietal

thrombi in the larger arteries, or in the aorta, the process of organization is very slow. Even old thrombi may show no distinct sign of organization; and in other instances small patches of immature fibrous tissue may be found on the surface. The thrombi that occupy aneurysmal sacs are very slowly and imperfectly replaced by fibrous tissue.

The process by which **wounds in blood-vessels** are healed up is analogous to organization. SCHULTZ has shown that after hæmorrhage ceases a thrombus composed of cohering white blood-cells occupies the site of the wound. This plug may bulge outwards under the pressure of the blood, but the sinus so formed is again filled up with white blood-cells. These thereupon proceed to develop, new vessels penetrate the mass from the surrounding parts, and a cicatrix is at length produced (Art. 308).

In the course of time, the fibrous tissue which replaces a thrombus shrinks more or less. The plug of scar-tissue formed after ligature may thus become extremely small, the vessel becoming pervious up to the point of ligature. The plug formed in the continuity of a thrombosed vessel may almost disappear, leaving behind only a thickening of the vessel-wall or a few bands or threads across the lumen. When this occurs, the blood may be enabled to flow through the reopened channel without sensible obstruction.

257. In Art. 254, we said that when a thrombus softens and breaks up, fragments of it may be swept off into the blood-current. We said also, that when the softening is puriform, the matters thus swept off excite inflammation and suppuration at the points where they settle. We have next to consider the fate of the less noxious fragments swept off from recent thrombi, especially the looser quickly-growing red kind, or from thrombi undergoing simple softening. Such a fragment, or **embolus**, if it is too large to pass through the capillaries, will become wedged in one or other of the smaller arteries, and generally at a point of bifurcation. Thus, an embolus starting from one of the systemic veins or from the right heart will lodge in a pulmonary arteriole. The first result of the lodgment in the vessel, or **embolism**, is that fresh deposits of fibrin take place on the plug, so that it soon occludes the vessel completely, even if too small to do so originally. The effect on the circulation of occlusion by embolism has already been described (Art. 30).

An embolus may undergo changes analogous to those which take place in the primary thrombus; it may soften, or shrink, or become calcified, or be replaced by fibrous tissue.

The process of organization is the same as that already described, but the volume of the fibrous plug is always very much smaller than that of the original embolus. After some weeks or months, the site of the embolus is often marked by nothing more than a fibrous band or a nodular protuberance on the inner coat of the vessel. In other instances, the

lumen is crossed by numerous threads running singly or connected into a loose network.

But the process is necessarily very different when the embolus sets up destructive inflammation around it. The inflammation then takes the suppurative form; the vessel-wall, the sheath, and the surrounding tissue are successively attacked, and an **embolic abscess** is formed (Art. 291).

CHAPTER III.

CHANGES IN THE QUANTITY AND COMPOSITION OF THE BLOOD.

258. We have already said (Art. 251) that the blood is a liquid tissue whose quantity and composition are normally constant, within narrow limits. This constancy of the blood is maintained by the physiological adjustment of the matter assimilated and the matters eliminated, and by the speedy rejection of any abnormal matters which may gain entrance. In disease, the equilibrium may be disturbed, so that the quantity and the chemical constitution of the blood may deviate from the normal for a longer or shorter time.

Increase in the quantity of blood in the body, *i. e.*, a true hyperplasia or **plethora**, does not occur as an abiding condition. When, for example, after amputation by the bloodless method (in which the blood contained in the limb is pressed back into the body before operation), the quantity in the body is rendered relatively excessive, the surplus is rapidly used up, and is not replaced. True plethora or polyæmia is in fact an essentially transient condition.

The opposite condition, namely, decrease in the quantity of blood, is called **oligæmia** or **anæmia**. Every abnormal loss of blood produces a temporary anæmia. If this does not exceed a certain limit, and if there is nothing to interfere with the production of blood, the loss is soon made up, and the anæmia is transient. But if the loss is greater, or often repeated, or long-continued, the anæmia may become chronic. During life, this condition is indicated by the pallor of the skin and mucous membranes; *post-mortem* it appears in the small proportion of blood contained in the several organs.

After a loss of blood, the replacement of the *liquor sanguinis* proceeds more rapidly than the replacement of the red corpuscles. For a time, therefore, the blood is relatively poor in red corpuscles, a condition described as **oligocythæmia**. This condition is frequently observed in fevers and in cases of lead or mercury poisoning; it is then an indication of impaired nutrition. In other cases, we must assume that the cause lies in the imperfect working of the blood-making organs (Art. 261); but we are frequently unable to say where the fault lies, and then we speak of the condition as **essential or idiopathic anæmia**.

If the elimination of water from the blood be interfered with, as in

renal disorders, the blood becomes watery, and the condition is described as **hydræmia** or hydræmic plethora. Here the watery parts alone are out of proportion; the amounts of the other constituents present are normal.

Hydræmia is less often the result of mere retention of water than of morbid diminution in the proportion of albumen contained in the blood, a condition which has been called **hypalbuminosis**. The diminution depends either on deficient supply or excessive consumption of albumen, or on both together. It is a common result of chronic disorders of digestion, long-continued and profuse discharges from the bowels, dysentery, chronic suppurations, excessive secretion from certain glands (over-lactation), repeated hæmorrhages, loss of albumen from renal disease, discharges from disintegrating tumors, etc. Or, as an idiopathic anæmia, we may be unable to trace its source. The proportion of hæmoglobin in the blood is diminished both in oligocythæmia and in hydræmia. Normally, the blood should contain some 14 grammes of hæmoglobin per 100 cubic centimetres; in anæmia, the proportion may fall to 8, 6, or even 3 grammes. Such blood is limpid, pale, and light-red, having much the look of meat-washings.

In oligocythæmia, the decrease of hæmoglobin is accounted for by the diminution in the number of red corpuscles. When the number is normal, either their size (Art. 251 on microcythæmia) or their hæmoglobin must be reduced. Both cases occur. In the latter case, the individual corpuscles look strikingly pale under the microscope, as is observed in the blood of chlorosis.

Anhydræmia is the opposite of hydræmia; it implies that, while the proportion of albumen in the blood is maintained, the proportion of water and salts is diminished. Blood of this kind appears viscid and tar-like in consistence and color. In man, it is oftenest the result of profuse watery discharges from the bowels, as in cholera, or of excessive loss of water by the skin.

In many diseases, the proportion of the fibrin-factors in the blood is altered. It is increased (**hyperinosis**) in all inflammatory disorders, but especially in croupous pneumonia, rheumatism, and erysipelas. It is commonly somewhat increased in hydræmia. The result is that when the blood coagulates the amount of fibrin formed is abnormally great.

The proportion of hæmoglobin in the blood is subject to considerable variation according to age (LEICHTENSTERN, *Untersuchungen üb. d. Hämoglobingehalt d. Blutes* Leipzig 1878; HOPPE-SEYLER, *Physiol. Chemie* Berlin 1877-81; LAACHE, *Die Anämie* Christiania 1883). It is highest at birth; in the first year it falls to one-half, and rises again between the fifth year and the forty-fifth to about two-thirds of its original amount; thence it again declines. Men have a somewhat higher proportion of hæmoglobin than women. The proportion diminishes during gestation. For methods of estimation, see GAMGEE (*Physiol. Chem.* I.); CORNIL and RANVIER (*Man. Path. Hist.* I.); HART (*Quart. J. micro. sci.* 1881); LYON and THOMA (*Virch. Arch.* vols. 84, 87).

MAAS has shown (*Deutsch. Zeitschr. f. Chir.* XVII.) that in animals rapid with-

drawal of water from the blood is followed by rapid diminution of blood-pressure and of temperature. He maintains that most cases of **sunstroke** or heat-stroke must be reckoned as cases of anhydræmia.

259. The changes in the blood discussed in the foregoing paragraphs have been merely quantitative. But there are also numerous **qualitative changes**, depending on the presence in the blood of foreign substances in solution. The chemical processes normally taking place in the blood are few and simple; the abnormal substances are thus either derived from the exterior, or are products of tissue-change abnormal in themselves or abnormally taken up into the blood; it is rare for abnormal substances to be generated in the blood itself. Most of these impurities of the blood are not traceable by means of the microscope; there are no histological tests for the presence in the blood of sugar, of urea, or of morphia. But few exceptions exist. Of the gases entering the blood by the lungs **carbonic oxide** produces the most striking change. It gives the blood a bright cherry-red color, which can often be recognized in the bright tint of the post-mortem *livores* or stains. On section the blood which flows from the vessels, and that contained in the parenchyma of the organs, alike exhibit the characteristic color. In cases of poisoning by **carbonic acid** the blood is dark, and the post-mortem stains violet or livid. The blood is likewise darkened, and may be even inky, after poisoning by **sulphuretted hydrogen**.

Of products of metabolism abnormally taken up into the blood, the salts of the biliary acids and the bile-pigments are most readily recognized. The **bile-pigments** color the plasma yellow. Probably the same effect may be produced by the biliary salts, for they bring about solution of the hæmoglobin and its transformation into bilirubin. The passage of bile into the blood is at once manifested by the yellow staining of the tissues, especially such as have no marked color of their own. This condition is known as **icterus**, or **jaundice**. If the staining is recent, the tint is yellow; after a time it passes into brown or grayish-green. The urine is likewise discolored, and the presence in it of the bile-pigments can readily be demonstrated by proper tests.

The plasma of the blood may be discolored by the presence of **methæmoglobin**, set free by the solution in it of the red corpuscles; the substance may be demonstrated in the blood, and also in the urine. If the quantity present is considerable the blood has a lake-red tint, while the urine may be stained from light brownish-red to a deep dark-red (Art. 262).

In what is called **uræmia**, a condition arising from impairment of the renal function, various matters accumulate in the blood which affect injuriously the several organs and especially the brain. The latter effect is indicated by the coma and convulsions which accompany the disorder. (CHRISTISON, *On granular degeneration of the kidneys* Edinburgh 1839; SCHERER, *Verh. d. phys.-med. Gesell. zu Würzburg* II., VII.). In animals whose kidneys have been excised, urea

and various urinary extractives are found to gather in the blood. In **gout** the normal proportion of uric acid is remarkably increased (GARROD, *Med. chir. Trans.* 1848, and *Gout and Rheumatic gout* London 1876).

In acute yellow atrophy of the liver **leucin** and **tyrosin** have been detected in the blood. In some stages of diabetes the blood-serum becomes milky (**lipæmia**) from the presence of chyle or emulsified fat (HOPPE-SEYLER, *Physiol. Chemie*; GAMGEE, *Physiol. Chemistry* I.; SANDERS and HAMILTON, *Edin. med. Journ.* 1879).

CHAPTER IV.

CHANGES IN THE BLOOD-CORPUSCLES.

260. The formed elements of the blood, the red and white corpuscles, are not permanent structures; the red corpuscles are continually perishing while new ones take their place; and the white corpuscles are diminished in number by migration from the vessels, so that the proportion of them in circulation must be maintained by the development of new cells.

The number of white cells in the blood is not altogether constant even in health. It is now reckoned that on the average there is one white cell to six hundred red; but the proportion is often greater (as during digestion), and often less.

In many and various morbid conditions (as in continued suppuration, in typhus, typhoid, and intermittent fevers, in pyæmia, erysipelas, etc.) the white blood-cells are increased in number, multinuclear forms appearing as well as the uninuclear; the proportion may in such cases rise to 1 in 100, 1 in 50, or even 1 in 20. According to VIRCHOW the white corpuscles are most apt to be morbidly increased when the lymphatic glands are affected. The condition of morbid increase he calls **leucocytosis**; it is a temporary condition and dependent on transient causes.

Leukæmia (VIRCHOW) or **leucocythæmia** (HUGHES BENNETT) is to be distinguished from the merely temporary condition of leucocytosis. Its characters are—a more or less notable and abiding increase of white corpuscles, accompanied by a decrease of the red corpuscles. The proportion between the two may be so altered that their numbers become equal, or in extreme cases the white may slightly outnumber the red.

In well-marked leukæmia the blood is quite visibly altered in appearance; it looks pale, transparent, and limpid. *Post-mortem* the accumulations of white corpuscles may here and there be so great that they are apparent to the unaided eye. In the heart and great vessels peculiar muddy clots are found instead of the usual fibrinous deposits, or the ordinary *post-mortem* clots may be covered over with a white creamy pus-like film. The diagnosis of less-marked cases may require the aid of the microscope, by which even a slight relative increase of the white cells in the blood may be recognized.

Post-mortem examination of cases of leukæmia shows that changes in certain of the organs are associated with the changes in the blood; these

are no doubt partly cause and partly effect of the blood-changes. The hyperplasia of the spleen (Art. 328), of the lymphatic glands (Art. 344), and of the marrow of the bones, is considered as an originating factor of the blood-changes. The grayish infiltration which appears diffused or in patches through various organs like the liver, lungs, and kidneys, can scarcely be other than an effect; the white cells circulating in the blood have lodged and accumulated in the parts affected. These infiltrated cells lie partly within the vessels, and partly around them. Occasionally the appearances are such that we can only explain them by assuming that a '**white hæmorrhage**' or hæmorrhagic infarction has occurred. Besides these patches of simple infiltration tumor-like formations of lymphadenoid tissue are at times found in certain parts, such as the liver and kidneys.

BENNETT was the first to describe the affection, which he called leucocythæmia and regarded as a 'suppuration of the blood' (*Edin. med. and surg. Journ.* Oct. 1845; *Leucocythæmia* Edinburgh 1852; see also *Brit. for. med. chir. Review* 2, 1852). VIRCHOW recognized its true character and significance under the name of 'white blood' or leukæmia (*Froriep's Notizen* Nov. 1845; *Gesamm. Abhand.* p. 147).

The white corpuscles found in leukæmic blood are not all alike. A larger and a smaller variety can be distinguished, and in different cases one or another form may be the more abundant. VIRCHOW holds that the larger cells are derived from the spleen, and their abundance in the blood is due to a splenic hyperplasia; the smaller cells he traces to the lymphatic glands. From this point of view leukæmia has been characterized as splenic (lienal), lymphatic, or lymphatico-splenic, the latter form being intermediate between the other two. The relation of the spleen or lymphatic glands to the disease is thus assumed to be—that by the hyperplasia of these organs an increased supply of lymphoid elements is produced and conveyed into the blood. Attention has been called to the part played by the bone-marrow by the researches of BIZZOZERO (*Cent. f. d. med. Wiss.* 1869), NEUMANN (*Arch. d. Heilk.* XI., and *Berl. klin. Woch.* 6, 1879, with full references to other papers), PONFICK (*Virch. Arch.* vol. 67), WALDEYER (*Virch. Arch.* vol. 52), and others. In leukæmic patients the marrow often manifests very notable changes; it becomes yellowish and pus-like, and contains an excessive proportion of lymphoid cells. Going upon the assumption that lymphoid elements pass into the blood from the bone marrow as well as from the spleen and lymphatic glands, a fourth form of leukæmia has been described—the medullary or myelogenic form. This can seldom occur uncombined with other forms.

Nucleated red blood-cells have now and then been found in leukæmic blood (ERB, *Virch. Arch.* vol. 34; BOETTCHER, *ib.* vol. 36; KLEBS, *ib.* vol. 38; HAYEM, *Arch. de physiol.* 1883). NEUMANN (*Berl. klin. Woch.* 10, 1878) believes that this fact is sufficient to establish the participation of the marrow in the genesis of the affection; but BIZZOZERO and SALVIOLI (*Centralb. f. d. med. Wiss.* 1879) dispute this, and think the nucleated corpuscles are derived from the spleen.

It is impossible to assign definitely the parts taken by the different organs in the production of leukæmia. We do not even know for certain whether all the organs referred to are normally capable of contributing lymphoid elements to the blood. It still seems questionable whether the marrow takes the important share ascribed to it at all; it may well be that the accumulation of lymphoid elements observed in it is merely a secondary result of the general disease.

The ultimate cause of leukæmia is still unknown. It is not inconceivable that it may be due to a primary disorder of the substance of the blood itself (KOTTMANN, *Symptome der Leukämie* Berne 1877). LEUBE, PENZOLDT, and FLEISCHER have recently described cases (*Virch. Arch.* vol. 83, *Arch. f. klin. Med.* XXVI.) in which neither spleen nor lymphatic glands nor bone-marrow were affected; from this it would seem that structural changes in these tissues are not absolutely essential to leukæmia. Possibly, as KLEBS has suggested, it may in reality be an infective disorder.

It is a noteworthy fact that hyperplastic changes may take place in the spleen and lymphatic glands without any accompanying leukæmia. Such an affection is spoken of variously as malignant lymphoma, pseudoleukæmia, and lymphatic or splenic anæmia (Arts. 328, 344). The latter description refers to the fact that the affected patients gradually sink and die in extreme anæmia. Occasionally the pseudoleukæmia seems to pass into true leukæmia. Further details on the subject, together with full references to the literature bearing on it, are given by MOSLER in *Ziemssen's Cyclopædia*, Art. *Leukæmia*, vol. VIII.; also by FLEISCHER and PENZOLDT in *Arch. f. klin. Med.* XXVI., and by GOWERS, *Reynolds' Syst. of Med.* v. A peculiar feature of some cases of leukæmia is the presence in the blood of long needle-like octahedral crystals ('Charcot's crystals': CHARCOT and ROBIN, *Soc. de biol.* 1853, NEUMANN, *Arch. f. mikr. Anat.* II.; ZENKER, *Arch. f. klin. Med.* XVIII.; according to SCHREINER (*Liebig's Annal. d. Chem.* 1878) they consist of an organic phosphate).

EHRlich has recently given much attention to the white blood-cells, and especially to their behavior with various staining-reagents (*Verh. d. physiol. Gesell. zu Berlin* 20, 1878-9 and *Zeitschr. f. klin. Med.* I.). He finds that a whole series of forms or stages can be distinguished. One form contains a single ovoid nucleus that stains feebly, another contains one or more rounded deeply-staining nuclei. Some cells show peculiar arrangements of their granules, whose power of taking up color varies in different cases. Others are notable for their power of absorbing eosin ('eosinophilous cells'). EHRlich further notes that in all acute cases of leucocytosis the uninuclear and multinuclear cells are increased in number, but the eosinophilous cells are not. On the other hand when the hæmatopoietic organs are chronically diseased, as in leukæmia, the eosinophilous cells are increased in number. Compare SPILLING, *Blutuntersuch. bei Leukämie* In. Diss. Berlin 1880.

261. In speaking of the cases in which the whole amount of blood in the body is reduced, in other words of oligæmia, we mentioned that the number of the red corpuscles is simultaneously diminished. This condition, known as **oligocythæmia**, is recognized by the diminished proportion of hæmoglobin in the blood, and by the actual diminution in the number of red corpuscles contained in a drop of it. In extreme anæmia the number may fall to one-eighth or one-tenth of the normal. The diminution in the number of the corpuscles is often associated with changes in their form. Some of them are unusually minute and darker or lighter in color; they may measure 4-6 micromm. instead of 6-8 micromm. in diameter. This condition is referred to as **microcythæmia**. In some forms of anæmia, as in chlorosis and lead-poisoning, both abnormally small and abnormally large red corpuscles (microcytes and macrocytes) are found. Occasionally cells that are singularly altered in shape and

partly broken up are met with, a condition known as **poikilocytosis**. As regards the diagnosis of such cases, it must not be forgotten that very soon after the blood has left the vessels the cells undergo very various changes, by contact with the air, evaporation, etc. Even when the blood is taken with the greatest care we can hardly make the examination without causing some of the cells to be deformed. It is common enough to see them actually assuming angular, tuberculated, or stellate forms. Microcythæmia and true poikilocytosis are probably due both to defective production and to excessive and abnormal destruction of the corpuscles; of these the latter is perhaps the chief factor.

The causes of the blood-changes here described are in part those already given (Art. 258) as producing anæmia and hydræmia. The changes are however also exhibited in the diseases known as chlorosis, pseudoleukæmia, simple and hæmorrhagic purpura, and scurvy. They are most pronounced in the grave disorder known as **progressive pernicious anæmia**. In the latter the dependence of the blood-change on some organic affection can often be clearly demonstrated, but there are many cases in which the cause of the rapid destruction of the corpuscles cannot be discovered (idiopathic anæmia). Nucleated red corpuscles have often been found in the graver forms (COHNHEIM, *Virch. Arch.* vol. 68; LITTEN, *Berl. klin. Woch.* 1877, 1880; EHRLICH, *ibid.* 1880; HAYEM, *Arch. de physiol.* 1883.

The changes which occur in the red corpuscles and in the hæmoglobin of the blood in anæmia have been much investigated within the last ten years. Special attention has been given to the examination of the blood in pernicious anæmia; by which term the highest grade or extreme of anæmia is implied (QUINCKE). Comparative examinations have likewise been made of the less extreme varieties such as occur in chlorosis, after severe hæmorrhage, in simple purpura, in scurvy, in the puerperal state, in chronic tuberculosis, in gastric carcinoma, in nephritis, etc.

Of the numerous papers on the subject the following may be mentioned:—ADDISON, *Collected Works* (New Syd. Soc.) London 1868; BIERMER, *Corresp. f. schweiz. Aerzte* II. (1872); ZENKER, *Deutsch. Arch. f. klin. Med.* XIII.; IMMERMANN, *ib.* XIII., and *Ziemssen's Cyclopædia*, vol. XIII.; VANLAIR and MASIUS, *De la microcythémie* Brussels 1871; TROUSSEAU, *Clin. Medicine* v.; PONFICK, *Berl. klin. Woch.* 1873; QUINCKE, *Virch. Arch.* vol. 54, *Sammlung klin. Vorträge* 100, and *Arch. f. klin. Med.* XX., XXV., XXVII.; PYE-SMITH, *Virch. Arch.* vol. 65; QUINQUAUD, *Arch. gén. de méd.* Sept. 1879; MÜLLER, *Die progr. perniciose Anämie* In. Diss. Zurich 1877; LÉPINE, *Bulletin gén. de Thérap.* 1876, *Revue Mensuelle* 1877 (with analysis of published cases); BYROM BRAMWELL, *Edin. med. Journ.* 1877; EICHHORST, *Die prog. pern. Anämie* Leipzig 1878; PENZOLDT, *Situngsber. d. phys.-med. Soc. zu Erlangen* 1878; BIZZOZERO, *Centralb. f. d. med. Wiss.* 8, 1881; FRANKENHÄUSER, *ibid.* 1883; WALDSTEIN, *Virch. Arch.* vol. 91; LAACHE, *Die Anämie* Christiana 1883. For English work on the subject see WILKS, *Brit. med. Journ.* 2, 1874; TAYLOR, *Guy's Hosp. Rep.* 1878; COUPLAND, *Gulstonian Lectures*, *Lancet* 1, 1881; HOBSON, *Practitioner* XXX. (1883).

The genesis of oligocythæmia is referable partly to excessive consumption, partly to defective production, of the red corpuscles. As regards the latter many

authors maintain that white corpuscles are transformed into red by the development in them of hæmoglobin. Some hold that the transformation occurs within the blood as it circulates, others that it is confined to the spleen and bone-marrow. The transformation (say they) is effected by the disappearance of the nucleus, the rounding and flattening of the cell, and the gradual deposition in it of hæmoglobin. In support of this view the occurrence of nucleated red corpuscles is insisted on.

Quite recently these assumptions have been assailed by various investigators, and a different account has been given of the genesis of red corpuscles. HAYEM makes out that they arise from his 'hæmatoblasts,' which are pinkish, yellowish, greenish, or sometimes colorless biconcave discs, without nuclei, and measuring 1-4 micromm. across. These discs are formed in the protoplasm of the lymph-corpuscles, and are shed by the latter before they reach the blood. CADET and POUCHET give a like account, though the latter believes that nucleated red corpuscles are produced by direct transformation from leucocytes. MALASSEZ and FOÀ say that they are formed out of cells budded off from the nucleated cells of the bone-marrow. RINDFLEISCH finds that nucleated red hæmatoblasts are formed in the marrow, which subdivide and produce daughter-cells; from these the nucleus is extruded and the remainder becomes a red corpuscle. BIZZOZERO denies the accuracy of HAYEM'S observations and holds that the latter's 'hæmatoblasts' are nothing but his own blood-plates (Art. 252), which have nothing to do with the production of red corpuscles. He asserts that after birth nucleated red blood-cells appear in the bone-marrow, which are really young corpuscles, and increase by subdivision. The division of the nucleus is accompanied by the formation of karyolytic figures. In early foetal life this process of multiplication takes place throughout the entire vascular system; towards the close of foetal life the process is restricted to the liver and spleen, and after birth to the bone-marrow. NEUMANN takes up a like position. Like RINDFLEISCH, BIZZOZERO states that the nucleus escapes from these young corpuscles, while FOÀ assumes that it disappears.

References:—BIZZOZERO, *Gaz. med. Lombard.* 2, 1869 and 1874, *Centralb. f. d. med. Wiss.* 1869, *Arch. p. l. scienze med.* IV., *Centralb. f. d. med. Wiss.* 40, 1880 and 8, 1881, *Arch. ital. de biol.* I.; NEUMANN, *Centralb. f. d. med. Wiss.* 44, 1868 and 19, 1869, *Arch. d. Heilk.* X. and XV., *Arch. f. mikrosk. Anat.* XI.; SCHÄFER, *Proc. Roy. Soc.* XXII. (1874); R. MAIER, *Allg. path. Anat.*; RANVIER, *Arch. d. phys.* 1874; SCHMIDT, *Month. Micro. Journ.* 1874, *Quart. J. micro. sci.* 1880; HAYEM, *Gaz. méd. de Paris* 1876 and 1878, *Comptes Rendus* LXXXIV., LXXXV., and LXXXVI., *Arch. de physiol.* 1878 and 1879; MALASSEZ, *Gaz. méd. de Paris* 1874 and 1878; POUCHET, *Journ. de l'anat. et de la phys.* XV., *Gaz. méd. de Paris* 25, 1878, *Arch. de Phys. norm. et path.* 1882; RINDFLEISCH, *Arch. f. mikrosk. Anat.* XVII.; DEMME, *Ueb. d. morph. Bestandtheile d. Blutes bei Säuglingen*, *Jahresb. d. Kinderspitäler* Berne 1880; COHNHEIM, *Virch. Arch.* vol. 58; LITTEN, *Berl. klin. Woch.* 1879, 1883; ZAESLEIN, *Blutkörperchenzählung bei Typhus abdominalis* In. Diss. Basle 1881; TIZZONI, *Arch. ital. de biol.* I.; ZAHN, *Rev. méd. de Genève* 1881; THOMA, *Virch. Arch.* vol. 87; CADET, *Étude phys. des éléments figurés du sang* Thèse de Paris 1881; FOÀ, *Arch. p. l. sci. med.* 1879, *Arch. ital. de biol.* I.; FEURSTACK, *Zeitschr. f. wiss. Zool.* XXXVIII.

262. The normal process of **destruction of the red corpuscles** may be greatly accelerated and increased by various morbid influences. High temperature affecting the blood directly, as in the case of burns, always brings about a considerable amount of disintegration among the

corpuscles. Many of them crumble into fragments and dissolve (PONFICK, KLEBS); others, without being actually seen to break up, are rendered functionally useless and presently disappear. The products of disintegration circulate for a time in the blood, and are then at length eliminated.

Certain chemically-active substances act on the red corpuscles in the same way as high temperature; such are nitrobenzol (FILEHNE), potassium chlorate (MARCHAND), pyrogallic acid (NEISSER), sulphuric acid (LEYDEN and MUNK), nitrite of amyl (HOPPE-SEYLER), certain mushrooms of the morel kind (PONFICK), and the venom of certain serpents (HALFORD).

PONFICK has shown that when blood from one animal is transferred into the vessels of another the foreign red corpuscles become dissolved. In patients suffering from **intermittent hæmoglobinuria** LICHTHEIM showed that cooling of the cutaneous surfaces caused a great number of the red corpuscles to break up and dissolve in the plasma (Art. 259). Lastly in so-called **melanæmia**, a result of malarial infection, the blood-change is due to the destruction of the corpuscles and the retention of the disintegrated products in the blood. The effect is that the plasma contains granular pigment either free or enclosed in cells or agglomerated into irregular masses.

On the destruction of red corpuscles after burns see PONFICK (*Naturforscherversam.* Munich, 1877, *Berl. Klin. Woch.* 46, 1877), LESSER (*Virch. Arch.* vol. 79, with references), CATIANO (*Virch. Arch.* vol. 87), HOPPE-SEYLER (*Zeitschr. f. phys. Chem.* 1881), TAPPEINER (*Cent. f. d. med. Wiss.* 21 and 22, 1881). On paroxysmal or intermittent hæmoglobinuria see LICHTHEIM (*Samm. klin. Vorträge* 134, with full references), BOLLINGER (*Deutsch. Zeitschr. f. Thiermed.* III.), BOAS (*Arch. f. klin. Med.* XXXII.), ROSENBACH (*Berl. klin. Woch.* 10, 1880), EHRLICH, (*Deutsche med. Woch.* 16, 1881). On melanæmia see MOSLER (*Ziemssen's Cyclop.* VIII.), COLIN (*Traité des fièvres intermitt.* Paris 1870), Arnstein (*Virch. Arch.* vol. 61), KELSCH (*Arch. de physiol.* 1875). On the effect of transfusion see PONFICK (*Virch. Arch.* vol. 62). On poisoning with potassium chlorate see MARCHAND (*Virch. Arch.* vol. 77), and with mushrooms PONFICK (*Virch. Arch.* vol. 88) and BOSTRÖM (*Phys.-med. Gesell. zu Erlangen* 1880).

BIRCH-HIRSCHFELD (*Berl. klin. Woch.* 36, 1879) describes, under the name of epidemic hæmoglobinuria of infants, a disease observed by WINKEL in the Dresden Lying-in hospital; it attacked suckling children, who rapidly perished with symptoms of destructive change in the blood, cyanosis, jaundice, hæmoglobinuria, and petechial eruptions. Its cause is unknown.

CHAPTER V.

SOLID IMPURITIES IN THE BLOOD.

263. The morbid changes in the blood just discussed (Arts. 257-262) are all liable to produce more or less transitory pollution of the blood. Disintegrated corpuscles, such as are common after burns, can only be regarded as impurities which have to be eliminated; and so too the pigment-granules of melanæmia, and the crumbled fragments of softening thrombi, are matters foreign to healthy blood. They have this in common that they are the products of **morbid changes in the blood** itself. The minute groups of granules seen in some cases of anæmia are probably of the same nature; RIESS (*Reichert's Arch.* 1872) thinks they are disintegrated white cells, LEUBE (*Berl. klin. Woch.* 44, 1879) regards them as broken-down hæmatoblasts, BIZZOZERO (*Arch. ital. de Biologie* I.) as broken-down blood-plates.

Morbid changes in the vessel-wall may introduce impurities as well as changes in the blood itself. For instance, in some infective fevers the vascular endothelium becomes fatty and is shed into the blood-current. When the lining membrane of the heart or great vessels becomes inflamed it is not uncommon for fragments of diseased tissue to be swept off in like manner. Fatty or necrotic patches in the lining membrane are also very apt to contribute impurities to the blood; it is thus that fragments of necrosed valves, of inflammatory exudations, and of fatty detritus enter the circulation.

264. **Impurities derived from the tissues** are frequently conveyed by various channels into the blood. The lymphatic system is one channel, and solid matters may be taken up and carried along by the lymph-current directly. More commonly such matters are first taken up by contractile cells which act as carriers. Thus the products of disintegration of extravasated blood are carried off by corpuscle-carrying cells, and the products of fatty degeneration by fat-granule cells. In like manner other minute particles or even living tumor-cells may reach the blood.

But the lymphatics are not the only channel; it is not rare for the blood-vessels to be entered directly. A tubercle developed in the vessel-wall may break up, and be in part swept off by the current. Tumors, such as cancers, may likewise break into the vessels, and tumor-cells may be conveyed from them to remote points. Moreover, when vessels are

wounded extraneous organic matters such as fat may gain direct access to the blood, indeed after wounds involving adipose tissues the blood is almost always found to contain oil-globules.

265. **Extraneous corpuscular matters** may reach the blood in the same way as those derived from the tissues of the body itself. Inhaled coal-dust or steel-dust may pass through the pulmonary lymphatics and reach not only the glands but from them the blood itself, and similar minute solid matters may gain access directly from wounds. Here as before the migratory cells play an important part by taking up the foreign matters into their substance and carrying them to a distance. Of such foreign matters **animal and vegetable parasites** are unquestionably the most important. We have already discussed in the First Part the conditions under which such parasites gain an entrance. Their invasion of the blood is partly passive, and partly active. So far as it is passive the process is that just described; but many parasites have moreover the power of active penetration of the tissues, and so make direct avenues of entrance for themselves through the vessel-walls while they also use the pre-existing lymph-channels. It must also be remembered that many parasites, and chiefly the vegetable kinds, have the power of multiplication within the blood; so that every drop may contain a multitude of individual organisms. The best examples of this are afforded by the anthrax-bacillus and the spirillum of relapsing fever. In the case of the other bacterial affections this process of multiplication within the blood has not yet been demonstrated, though there are many disorders in which brood-colonies are met with in the smaller blood-vessels, as in pyæmia (Art. 199). Among animal parasites the *Filaria sanguinis* (Art. 235) is the only one which occurs in great numbers in human blood. Trichinæ, when they do enter the blood, stay only a short time in it. As to the seat of the *Distoma hæmatobium* or *Bilharzia* see Art. 239; and for *Echinococcus* see Art. 248.

The **entrance of air** into the blood-vessels deserves special mention. It most frequently results from wounds of the great veins in the neighborhood of the thorax; but it may also occur in consequence of ulceration into the veins, as in cases of gastric ulcer (JÜRGENSEN), or after parturition through the open uterine sinuses. If not rapidly absorbed the bubbles of air behave like small solid bodies and produce like results.

266. It may be taken as a general law that no foreign body can for any long time remain in the blood; it is either deposited, or destroyed, or eliminated from the circulation. It may be deposited in very various localities; a large body will naturally lodge in the heart or a great vessel, a smaller one may pass into a capillary.

If a large quantity of **air** enters the right heart from a venous trunk, it forms with the blood a bulky froth, which the contractions of the heart are unable to propel effectively. The result is that little or no blood reaches the left heart, the blood pressure in the aorta sinks, and

the patient quickly dies. If, however, the quantity of air which enters the blood is small, or its entrance slow, it is carried on in the form of minute bubbles, and may circulate throughout the body. Larger quantities may produce local disturbances of the circulation, and so interfere with the cerebral or respiratory functions, but after a time it is all absorbed.

Small bodies such as **fat globules** or **pigment granules** generally lodge in the capillaries of the various parts. Certain organs seem to be favorite seats for such lodgments; such are in especial the spleen and liver, and frequently also the kidneys and bone-marrow. The observation may often be verified on the post-mortem table, but it may also be experimentally demonstrated (PONFICK). The cause of the preference for these organs probably lies in their anatomical structure, in consequence of which the blood-current through them is unusually slow. As regards the spleen, an additional factor comes into play in the permeability of its vessel-walls; this specially favors the extravasation of small bodies from the blood-current, and in particular such as are inclosed in contractile carrier-cells.

The process of deposition is most easily followed in the case of pigmentary matters, such as disintegrated blood, or iron-compounds, or granular coloring matters inhaled or injected into the blood. The spleen pulp may in such cases become deeply stained, and sections of the liver may also show the effect in a very instructive manner. In the latter instance the deposit lies chiefly around the periphery of the lobules. At first the foreign matters are seen to lie within the vessels, but afterwards they partly pass out of them into the tissues. This escape is generally effected by the help of contractile carrier-cells (Arts. 112-114), but free corpuscular matters may escape from the capillaries directly, especially from those of the spleen.

The behavior of **bacteria** in the vascular system has already been discussed (Arts. 199-200). The embolic occlusion of arteries by larger foreign bodies, and its results, are described in Arts. 29, 33, and 255-257.

The fate of foreign bodies which have gained access to the blood has been the subject of several experimental researches by PONFICK (*Virch. Arch.* vol. 48), SLAVJANSKY (*ibid.*), RUPPERT (*Virch. Arch.* vol. 72), SOYKA (*Prag. med. Woch.* 1878), and others. Cinnabar, or coal-dust, or Chinese black was introduced into the blood of animals, either directly, or through the pulmonary lymphatics by inhalation. These substances were found to become inclosed in contractile cells, and to be deposited outside the vessels in the spleen, liver, kidneys, and bone-marrow. The carrier-cells generally take up the foreign matters before they leave the blood; but in the spleen pulp and in the marrow they may become enclosed after escaping.

On the subject of **fat-embolism** see SCRIBA (*Deutsch. Zeitschr. f. Chir.* XII., with full references), FLOURNOY (*Contrib. à l'étude de l'embolie graisseuse* Strasbourg 1878), HAMILTON (*Edinburgh Med. Journ.* 1879), JOLLY (*Arch. f. Psych.* XI.), JACOBSON (*Holmes' Syst. of Surg.* I.), MANSELL-MOULLIN (*Inter. Encyc. of Surg.* I.).

On the consequences of the entrance of air into the blood-vessels, JÜRGENSEN has recently published (*Arch. f. klin. Med.* XXXI.) the results of his clinical and experimental investigations; they partly bear out and partly extend the results previously obtained by BICHAT, MAGENDIE, MURON, LABORDE, COUTY, and others. He states that air injected distally into the right femoral artery appears after thirteen minutes in the left femoral vein, having passed through three capillary systems. The air may continue to circulate for hours, but is ultimately absorbed. When air enters the pulmonary vessels, dyspnœa with brief respiratory pauses is induced. When life is in danger, the respiration is notably slowed. So long as air is in circulation the proportion of oxygen in the blood is diminished.

267. The **ultimate fate of foreign substances** which have been arrested in the blood-vessels or have passed into the neighboring tissues, varies according as the substances are destructible or not.

Insoluble matters, like cinnabar, coal-dust, etc., remain in the tissues permanently, or are in part eliminated from the body. Experiment shows that after many weeks some part of the substance may still lie enclosed in cells within the tissues. During this time some movement of the substance always takes place; the carrier-cells change their position, and may even enter the blood once more. In this way part of the substance is carried to the exterior of the body, and that by various routes. In the first place, glands like the kidneys, liver, or mamma, whose secretion passes out of the body, may eliminate the foreign substance with the secretion. But it may also pass out through the mucous membranes, through the lungs, through wounded parts, or even through the skin; such is especially the case when active cell-migration is taking place at any of these sites. For example, if we introduce a considerable amount of insoluble coloring matter into the blood or lymph of an animal, and then induce inflammation at any point, a large proportion of the migratory leucocytes will be found to have portions of the coloring matter inclosed in their protoplasm. In spite, however, of these processes, by which the organism gets rid of its impurities, some part of the foreign substance will usually remain in the tissues; and if the substance is colored, a morbid or abnormal pigmentation of the organs may result.

Many of the extraneous substances entering the blood are soluble and destructible, and such always disappear after a longer or shorter time. Thus inhaled particles of chalk-dust are dissolved in the blood; fat, which circulates in great drops, rapidly disappears; and micro-organisms likewise break up and are absorbed, so soon as they cease to find the vital conditions that are necessary to them. Even embolic plugs of considerable size (such as fragments of thrombi, of diseased valves, etc.), are in time dissolved and disappear (see Arts. 114–115 and 254–257, where the effects of septic or infective embolism are described).

Emboli consisting of living cells may proceed to grow and develop at the spot where they lodge. This happens, for example, in the development of secondary tumors (Art. 174).

268. The question as to **what becomes of disintegrated red cor-**

puscles has a special interest. We have already said in Art. 260 that the lifetime of a red corpuscle is but brief; according to QUINCKE (*Deutsch. Arch. f. klin. Med.* XXVII.) it is probably not longer than two or three weeks. At the end of that time it becomes functionally inactive, is taken up by the white cells, and eliminated from the blood. QUINCKE says this happens chiefly in the liver and spleen, possibly also in the bone-marrow. The red corpuscles and their *débris* inclosed in the white cells of the spleen-pulp are transformed into colored or colorless ferro-albuminoid compounds, which may be micro-chemically demonstrated either in the soluble or the granular form. From the spleen and marrow, perhaps also from the liver, some part of these iron-compounds passes again into the blood, being utilized in the formation of new red corpuscles; the remainder is excreted by the liver-cells.

If however the destruction of blood-cells becomes so excessive that hæmoglobin appears in solution in the plasma, the kidneys take part in the eliminating process, and **hæmoglobinuria** is induced. Hæmatogenous and biliary pigments which have passed into the blood (as from old hæmorrhagic patches, for example) are excreted in the urine as urobilin (KUNKEL, *Virch. Arch.* vol. 79). The more insoluble parts of the red corpuscles reach the spleen, liver, and bone-marrow; and there the normal process of disintegration becomes intensified so as to meet the demand on it thus occasioned. In these organs numbers of cells can be seen which contain fragments of red corpuscles, or brown and yellow flakes and granules of pigment; and similar flakes and granules also occur free. The pigmentation of the organs may in this way become very intense. The kidneys also generally contain fragments of pigment in the glomeruli, tubules, and interstitial tissue. PONFICK has pointed out (*Berl. klin. Woch.* 1877) that such deposits are often associated with serious textural and functional changes in the kidneys, and especially with the formation of tube-casts and fatty degeneration of the renal epithelium.

The brown flakes and granules found in these deposits have not always the same composition. They are in part proximate derivatives of the blood-pigments such as bilirubin and hæmatoidin, formed directly from hæmoglobin; partly ferro-albuminoid bodies (QUINCKE); and partly other compounds of iron such as the hydrated sesquioxide (KUNKEL, *Virch. Arch.* vol. 81).

The liver and spleen may be unable to deal with the increased amount of material brought to them when the disintegration of corpuscles in the blood exceeds a certain limit; that is to say, they may not be able to destroy it or to eliminate it with the bile. Hence these organs may show signs of more or less temporary pigmentation or of deposits of iron-compounds (QUINCKE, KUNKEL); and the same is occasionally seen in other organs. Part of the iron deposited may possibly be derived directly from dissolved hæmoglobin which has not undergone change in the interior of carrier-cells.

QUINCKE moreover affirms that such deposits of iron may occur when from any cause the formation of new corpuscles is interfered with. The iron-compounds naturally formed are not utilized speedily enough in forming blood, and are not at once eliminated from the body.

The above account of the formation of pigment-granules containing iron rests mainly on the researches of QUINCKE and KUNKEL. It is to a certain extent confirmed by the case described by HINDENLANG (*Virch. Arch.* vol. 79), in which pigmentary infiltration of many of the organs was observed in a patient dead of purpura, in whom a large extravasation of blood had undergone absorption. The liver, spleen, pancreas, kidneys, and other organs contained yellowish-brown pigment-carrying cells, and yellow and brown flakes and granules of free pigment. KUNKEL examined the pigment and found it to consist of hydrated ferric oxide with a mere trace of hæmatin; while, as ZIEGLER convinced himself, the appearances were exactly those of the pigmentary infiltrations found in other like cases. It may therefore be granted that in such cases pigments may be formed containing iron, which are not at all or only remotely related to hæmatin (Art. 68). QUINCKE, who demonstrated by chemical tests the presence of iron in pigmented sections, found it occurring diffused or as minute granules in the lymphatic glands, liver, and kidneys. He calls the condition **siderosis**, a term that is in itself not inapt, though it has already been applied to the deposit of inhaled steel-dust in the lungs.

CHAPTER VI.

CHANGES IN THE LYMPH.

269. The **lymph** is merely the liquid transuded from the blood-vessels, together with certain products of tissue-metabolism and certain matters taken up (*e. g.* by the lacteals) from the outside. To this the lymphatic glands contribute a number of lymphoid elements, in addition to the few cells derived from the blood. The sources of

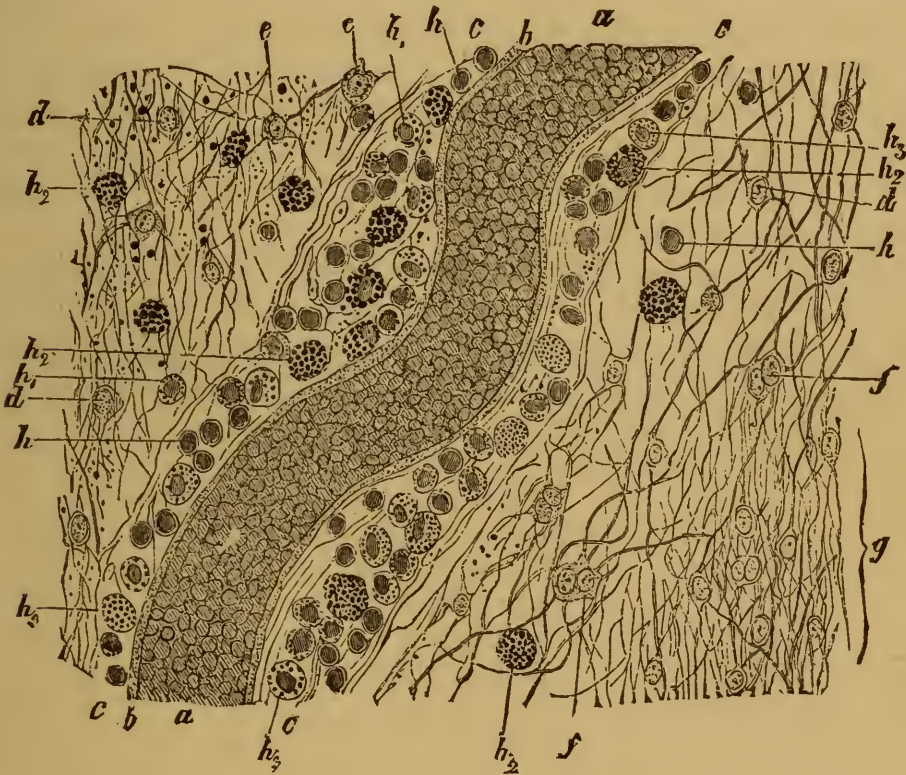

FIG. 120. SECTION THROUGH A DEGENERATING PATCH FROM THE BRAIN.

(*Perosmic acid preparation: × 200.*)

- a, blood-vessel filled with blood.
- b, tunica media.
- c, adventitia with its lymph-sheath.
- d, unaltered neuroglia-cells.
- e, fatty neuroglia-cells.
- f, binuclear neuroglia-cells.
- g, sclerosed tissue.

- h, lymphoid cells.
- h₁, lymphoid cells containing a few oil-globules.
- h₂, fat-granule carriers.
- h₃, pigment-granule cells, some containing red corpuscles.

the lymph being thus somewhat various, we may expect that morbid changes in its composition will not be uncommon. Changes in the blood

and disorders of the tissues generally give rise to changes in the lymph; and the various impurities of the blood already described are all of them apt to pass into the lymphatic system on leaving the blood-vessels. To discuss in detail the changes which may take place in the lymph would in fact require us to repeat what we have said concerning the impurities of the blood, as well as to go through all the morbid processes affecting the tissues in which the lymph-stream takes its rise.

Many of the changes referred to are not capable of microscopical demonstration, being due to substances dissolved in the lymph. As regards the formed elements, the morbid changes are either such as to relate to the quantity or quality of the lymph-cells, or to the addition of solid products of tissue-waste or of foreign matters derived from without. As an example of such changes in the normal contents of the lymph, we may refer to Fig. 120, representing a perivascular lymph-sheath (*c*) from a lunatic's brain, which contained both sclerosed and softened patches. The lymph-sheath is dilated and contains numerous cells, which are laden with colorless products of degeneration of brain-tissue (h_1, h_2), or with the *débris* of disintegrated blood (h_3). There are also lymphoid cells (*h*) not inclosing any such matters. The two former kinds of cells are foreign to the normal lymph of the brain, and even of the latter the numbers are here abnormally great.

A lymphatic vessel taken from tissue in a state of inflammation would show an abnormal increase of cellular elements in the lymph it contained; another taken from the neighborhood of a tumor would probably contain tumor-cells; a third from a region invaded by micrococci would contain colonies of these in process of development, and so on.

SECTION II.

THE VASCULAR MECHANISM.

CHAPTER VII.

MALFORMATIONS AND MALPOSITIONS OF THE HEART.

270. The development of the heart is so complex, and so dependent on the accurate co-ordination of many diverse stages and processes of growth, that its liability to malformation is not surprising. The chief abnormalities which occur are—insufficient size of the heart as a whole, and defective development of the septa and of the ostia. These are often associated with defects in the large vessels.

The **defects in the septa** may vary from the entire absence of any partition to the persistence of minute openings which have no effect whatever on the functions of the heart. The commonest defects are—patency of the foramen ovale, and deficiency of the ventricular septum beneath the aortic valves.

Defects of the ostia are generally of the nature of valvular deformities. Some of these are unimportant unless they interfere with the competency of the valves; such are excess or diminution in the number of valvular segments, and slighter anomalies in their form or relative position. When the malformation of the valves is such as to interfere with their functions by causing incompetency or stenosis, the case is more serious, and may become extremely serious. Many of the commoner valvular malformations, especially such as are of the nature of thickening, contraction, or adhesion, are referable to inflammatory affections *in utero*. Occasionally traces of such inflammations are to be found elsewhere than about the valves, and generally in the form of whitish thickenings on the surface of the endocardium (Arts. 281–283).

Development of the heart. The heart is originally formed out of two lateral mesoblastic tubes which coalesce into an undivided straight tube. This single tube is continuous in front with the two primitive aortas, and posteriorly it receives the two vitelline veins from the vascular area. In consequence of the continued growth of the single tube it becomes doubled on itself into an S-shaped structure, and presently by slight constrictions three somewhat sacculated sections can be made out. The anterior almost straight section is the aortic bulb; the middle section has somewhat thickened walls and forms the ventricular portion; the posterior section is thin-walled and forms the auricular portion.

By the continued bulging and growth of the ventricular portion the aortic bulb and the auricular portion are brought into approximate juxtaposition, and sometimes seem to twist round each other. The ventral bulge of the ventricular portion indicates the position of the future apex.

The next step is the separation of the ventricular portion into two chambers. This begins to take place about the seventh week by the development of a low crescentic fold from the inner surface of the right wall below, while an evanescent notch appears at the corresponding spot outside. The fold grows rapidly upwards towards the auriculo-ventricular opening, where it is in relation both with the auricular portion and the aortic bulb. For a time therefore communication between the ventricles is free over the top of the septal fold.

The septum of the auricles begins to appear about the eighth week as a low crescentic fold, starting from the anterior wall of the auricular portion and the upper edge of the ventricular septum. In the tenth or eleventh week two other folds grow up from the posterior wall, one coming forward to meet without adhering to the anterior fold, and forming the valve of the foramen ovale; the other fold is the Eustachian valve. The auricular septum thus remains incomplete until after birth, when the valve usually coalesces with the margin of the foramen ovale, and the latter ceases to be patent.

The division of the arterial bulb begins, about the seventh week, by the development of an internal septum proceeding from the distal end towards the ventricles. Two channels are thus formed from the single cavity, and the direction of the septum twists in such a way that the anterior channel (pulmonary artery) becomes continuous with the cavity of the right ventricle, and the posterior channel (aorta) with the cavity of the left ventricle. The septum ultimately meets and joins the septum of the ventricles.

The two primitive aortas form the first or primitive pair of aortic arches and converge dorsally and posteriorly to form a single trunk. Between the ascending and descending limbs of each arch are developed four secondary aortic arches, while the primitive arches almost entirely disappear. The great arterial trunks are derived chiefly from the three lower secondary arches, but portions of the primitive and of the highest secondary arches persist in the internal and external carotids.

271. **Defects of development in the large arterial and venous trunks** are of grave import. Such defects are very much more frequent in the arteries than in the veins. Thus we may have absence or imperfection of the septum of the aortic bulb, so that the aorta and pulmonary artery rise from a single stem. Or the position of the septum may be abnormal, whereby the aorta is displaced to the right; in extreme cases it may even arise from the right ventricle.

Of the vessels which are not directly connected with the heart the most interesting is the **ductus arteriosus** (*ductus Botalli*), which unites the pulmonary artery with the descending aorta. It naturally becomes occluded and impervious after birth, but in many cases it remains patent, especially when defects in the aorta or pulmonary artery make its persistence necessary to life. This happens notably in cases of atresia of either trunk; if blood is to reach the branches at all it must pass from the pervious trunk through the ductus into the other.

It is always to be remembered in connection with this subject that many of the minor anomalies are merely the necessary results of other more fundamental malformations. Thus the malposition of the septum of the aortic bulb may involve the displacement of the aorta to the right (ROKITANSKY), and there may in consequence be a defect in the ven-

tricular septum, even though it is sufficiently developed to have met the septum of the bulb had the conditions been normal. Similarly a primary defect in the ventricular septum may lead to secondary deformities elsewhere (ORTH). If the right auriculo-ventricular orifice should be narrowed or closed, the blood from the right auricle must pass into the left auricle; and this will naturally prevent the closure of the auricular septum. And so generally, a defect at one point is to a certain extent compensated for by a corresponding abnormality at another. Not infrequently the connected series of malformations is highly complex, so that it is not always easy to make out their mutual relations.

Summing up we may say, that the **causes of cardiac malformations** are to be sought either in lack of developmental energy, or in imperfect co-ordination of the several stages and processes of growth, or in inflammatory disease attacking the heart *in utero*.

According to FÖRSTER the chief forms of cardiac malformation are the following.

(1) Absence or deficiency of the septum of the aortic bulb, with deficiency of the other septa; of this there are various degrees:—

(a) the heart is in two parts, one corresponding to the ventricular portion and the other to the auricular portion

(b) the heart has two auricles and one ventricle.

(2) Atresia or stenosis of the aorta or pulmonary artery, with partial deficiency of the septa:—

(a) aorta narrow or impervious; pulmonary artery conveys blood to the aorta and its branches through the ductus arteriosus; auricular and often ventricular septum imperfect; left ventricle ill-developed, right ventricle large

(b) pulmonary orifice narrow or impervious; lungs supplied with blood from the aorta through the ductus arteriosus; auricular and ventricular septa generally imperfect, the latter may be closed; this form is not infrequently met with in clinical practice.

(3) Defective metamorphosis of the arterial arches:—

(a) stenosis of the aortic arch above the entrance of the ductus arteriosus; the latter remains patent and conveys blood from the pulmonary artery to the descending aorta

(b) transposition of the great trunks; aorta rising from the right, pulmonary artery from the left ventricle; septa deficient; more rarely the great veins are likewise transposed

(c) aorta and pulmonary artery both rise from the right ventricle.

(4) Patency of foetal apertures, the arteries being normal.

The commonest example is offered by the foramen ovale; minor deficiencies in the auricular septum have no effect on the circulation. The ductus arteriosus may remain open for a long time; if the channel be narrow its patency has no importance. Minor deficiencies in the ventricular septum are less common; they may become of importance if the function of the heart is impaired from other causes.

(5) Atresia or stenosis of an auriculo-ventricular orifice.

Here the auricle may be shut off from the corresponding ventricle; the septa are always deficient.

(6) Deformity of the valves.

The valves may be stunted, morbidly adherent, misshapen, or abnormally subdivided in a multitude of ways; the result may be incompetence or stenosis.

The malformations above described are often incompatible with life. In other cases life is possible but the circulation is gravely disordered, which may be indicated during life by extreme cyanosis.

References:—FÖRSTER, *Handb. d. path. Anat.* and *Die Missbildungen des Menschen* Jena 1865; PEACOCK, *Malformations of the human heart* London 1866 (with references to the earlier literature); MAIER, *Allg. path. Anat.*; ROKITANSKY *Die Defecte d. Scheidewände d. Herzens* Vienna 1875; ORTH, *Virch. Arch.* vol. 82; ASSMUS, *Deutsch. Arch. f. klin. Med.* xx.; REIL, *ibid.* xvii.; RAUCHFUSS, *Gerhardt's Handb. d. Kinderkrankh.* vol. iv. Tübingen 1878; TARUFFI, *Sulle mal. congenit. d. cuore* Bologna 1875; GREENFIELD, *Trans. Path. Soc.* xxvii. (1876); BUHL, *Zeitschr. f. Biologie* xvi.; LORENZ, *Wien. med. Jahrb.* 1880; ORTH, *Virch. Arch.* vol. 82, and *Lehrb. d. spec. path. Anat.* vol. i. Berlin 1883; DILG, *Virch. Arch.* vol. 91.

272. It is not rare for the heart to be abnormally small in proportion to the body-weight. The condition is described as **cardiac hypoplasia**. The heart is either abnormally small at birth, or it simply lags behind the body in its growth. Thus in adults the heart may be no bigger than it normally is in children of seven or eight. Such extreme cases are rare, but minor degrees are often met with. VIRCHOW showed that cardiac hypoplasia is common in patients suffering from chlorosis or hæmophilia. The aorta and arteries in such patients are usually narrow and thin-walled; while the genital organs, and sometimes the entire body, are ill-developed. General hypoplasia of the vascular system occurs in men as well as in women. As the growth of the heart is in a measure conditioned by the work it has to do, the increased resistance caused by the narrowness of the aorta may bring about a compensatory or functional hypertrophy of the heart muscle.

The abnormal thinness and narrowness of the great arteries are often associated with anomalies in their distribution; and corrugated or lattice-like irregularities of surface are also observed on the inner coat of the aorta. In such cases the aorta is peculiarly liable to fatty change, and to spontaneous rupture.

The heart may be misplaced in the thorax; the most notable case being that of transposition or **dexiocardia**. This is rarely a solitary malposition (KRIEGER, *Ueb. reine Dexiocardie* In. Diss. Berlin 1880), it is nearly always part of a general *Situs inversus* (Art. 11).

In cases of fissural malformation of the wall of the thorax and abdomen (Art. 9) the heart is not uncommonly displaced forwards (*Ectopia cordis*). The pericardium may be present or absent; but total or partial absence of the pericardium without other malformation is very rare.

References on the size of the heart and blood-vessels in normal and morbid conditions:—PEACOCK, *On the size and weight of the heart* London 1854; VIRCHOW, *Ueb. die Chlorose u. die damit verbundenen Anomal. am Gefässapparate* Berlin 1872; BAMBERGER, *Lehrb. d. Krank. d. Herzens* Vienna 1857; BENEKE, *Die anatom. Grundlagen der Constitutions-anomalieen* Marburg 1878; BUHL,

Mitth. a. d. path. Inst. zu München Stuttgart 1878; DU CASTEL, *Arch. gén. de méd.* 1880; SPATZ, *Arch. f. klin. Med.* xxx.; THOMA, *Unters. üb. d. Grösse u. d. Gewicht d. anat. Bestandtheile d. mensch. Körpers* Leipzig 1882 (with full references and very accurate measurements); MÜLLER, *Die Massenverhältnisse d. menschlichen Herzens* Hamburg 1883 (with elaborate tables).

According to BENEKE the volume of the heart in new-born infants is 20-25 ccm.; when its development is complete 215-290 ccm.; in the prime of life 260-310 ccm. In cases of hypoplasia the volume may be reduced by a third or more.

CHAPTER VIII.

ATROPHY AND DEGENERATION OF THE HEART.

273. Simple brown atrophy. In patients who have died of general marasmus the heart is often found to be greatly reduced in size. The investing fat is almost or altogether transformed into a gelatinous or mucoid substance, occasionally stained with yellowish pigment. The superficial cardiac vessels lying under the visceral pericardium are much convoluted from the shrinking of the subjacent structures; the cavities are small; and the muscular walls are thinned. They are also firmer than normal, and stained of a brownish tint. The endocardium is apparently thickened, but this is due to its enforced adaptation to a smaller surface than it originally covered. Indeed in simple cases the muscle-cells are the only elements which are altered (Fig. 121). The muscle-cells are abnormally small, and contain numerous fine yellow pigment-granules lying chiefly at the poles of the nuclei, but also scattered through the protoplasm of the cells. These retain their normal striation. If it were necessary we might distinguish some cases as exhibiting simple pigmentary atrophy, and others brown pigmentary atrophy, according to the amount of pigment present. Brown atrophy is not infrequently associated with fatty degeneration




FIG. 121. BROWN ATROPHY OF THE MUSCLES OF THE HEART.

(Teased preparation; $\times 350$.)

274. Fatty degeneration and cloudy swelling.

Fatty degeneration is one of the commonest affections of the substance of the heart and not infrequently a cause of death. It is either uniformly diffused over the heart-muscle, or concentrated at certain spots. In the former case if the affection is at all advanced the muscular substance appears pale, yellow, limp, and easily torn; in the latter case it is speckled or mottled. The mottling is most beautifully seen in the papillary muscles and the trabeculæ of the right heart; the delicate and often regular yellowish streaks recalling the grain of some fine cabinet wood. Less intense degrees of fatty change are indicated by simple yellowish discoloration; but certainty of diagnosis is often only to be attained by the aid of the microscope. A fatty muscle-cell is interspersed with minute colorless dark-bordered oil-globules, whose number varies much according to the degree of degene-

ration which exists. At times they are so numerous that both nucleus and striation are overlaid and disappear. But even in such extreme cases the globules do not coalesce into large drops.

Fatty degeneration of the heart is usually very gradual in its onset. It is most commonly a result of valvular lesions, pulmonary emphysema, or general anæmia, that is to say of disorders involving malnutrition of the heart-substance. According to EICHHORST (*Die troph. Beziehungen d. Nerv. vagus z. Herzmuskel* Berlin 1879) section of the vagi is followed by fatty degeneration of the heart. Acute fatty change is likewise observed in the course of infective and toxic affections. In such cases a stage of cloudy degeneration (Art. 48) precedes the fatty change, the muscular fibres assuming a peculiar grayish-yellow tint and a dull fish-like lustre. The muscle-cells look as if powdered, and contain fine albuminous granules which disappear when treated with acetic acid. In the later stages fat-globules appear. If the fatty degeneration of the heart is extreme it may lead to rupture of its walls, and so to fatal hæmorrhage.

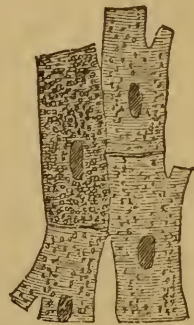


FIG. 122. FATTY DEGENERATION OF THE MUSCLES OF THE HEART (× 350).

275. **Fatty degeneration of the endocardium** is to be distinguished from the like change in the heart-muscle. It appears in the form of circumscribed patches of an opaque white color. The connective-tissue cells of the intima (Fig. 123) are found to be filled with larger or smaller oil-globules. These patches

are most commonly seen on the valves, and especially the mitral valve. They may be quite small, or may cover the greater part of the valve. They usually occur in aged persons, whose vascular system elsewhere shows signs of analogous change. But they may also be found in younger persons, and even in children, especially such as have died of general marasmus or anæmia, or from some imperfection of development in the vascular system.

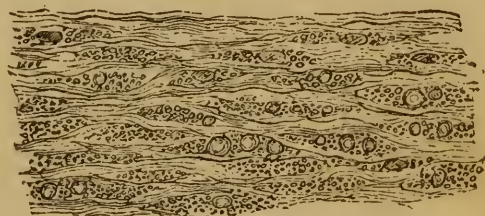

FIG. 123. SECTION OF FATTY ENDOCARDIUM. (From the mitral valve of a child dead of scurvy; perosmic acid preparation; × 350.)

Amyloid degeneration likewise attacks the connective tissues of the heart. A slight amount of amyloid change, only to be made out by proper reagents under the microscope, is not uncommon and may occur in any part of the heart-wall. Well-marked change recognizable by the naked eye is rare. When it occurs (Art. 59), and extends to the fibrous tissues of the endocardium, myocardium, and pericardium, these become remarkably thickened. The thickening may be uniform and smooth surfaced, or it may be irregular and nodular; so that, for example, the surfaces of the valves may become remarkably rough and granular. Within the heart-wall the amyloid tissue forms patches and swathes and

bands, between which the muscular tissue is apt to atrophy. The amyloid tissue is distinguished from the ordinary fibrous tissue by its greater translucency and firmness. Where the fibrous tissue is vascular, the amyloid change is particularly apt to attack the walls of the vessels.

276. **Hyaline and mucoid degeneration of the endocardium** is very common. It may almost be regarded as a physiological change accompanying old age, when the endocardium, especially that covering the valves, undergoes a certain amount of thickening; it merely implies an increase of connective tissue. But it not infrequently takes place in an irregular manner, leading to the formation of flattened or nodular or even pectiniform prominences on the surface. Such growths are chiefly found near the free edges of the valves, but they also occur at their bases and on the tendinous cords. The *corpora Arantii* of the aortic valves are very apt to be thickened in this way.

A certain amount of textural change is usually associated with the thickening of the tissues. The fibrous texture is gradually lost and the tissue becomes homogeneous, while the nuclei dwindle and disappear. This homogeneous or hyaline change with thickening somewhat resembles amyloid degeneration; but it may appear simultaneously with the latter, it generally occurs under altogether distinct conditions, and it gives no reaction with iodine.

The homogeneous degeneration may ultimately lead to necrosis of the affected tissue, which thereupon becomes turbid and breaks up into granular detritus. Not infrequently fat is formed in the tissue before necrosis sets in; and calcareous salts may likewise be deposited. Such changes are included under the term **atheroma**. The affected spots have first a dull white look, but when calcareous deposits have been made the tissue becomes hard and rigid and of a brilliant white color.

As a sequel to homogeneous degeneration in old age, or at times independently of it, we may have mucoid degeneration. The tissue assumes a clear jelly-like appearance, readily distinguishable from the brilliant white of the thickened calcareous patches. The change occurs in spots, generally in the neighborhood of the mitral and aortic valves; the *corpora Arantii* of the latter are favorite sites.

In mucoid degeneration the ground substance of the tissue becomes liquefied, with the formation of mucin. In extreme cases the ground-substance may entirely disappear. Fatty and calcareous change is often associated with the mucoid change.

Inflammatory processes are very apt to be set up in connection with the various degenerations described in this Article, and with the necrosis which they frequently induce. Such processes lead to infiltration of leucocytes around the foci of degeneration; and in this way new fibrous tissues may occasionally be formed.

277. **Myomalacia cordis** is the name given to a peculiar softening of the muscles of the heart, consequent on arterial anæmia (ischæmia).

The commonest cause of such anæmia is disease (such as sclerosis or atheroma) of the nutrient arteries of the heart, the coronary arteries and their branches; more rarely it may be due to coronary embolism.

The softened spots have different appearances according to their age and the amount of blood they contain. When the softening is recent, the spots are pale yellow and the tissue soft and fragile; sometimes the cut surface of a cross-section sinks in so as to become concave. If in consequence of the occlusion of an artery there has been an extravasation of blood from the capillaries, so that an infarct is produced, the softened patch becomes uniformly dark-red, or else mottled with red, brown, and yellow. After a time it turns grayish-yellow or rusty brown, and ultimately a translucent gray. Such patches are oftenest found in the wall of the left ventricle, especially near the apex; but they also occur elsewhere, as in the right ventricle. The papillary muscles may likewise undergo localized softening; or the entire muscle may be transformed into a grayish-yellow or semi-translucent mass. If the softening reach the endocardium thrombi (taking the form of cardiac polypi) may be formed over the spot.

When the softening is so extensive as to include almost the entire thickness of the heart-wall, rupture of the heart will result, and blood escapes into the pericardial sac. The rent is generally irregularly serrated, and is seldom large.

The tissue-changes underlying the varying appearances of the softened patches are partly retrogressive and partly constructive. The original ischæmia first of all brings about the destruction of numbers of muscle-cells. In the yellowish patches the muscular fibres are in various stages of degeneration and disintegration. This can be demonstrated in teased preparations, in which irregular fragments of muscle-cells and masses of granular detritus are seen. Generally some formation of oil-globules has also taken place. Sections of the muscular wall show the destructive process even better than do the teased preparations. Fig. 124 represents a section through a degenerating muscular bundle. In the upper part the muscle-cells are still unaltered and present the ordinary appearance (*a*). In the middle the cells (*b*) are beginning to break up into fragments, while below (*c*) they are completely disintegrated into granular detritus. The destruction is often limited to the muscle-cells, but at times the connective tissue likewise suffers; in such cases the nuclei cease to take up color when the section is stained (*d*), and granules are deposited among the pale fibrils of the connective tissue.

When hæmorrhage occurs as an accompaniment, we may find entire or fragmentary blood-cells mingled with the connective tissue and in part replacing the disintegrated muscle-cells; and in later stages the tissue will contain pigment-granules.

When the destructive process has gone a certain length, and death does not ensue, processes of repair are set up. The detritus is re-absorbed

and carried off, and the gap filled up by scar-tissue. Migratory leucocytes pass out of the vessels, and reactive inflammation begins. The detritus is for the most part taken up by these migratory cells, in part also taken up by the vessels directly or in solution. Ultimately fibrous tissue develops from the granulation-tissue built up by the leucocytes and perhaps by the multiplication of the fixed tissue-cells of the surrounding parts; but the muscle-cells are not reproduced. After a time the affected area is thus filled up with fibrous tissue containing a certain number of cells in its meshes. The muscle-cells which survive lie embedded in the new-formed tissue; and if hæmorrhage has occurred the tissue will also contain flakes and granules of pigment.

To the unaided eye the presence of the scar-tissue is manifested by its

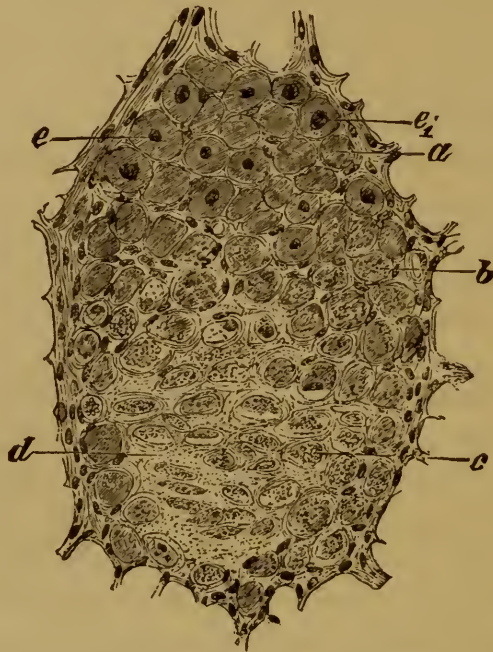


FIG. 124. MYOMALACIA CORDIS.

(Section through a degenerating muscular bundle: double staining with hæmatoxylin and carmine: $\times 300$.)

- | | |
|---|-----------------------------------|
| a, normal muscle-cell. | d, non-nuclear fibrous tissue. |
| b, disintegrating muscle-cell. | e, normal nucleus of muscle-cell. |
| c, completely degenerate muscle-cell resolved into granular detritus. | e ₁ , swollen nucleus. |

grayish translucent look when recent, and its glistening white color when more mature; the scar moreover seems to ramify through the muscular substance. Such scars are referred to as fibroid indurations or **scleroses of the heart**, and may thus represent the last stage of a localized softening. The bulk of the scar is usually less than that of the muscle it replaces, so that the heart-wall is abnormally thin at the affected spot (Art. 285).

Myomalacia cordis has hitherto received but little attention as an integral process; it has been treated under many and various partial names. Clinical observers generally confound it with myocarditis or with fatty degeneration; though

it agrees in strictness with neither. The affection is really anæmic necrosis. Fatty change and inflammation do in fact at times accompany it, but not as chief or primary conditions. Cardiac softening is altogether comparable with cerebral softening, or encephalomalacia. It is not a rare affection, and when at all extensive it brings about death by failure or rupture of the heart. It has been treated of by TAUTAIN (*De quelques lésions des artères coronaires comme cause d'altération du myocarde* Thèse de Paris 1878), and LAVERAN (*Union méd.* 23, 1878): compare also WILKS AND MOXON, *Path. Anat.* p. 122 London 1875; HUBER, *Virch. Arch.* vol. 89 and ZIEGLER, *ibid.* vol. 92; FAGGE, *Trans. Path. Soc.* XXV. (1874); TURNER, *Trans. intern. med. congress* vol. I. London 1881.

SAMUELSON (*Zeitschr. f. klin. Med.* II.), and COHNHEIM with v. SCHULTHESS RECHBERG (*Virch. Arch.* vol. 85) have recently investigated experimentally the effect on the heart of closing the coronary arteries. According to the latter clamping the coronary artery in the dog has no immediate effect on the heart's action, but after some 30 to 60 seconds the aortic blood-pressure sinks suddenly to zero, and the heart stands still in diastole. SAMUELSON operated on the rabbit and attempted to close and open the coronary artery alternately; he generally found that the aortic blood-pressure sank gradually. As in man the closure of the arteries must usually be gradual and at most affects only certain branches, the clinical symptoms usually differ somewhat from those which the experiments might suggest. The affection is manifested by gradually increasing failure of the heart's action, with angina pectoris and pulmonary congestion.

In cases of myomalacia we may sometimes see in the neighborhood of the softened fibres muscle-nuclei which are enormously enlarged, and stain very readily. ZIEGLER is unable to say what this may signify. In his researches on the subject he was never able to detect any sign of regeneration of muscle, so that there seems no reason to regard the appearance as evidence of any formative process. It is probably due to simple swelling or imbibition.

LANCEREAUX, IWANOWSKY, PUTJATIN (*Virch. Arch.* vol. 74), and USKOW (*ibid.* vol. 91) have pointed out that in various chronic affections of the heart certain changes take place in the cardiac ganglia; the changes may be degenerative or inflammatory.

CHAPTER IX.

HYPERTROPHY AND DILATATION OF THE HEART.

278. Enlargement of the heart, when not due to the presence of a tumor, is caused either by the dilatation of its cavities, or by the hyperplasia of its walls, generally of their muscular tissue but occasionally of their adipose tissue. Both dilatation and hypertrophy may exist at the same time.

In **simple dilatation** the auricular and ventricular cavities are enlarged, while the muscular walls are thinned by distention. The dilatation is often unilateral, that is to say confined to the right or to the left heart.

Hyperplasia of the cardiac tissues is generally due to true **hypertrophy of the muscular elements**, the walls becoming abnormally thick. It may be confined to the walls alone, or may extend to the trabeculæ and papillary muscles; indeed the latter may show the change more strikingly than the other parts. If no secondary degeneration has intervened the hypertrophied muscle appears firm and brownish-red in color. The general texture is not altered, but the muscle-elements are larger and more numerous than is normal. Higher degrees of hypertrophy are palpable even without section, the resistance and firmness of the walls being greatly increased.

The size of the cavities in hypertrophy varies much. If dilatation coexist with hypertrophy, so that the cavities are larger than normal, we speak of it as **excentric hypertrophy**; if they are smaller it is **concentric hypertrophy**; if they are of normal size, it is **simple hypertrophy**. Very frequently the hypertrophy is not general, but confined to one side only. Hypertrophy with dilatation of the right heart involves increase chiefly in the transverse dimensions; hypertrophy with dilatation of the left heart increases rather the longitudinal or apex-to-base measurement.

According to BENEKE (*Die anat. Grundlagen der Constitutions-anomalieen* Marburg 1878) the normal volume of the adult male heart is 260–310 ccm. for a stature of 167–175 cm.; or 150–190 ccm. for every 100 cm. of height. The growth of the heart is most rapid at two periods of life, namely during infancy, and at the time of puberty; it is much less rapid in the interval. In cases of hypertrophy the volume of the heart may rise to 500–700 ccm.; or 300–400 ccm. for every 100 cm. of height.

279. **Dilatation of the heart** is in part due to increased resistance opposed to the heart's contraction, and in part to textural change in its walls.

Hypertrophy of the heart is the result of increased work, and is a true functional hypertrophy. It of course implies not merely that increased work is called for, but that the conditions as regards increased nutrition of the cardiac tissues are sufficiently favorable; if the conditions were unfavorable the only result of increased strain (that is increased resistance to be overcome) would be dilatation.

The work required of the heart may be increased from various causes. Congenital narrowness of the aorta may induce hypertrophy of the left ventricle even in an infant, if it is well nourished. Other congenital affections leading to left hypertrophy are—affections of the valves producing incompetency or stenosis of the aortic orifice (Arts. 281–284); affections of the arteries, such as atheroma or sclerosis of the intima (Art. 297), and aneurysms (Art. 303), both of which increase the arterial resistances; partial destruction of the renal epithelium, and disorders of innervation, by which two latter causes the functional activity of the heart is increased. Pericardial adhesions may likewise induce compensatory hypertrophy. Right hypertrophy is the result of disease at the mitral or pulmonary valves, and of affections of the lungs in which the capillary area is seriously diminished or extensive pleural adhesions are formed.

Hypertrophy which follows as the result of visible anatomical lesions of the vascular system, or of the kidneys, or as the result of increased action due to nervous influences, is usually referred to as symptomatic hypertrophy. An idiopathic form of hypertrophy is also described, which is not referable to any increase in the heart's work; but this must be at least very rare. Even if in many instances we are unable to demonstrate anatomically the factors on which the hypertrophy depends, we cannot at once infer that during life no cause existed which involved an increased demand on the heart. Within recent years observation has shown that long-continued bodily exertion is particularly apt to cause functional hypertrophy; and according to TRAUBE luxurious habits of life may produce a like result.

Fatty enlargement of the heart, obesity or lipomatosis, is due chiefly to the deposit of fat in the subpericardial connective tissue. The normal investment of fat is abnormally increased by increased supply and decreased consumption. The connective-tissue cells normally free from fat are transformed here and there into fat-cells, so that adipose tissue appears not only on the surface, but also in the intermuscular septa. In extreme lipomatosis the endocardium may also contain adipose tissue, and the function of the heart may be seriously interfered with.

The fact that hypertrophy of the left ventricle is associated with certain acute and chronic renal affections has been variously accounted for by various authorities. Some look for the cause of the hypertrophy in a general increase of the volume of the blood (TRAUBE, BAMBERGER), others in some change of its composition (BRIGHT, SENATOR, EWALD), others again in a wide-spread change (arterio-capillary fibrosis) in the walls of the smaller arteries (GULL and SUTTON). BUHL refers it to "post-inflammatory over-nutrition" of the heart. The outcome of recent research undoubtedly is—that cardiac hypertrophy following upon renal disease is dependent on increased arterial blood-pressure. COHNHEIM explains the increase of pressure thus: the degree of tonic contraction (*i. e.* the calibre) of the renal arterioles is determined simply by the proportion of urinary matters contained in the blood which circulates through them; the supply of blood to a diseased kidney is as great as to a healthy one; if abnormal resistances are interposed beyond the renal arterioles, in the capillaries or glomeruli, for example, the pressure in the renal arteries and so throughout the system must rise.

The most likely view is—that the increase of arterial pressure is due to increased resistances in the arterioles throughout the entire body. When cardiac hypertrophy is induced by primary renal disease we must conclude that the resistances to the circulation outside the kidneys have been increased in consequence of the renal affection. The increased resistance is due to a contraction of the arterioles, and this is brought about either by the direct action of the urinary matters in the circulation, or by reflexes from the kidneys, or by stimulation of the vaso-motor centre.

References:—TRAUBE, *Gesamm. Abhand.* II., III.; JOHNSON, *Med. Chir. Trans.* XXXIII. (1850), LI. (1868); GULL and SUTTON, *ibid.* LV. (1872); BUHL, *Mitth. path. Inst. zu München*, 1878; BAMBERGER, *Samm. klin. Vorträge* 173; EWALD, *Virch. Arch.* vol. 71; SENATOR, *ibid.* vol. 73; GRAWITZ and ISRAEL, *ibid.* vol. 77; ISRAEL, *ibid.* vol. 86; COHNHEIM *Allg. Path.* II.; ROY, *Proc. Camb. Phil. Soc.* IV. (1881); ZANDER, *Morbus Brightii u. Herzhypertrophie* In. Diss. Königsberg 1881, and *Zeitschr. f. klin. Med.* IV. (with an elaborate discussion of the various theories); Discussion, *Trans. intern. med. congress* vol. I. London 1881.

CHAPTER X.

ENDOCARDITIS AND MYOCARDITIS.

280. **Acute endocarditis** is an inflammatory process set up by the presence in the blood of some irritant substance. It most commonly attacks the valves, but it may occur at any point of the endocardial lining. It usually takes the form of 'vegetative' or 'wartlike' endocarditis, which is characterized by the formation of small knotty and wartlike growths or vegetations, translucent or grayish or yellowish in tint, and projecting from the surface of the membrane. These are often overlaid and concealed by white or reddish or mottled thrombi.

The **valvular vegetations** generally form in rows along the lines of contact of the valves in closure; but they may be spread over the surface of the valves, or aggregated in groups to form large nodular or cauliflower-like excrescences. When they affect other parts, such as the wall of the auricle, the ventricular septum, the apex, etc., they are in general disposed irregularly, and may be aggregated into nodular masses or scattered in isolated patches. If the separate vegetations are all small but numerous and closely set, they may give the surface a granular or shaggy or merely turbid appearance; and close examination may be required to make out their individual existence. In the mildest forms no prominences above the surface are formed, so that the true nature of the patches is only to be made out with the microscope.

281. The vegetations consist essentially of subendocardial exudations and infiltrations.

The surface layers of the fully-developed vegetation (Fig. 125 *c*) are made up of granular (*e*) and fibrinous masses, which are for the most part merely coagulated exudations. Now and then patches appear which are distinguished by their fine and uniform granulation (*g*), and by their avidity for anilin-stains; they are possibly colonies of micrococci.

Among the granular masses certain peculiar colorless flakes or protoplasmic lumps (*f*) appear, which are probably nothing more than necrosed and coagulated endocardial cells. This is rendered more likely by the gradual transition observable between the persisting nucleated endocardial tissue and the non-nucleated lumps. The deeper layers (*d*) of the growth are infiltrated with small leucocytes, the infiltration extending in places to the superficial granular masses and to the deeper subendocardial tissues (*b*).

The genesis and the significance of the process are apparent from the consideration of such a vegetation. We see that it is an exudative inflammation, in which the exudation permeates the tissues and in part coagulates. Where coagulation takes place the tissue undergoes necrosis: where there has been only an infiltration of leucocytes the tissue persists.

The inflammatory process is therefore diphtheritic in its nature (Art. 103). It is closely related to superficial diphtheritic inflammation of the mucous membranes (Art. 435), and to pustulation of the cutaneous surface (Art. 388).

As we have already said, vegetations are not an invariable accompaniment of endocarditis. The inflammatory change is often recognizable only by the existence of more or less marked infiltration of the fibrous tissues of the lining membrane.

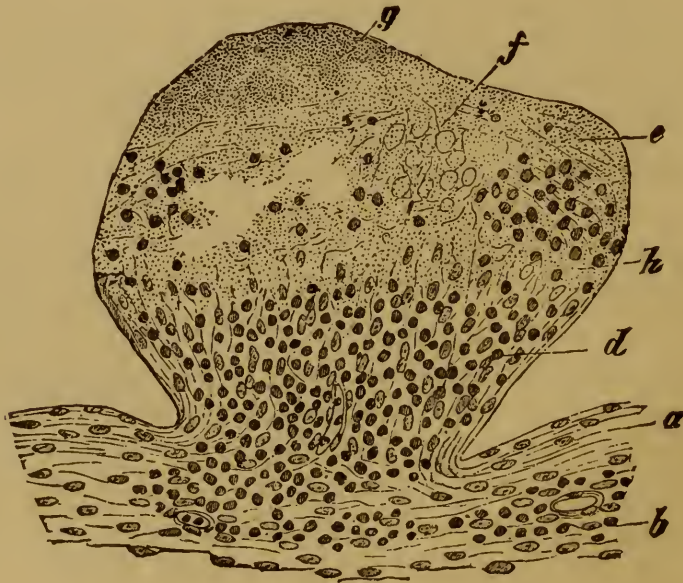


FIG. 125.—SECTION THROUGH AN ENDOCARDITIC VEGETATION.

(From the auricle : hæmatoxylin staining : $\times 150$.)

- | | |
|---|--|
| a, endocardium. | f, colorless denuded protoplasmic masses. |
| b, subendocardial fibrous tissue, partly infiltrated with leucocytes. | g, finely granular substance (? micrococci). |
| c, the vegetation. | h, zone of transition from the undestroyed infiltrated tissue to the necrosed and coagulated tissue. |
| d, infiltrated leucocytes. | |
| e, upper part of the growth consisting of fibrous and granular coagula. | |

The cause of the inflammatory exudation is in some cases at least to be set down to the settlement of morbid organisms in the tissues. KLEBS (*Arch. f. exp. Path.* IX.) and EBERTH (*Virch. Arch.* vol. 72) have demonstrated the presence of microparasites in endocarditis. Whether the granular masses represented in Fig. 125 g are really micrococci is questionable, for the staining is not very intense. ZIEGLER met with a case of acute vegetative endocarditis, in which metastatic inflammations of the heart-substance and of the kidneys appeared, and in this he found colonies of micrococci in the blood-vessels of the affected organs. NAUWERCK recently found numbers of similar colonies in a case which

proved fatal after four months' duration. The colonies existed not merely in the thickened vegetations of the valves, but also in the still unaltered parts of the endocardium and in the muscular wall.

Endocarditis most commonly occurs associated with rheumatic affections, especially with acute general rheumatism, now regarded by some as of micro-parasitic origin. But it is also found in other conditions, as in measles and scarlatina and in fatal cases of nephritis, pneumonia, typhoid, septicæmia, etc. Very commonly, too, it develops in patients who are sinking under chronic suppurations, especially in the course of ulcerative cancer, or phthisis. LEYDEN says it also occurs after gonorrhœa. These facts point on the one hand to the conclusion that endocarditis is produced by bacteria, and on the other hand that the bacteria are not always of the same form, perhaps are of different species. In other words the etiology of endocarditis is probably multiform, not simple (Art. 204).

282. The ultimate course of endocarditis varies in different cases. The superficial granular masses and the investments of fibrin overlying the vegetations are incapable of organization. Small portions or patches may be absorbed, or may become calcified. Very often the growth softens and portions of it are swept off by the blood-current; and calcified masses may be swept off in like manner. In either case embolism is the result.

As necrosed masses are thus washed out excavations remain which are practically ulcers; they may be small or large. In so-called **ulcerative endocarditis** the destruction of tissue goes deeper still, so that a valve, for instance, may be deeply and extensively eroded by ulceration. In this way the weakened and infiltrated tissue which remains may give way under the pressure of the blood, and a sacculation, or acute valvular aneurysm, may be produced; or the process may go further and lead to perforation, and even to the detachment of a considerable fragment of the valve. Similar ulcerations may involve other parts, such as the *chordæ tendineæ*, which may in this way be severed from their valvular attachments.

Ulcerative endocarditis is usually the result of pyæmic or septic infection.

The vegetative and ulcerative forms pass gradually into each other, so far as their anatomical manifestations are concerned. The ulcerative form has usually been compared to the diphtheritic inflammations of the mucous membrane, but this is less than the truth; the vegetative form is likewise a diphtheritic inflammation with coagulative necrosis of the solid tissues. The two forms seem moreover to differ etiologically; the pernicious or ulcerative type being associated with septic or pyæmic processes, the vegetative with articular rheumatism. EBERTH (*Virch. Arch.* vol. 57 and *Corresp. f. schweiz. Aerzte* 1872) was the first who demonstrated the presence of bacteria in ulcerative endocarditis. Since then the fact has more than once been verified (MAIER, *Virch. Arch.* vol. 62; BURKART, *Berl. klin. Woch.* 1874; SANSOM *Lettsomian lectures* London 1883).

Perforation of the valves as a consequence of inflammation is not to be confounded with so-called **fenestration**, often found as a congenital anomaly in the sigmoid valves *above* the lines of contact in closure. This condition differs

essentially from the other, not merely in the difference of its site but in the absence of inflammatory infiltration or fibrous thickening around the hiatus.

283. **Results of endocarditis.** If an attack of endocarditis does not prove fatal in its early or acute stage, certain plastic or formative inflammatory processes are set up at the affected spot, which result in the formation of new tissue and the cicatrization of the defect. The tissue in which the new formation starts is that which has not succumbed to the severity of the disease; the tissue in fact which is infiltrated but not necrosed. The raw material for new tissue is present, and the fixed cells of the old tissue are intact.

For weeks and months after the commencement of the disease the thickened tissues of the inflamed valves are still notably infiltrated with young cells, and may here and there have the appearance of ordinary granulations. Very probably the migrated leucocytes, and it may be the proliferous fixed cells, act as the builders of the new tissue; and their activity is maintained by the formation of new capillaries.

These plastic processes lead to more or less considerable thickenings of the endocardium. In the ventricles and auricles they appear as dense opaque white patches, which may be indefinite or sharply circumscribed.

The segments of the valves are thickened, hardened, coherent, and deformed in a multitude of ways. The tendinous cords are likewise thickened and shortened, and their ramifications abnormally adherent.

Degenerative change frequently attacks these inflammatory thickenings, and that in any of the forms mentioned in Art. 276. Fatty degeneration, and atheroma with calcification, are the commonest forms.

The result of these changes very often is that the valves are rendered functionally imperfect. Thickening and adhesion lead to narrowing of the ostia, or **stenosis**; retraction or deformity of the segments and cords to imperfect closure of the ostia, or **incompetence**. Both stenosis and incompetence may exist at the same orifice. It would be impossible to give in detail all the varieties that occur. In mild cases the thickening is slight and confined to the free margin of the valve and perhaps one or two of the cords. In severer cases the normal configuration of the valvular apparatus may be entirely lost. Thus the mitral opening is often reduced to a mere chink at the end of a funnel-like projection, surrounded by dense, firm, and all but immovable masses of fibrous tissue. If calcification ensue the parts round the ostium may become perfectly rigid and immovable.

We have already alluded to the results of valvular disease of this kind. In general terms they are these: the difficulties in the way of emptying the heart at each systole, whether from stenosis or regurgitation, are such that the blood tends to collect in the ventricle; the vascular system behind the diseased valve is permanently over-distended with blood, and so becomes dilated; and the heart hypertrophies to meet the

increased resistance, beginning with the part which serves to drive blood through the diseased valve.

284. **Myocarditis** not uncommonly accompanies endocarditis, the inflammation extending by continuity from the endocardium to the subendocardial and intermuscular connective tissue. In other cases the process may begin in the muscular tissue itself. In either instance the inflammation is characterized histologically by the appearance of an infiltration of leucocytes in the tissue of the heart-wall.

Two forms of myocarditis are distinguished, according as the disease results in induration or in abscess. **Indurative myocarditis** leads to hyperplasia of the intermuscular fibrous tissue, and the formation of ten-

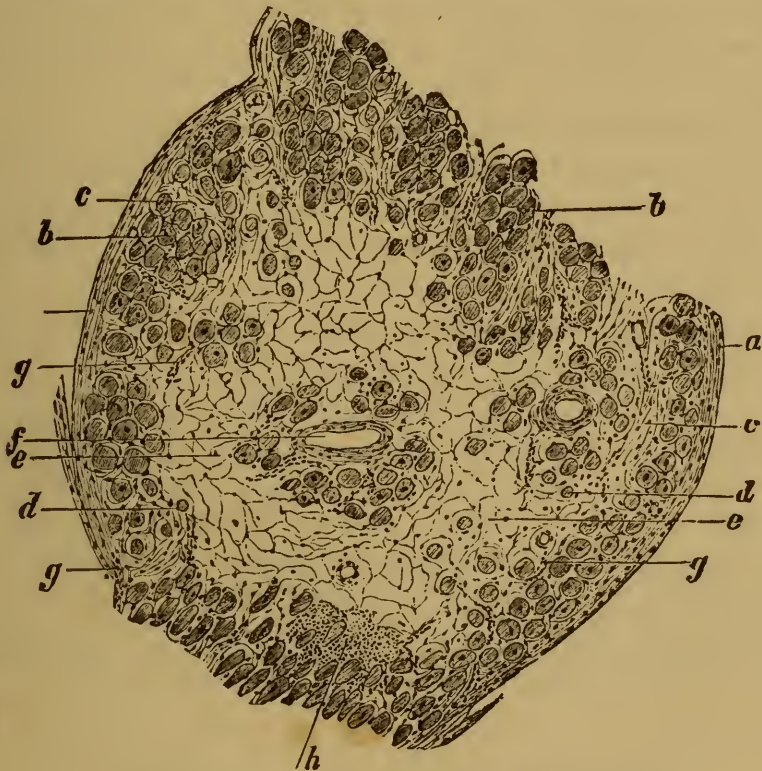

FIG. 126. SCLEROSIS RESULTING FROM MYOCARDITIS.

(Section through a fibroid trabecula : hæmatoxylin staining : $\times 40$.)

- | | |
|--|---|
| a, endocardium. | e, dense connective tissue with few nuclei and no muscle-cells. |
| b, normal muscle-cells. | f, vein, surrounded by a few intact muscle-cells. |
| c, hyperplastic connective tissue rich in cells. | g small blood-vessels. |
| d, atrophied muscle-cells amid hyperplastic connective tissue. | h, infiltration of leucocytes. |

don-like scleroses or thickenings (Art. 277), composed of glistening white bands or patches of dense fibrous tissue. As endocarditis is generally present at the same time, the endocardium will show similar tendinous streaks and patches on its surface. Not infrequently some of the muscular trabeculæ are transformed into coarse fibrous cords.

The new fibrous tissue (Fig. 126 e) when fully-developed is dense and almost free from cells ; if the inflammatory process is kept up, it may still contain infiltrated leucocytes (h) in some spots.

The muscle-cells have in many places disappeared ; in other places, especially near the periphery, they remain but show evident signs of atrophy (*d*). When the inflammation is more recent, the tissue is grayer or more reddish, and richer in cells and in vessels. At first nothing is seen but an infiltration of small cells, amid which the muscle-cells appear in various stages of disintegration ; and sometimes hæmorrhage occurs. The disintegrated muscle-cells are not afterwards replaced.

The smaller scleroses have no serious effect on the heart's function ; but the larger ones which involve a considerable extent of the muscular substance may have a very harmful effect. The new tissue is not contractile, and so does not take a share in the general contraction of the heart ; while if it is at all pliable or distensible the blood-pressure may force it to give way and bulge into a sacculation, and thus an **aneurysm of the heart** is formed.

Parulent myocarditis usually accompanies pyæmic infections, and is due to bacteria which have reached the heart-muscle through the coronary arteries. Small yellowish or grayish abscesses are formed. They may break inwardly, and lead to cardiac ulcer ; or outwardly and set up pericarditis.

Larger myocarditic abscesses may lead to rupture of the heart.

As we have said, the ætiology of myocarditis corresponds in general with that of endocarditis ; but there are certain irritants which may set up myocarditis though they do not usually affect the endocardium. Thus according to LEYDEN (*Zeitschr. f. klin. Med.* IV.) the poison of diphtheria often causes myocarditis, while endocarditis a rare complication. ROSENBAACH (*Virch. Arch.* vol. 79) found granular and waxy degeneration of the heart-muscle in diphtheria. LEYDEN moreover states that the virus of small-pox, of epidemic meningitis, or of relapsing fever, may bring about myocarditis.

On the myocarditis and sclerosis that follow myomalacia see Art. 277.

CHAPTER XI.

INFECTIVE GRANULOMATA, TUMORS, AND PARASITES OF THE HEART.

285. **Tubercle** is the commonest of the granulomata affecting the heart; **syphiloma** is more rare. In acute miliary tuberculosis the heart does not escape the general invasion ; but it is much less common to find larger caseous nodules in its substance. When they do occur it is almost invariably in connection with like caseous nodules in the pericardium. Gummata are very rare. They lie in the wall of the heart embedded in dense hyperplastic fibrous tissue ; and according to their age appear as soft reddish or grayish patches, or as dry yellow cheesy nodes. Simple inflammatory indurations of the heart-muscle occur as a consequence of congenital or acquired syphilis, and these are more common than gummata.

Of the **true tumors** several kinds may attack the heart primarily, such as sarcoma, fibroma, lipoma, myxoma, and myoma ; but they are all of them rare.

Secondary tumors are more frequently found, especially secondary carcinomata. The tumor-germs, other than those that seize upon the heart from the pericardium, reach the heart-muscle through the circulation. The growths may be seated in the substance of the wall, or may protrude into the cavities, or into the pericardial sac. Occasionally tumors attack the heart by continuity from the mediastinum, the œsophagus, or the stomach.

The effect of such tumors on the heart will of course depend on their seat and size. If large they may interfere seriously with its action. Thrombi readily form on tumors which project into the cavities. Softening and ulceration of new growths may lead to rupture of the heart.

Of **parasites** *Cysticercus* and *Echinococcus* are found in the heart. *Echinococcus* (hydatids) may lead to its rupture.

For references see ORTH'S *Lehrb. d. spec. path. Anat.* vol. I. Berlin, 1883.

CHAPTER XII.

HYPOPLASIA AND DEGENERATION OF THE VESSELS.

286. A blood-vessel consists essentially of an endothelial tube; but all vessels above a certain size have their endothelial walls strengthened by the addition of connective tissue, elastic tissue, and muscle-cells; and all again above a somewhat larger size have nutrient vessels of their own, the so-called *vasa vasorum*.

The diseases of the vessels are processes affecting the vessel-walls alone, or the vessel-walls with the surrounding tissue; or they may form merely a part of some general affection of the parenchyma of the organs through which the vessels run. The latter is especially the case with the smaller vessels embedded in the substance of the organs.

The **malformations of the vessels** which have clinical importance have already been referred to in treating of the malformations of the heart. Here we need refer again only to the condition of general undergrowth or hypoplasia of the vessels associated with chlorosis, and characterized by abnormal narrowness of the channels and thinness of the walls, especially of the greater arteries. The very frequent anomalies of position, course, and distribution which are met with in arteries and veins are treated of in text-books of normal anatomy.

According to BENEKE (*Die anat. Grundlagen d. Constitutions-anomalieen* Marburg 1878) the circumference of the ascending aorta in a new-born infant is 20 mm., in an adult 60 mm.; the pulmonary artery measuring 23 mm. and 65 mm. in the two cases respectively. Above the bifurcation of the abdominal aorta the circumference in the adult measures 32 mm.

287. **Simple atrophy** of the walls of arteries and veins is observed in connection with general marasmus and atrophy of individual organs. After amputation of a limb the vascular trunks of the stump usually become smaller. Instead however of this simple and uncomplicated atrophy we more often find evidence of partial disappearance of some constituent (such as the muscular fibres) of the vessel-wall, the result of inflammatory or degenerative change.

Fatty degeneration of the vessels is the most frequent of all the degenerative changes to which they are subject. It usually attacks the inner and middle coats, more rarely the adventitia.

Fatty change of the intima is most commonly exemplified in the aorta,

but it is frequent enough in the larger arteries, including the pulmonary artery.

The slightest degree of fatty change is not apparent to the naked eye. More marked degrees are characterized by the opaque whitish or yellowish appearance of the affected spots, which are usually somewhat irregular in outline. The surface is at first smooth, but in latter stages it becomes uneven or velvety.

The process begins with the fatty degeneration of the cells, which become filled out with oil-globules (Fig. 127 *A*). If the change proceeds further the arrangement of the oil-globules ceases to be so definite as it is in the figure; they not merely occupy the place of the cells but also accumulate between the fibres of the intercellular ground-substance. In still more advanced cases subendothelial cavities are formed by softening. At this stage leucocytes generally appear, which have migrated from the

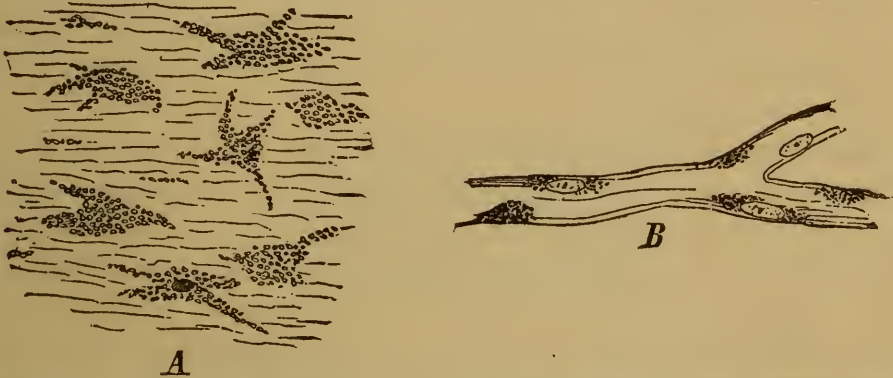


FIG. 127. *A*, CELLS FROM THE INTIMA OF THE AORTA SHOWING FATTY DEGENERATION.

(Seen on the flat.)

B, FATTY CAPILLARY FROM THE BRAIN.

(Perosmic acid preparation: $\times 300$.)

vasa vasorum, and take up the fatty products of disintegration into their substance; it is in this way that fat-granule carrying cells arise.

The favorite seats of fatty change in the aorta are immediately above the valves, and at the places where the large and small arteries are given off. The change is most common in anæmic and in aged patients. In the pulmonary artery it seems most favored by causes producing stagnation in the pulmonary circulation, in consequence of which the carbonic acid of the blood is imperfectly removed from it. Spots of fatty degeneration occur in like manner in the lining membrane of the veins when the circulation through them is chronically impeded.

Fatty degeneration is common in the capillaries (Fig. 127 *B*), partly as the result of simple disorders of circulation, partly of changes in the blood itself such as are met with in infective diseases and in certain forms of poisoning (phosphorus or arsenic).

The tunica media may be affected as well as the intima, the fatty change specially attacking the muscle-cells, which in consequence often perish outright. The general course of the process is the same as in the

case of the intima; but its effect on the functions of the vessels is more serious. Thus degeneration of the middle coat may lead to rupture of the vessel; while calcification follows readily upon fatty change, and the vessel may thus lose its elasticity and contractility, and remain a mere rigid pipe.

The cells of the adventitia are found to become fatty in connection with like change either in the interior coats, or in the parenchyma of the surrounding organ; the change has no special significance. Not infrequently the fat found in the meshes of the adventitia is not produced there, but is merely deposited from the lymphatics.

See on this subject VIRCHOW (*Virch. Arch.* vols. 1 and 3, and *Gesamm. Abhand.* (1856) p. 493); LANGHANS (*Virch. Arch.* vol. 36).

288. **Amyloid degeneration** of the vessels is very frequently met with. As was pointed out in Art. 52 the vascular system is in a special way singled out as the seat of amyloid deposit. In the larger vessels the intima is most apt to be affected; in the smaller vessels the media, and to some extent the adventitia.

Hyaline degeneration (Art. 63) is the term used to describe certain morbid appearances in the vessel-wall, which have certainly not always the same significance. In the first place the term is applied to a peculiar transformation of the intima of the larger vessels, by which it is changed into a homogeneous connective tissue with few nuclei; in this atheroma often takes its rise (Art. 299). A second form of homogeneous change bearing the same name affects chiefly the smallest arterioles and capillaries; it is oftenest observed in the renal glomeruli, in the choroid, and in the brain. In the case of the capillaries the change is preceded by proliferation of the nuclei of the cells (OELLER); then homogeneous or hyaline deposits are formed on the exterior of the capillary tube, which are at first scattered but presently aggregate into masses encircling the tube. Thrombi are occasionally formed in the altered capillaries, and after a time they too assume a homogeneous appearance.

In the arterioles the change may extend to all the coats of the vessel, or be limited to one only; the change may here as in the capillaries be preceded by proliferation of nuclei; and thrombosis may likewise be set up.

The genesis of the hyaline deposit is not always easily determined. Some authorities hold that it depends mainly on the coagulation of extravasated red and white blood-cells. In other cases it is due to a homogeneous metaplasia of the connective tissue.

Calcification of the vessels occurs chiefly in cases where the nutrition of the vessel-wall is impaired, and where the tissue has already undergone some antecedent degenerative change. Thus calcification in the arteries is a very common sequel of fatty change; and also of sclerosis or atheroma (Arts. 297 and 298). The calcareous matter is deposited

in the intima or media. In the former it is mainly the sclerosed or atheromatous patches themselves which become calcified; so that definite and coherent calcareous plates are formed, which may be removed entire. In the case of the media the process may go so far as to convert the whole vessel into a hard and rigid tube; this occurs most commonly in the larger and middle-sized arteries of the trunk and limbs. The inner surface of such arteries has often a ribbed or corrugated appearance, fine white circular ridges running round the wall. If the intima be peeled off (and it is usually very loosely attached), it is seen that the ridges spring from the middle coat. The intima itself is sure to be more or less atheromatous.

The calcareous salts are deposited in small shining grains lying in the muscle-cells or in the intercellular tissue. In the middle coat of the aorta (Fig. 128) they lie irregularly in the spaces separating the elastic lamellæ.

Calcification of the capillaries is chiefly met with in tumors of the central nervous system.

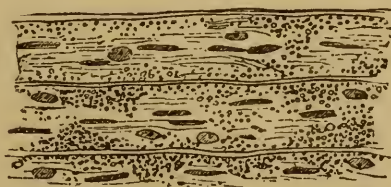


FIG. 128. CALCIFICATION OF THE TUNICA MEDIA OF THE AORTA.
(The deposit lies between the elastic lamellæ : $\times 250$.)

The veins may also be the seat of calcareous deposits, but much less frequently than the arteries. The deposits chiefly occur in dilated and varicose veins, and then generally in the inner strata of the middle coat.

Necrosis of the vessel-wall is generally a result of an inflammation set up in the surrounding tissue and resulting in general necrosis and disintegration. Diphtheria and caseous tuberculosis are of this kind; and the vessels undergo changes analogous to the changes in the other tissues affected. But besides this acute necrosis there is a more gradual 'necrobiosis' of the vessel-wall in which the tissue first becomes homogeneous and then breaks up; it mainly affects the intima (Arts. 297-299).

On hyaline degeneration of the vessels see Art. 63; THOMA (*Virch. Arch.* vol. 71); ZIEGLER (*Arch. f. klin. Med.* XXV.); LEYDEN (*Zeitschr. f. klin. Med.* II.); WEIGERT (*Virch. Arch.* vol. 79); JUNGE (*Arch. f. Ophthalm.* v.); SCHWEIGGER (*ibid.* VI.); OELLER (*Virch. Arch.* vol. 86); MEYER (*Arch. de physiol.* VII.).

CHAPTER XIII.

HYPERTROPHY AND HYPERPLASIA OF THE VESSELS.

289. True **hypertrophy of the arteries**, that is to say increase in all the coats of the walls without loss of structure, is seen in a marked form in the vessels which carry on collateral circulation after the occlusion of a larger artery. The increase is most remarkable when it depends on the occlusion of one of the large arterial trunks. The collateral vessels increase in length as well as in width and thus become convoluted, while the increase in the thickness of the wall is even greater in proportion. Local hypertrophy may likewise follow upon increase of blood-pressure, such as occurs in front of a contracted portion of the vessel. If the pressure of the blood be generally increased throughout the system, as it is in chronic Bright's disease, the smaller arteries may become universally hypertrophied.

The so-called anastomotic or racemose aneurysm (Art. 151) is mainly due to dilatation, convolution, and hypertrophy of arteries and capillaries. And in hypertrophy of the organs, as in ordinary development or in new-formations, the arteries tend to become more or less hypertrophied.

Veins and capillaries may hypertrophy like arteries, especially under the conditions just mentioned, which are associated with increased blood-supply.

Hypertrophy implies increase in the elements of the vessel-walls, but not in the number of the vessels; the latter is **hyperplasia**, and is an extremely common occurrence. In the General Pathological Anatomy we pointed out that the development of new-formations of any size involved of necessity the formation of new vessels; and in Art. 86 we described the mode in which this takes place. At first capillaries only appear; but by the multiplication of the elements of the walls and their progressive differentiation arteries and veins are ultimately elaborated.

CHAPTER XIV.

INFLAMMATIONS OF THE VESSELS.

290. We have already had occasion to allude to two varieties of inflammatory change affecting the walls of the vessels. From one point of view, we have spoken of an alteration in the vessel-wall as an essential factor in all inflammatory processes, this alteration being the condition antecedent to the quantitative and qualitative changes in the current of transudation from the smaller vessels into the tissues. The increased permeability of the vessel-wall permits the escape from the capillaries and veins, not only of liquid, but of large numbers of white and occasionally red blood-cells (Art. 96). The second form of inflammatory change dealt with was that concerned in the organization of thrombi (Art. 255). Here the vessel-wall became inflamed in consequence of the irritating presence of a foreign body, the thrombus itself; and the inflammation resulted in the development of granulation-tissue and a cicatrix within the vein or artery. In view of the ultimate result of the inflammation, we might describe it as a plastic obliterating endarteritis or endophlebitis.

But in addition to these two kinds of inflammatory vascular change we have a series of others which have their seat in the substance of the vessel-wall and lead to temporary or permanent changes extending to a part or the whole of its thickness. **Arteritis** and **phlebitis** are used to describe these parenchymatous inflammations of the vessel-wall. They may arise as primarily vascular affections and be confined to the proper tissues of the vessels; or the surrounding tissues may be likewise involved; or the vascular affection may be secondary to an existing inflammation of the surrounding tissues. The latter occurs in the case of minute vessels embedded in the tissues, and is to be clearly made out only by the aid of the microscope.

291. **Purulent arteritis**, issuing in suppuration and destruction of the wall of the artery, is generally a secondary process occurring within suppurating wounds and ulcers. Inflammation and necrosis extend by continuity from the surrounding tissues to the vessel, destroying first the adventitia and then the other coats. The wall appears thickened and yellowish or grayish in color; the intima is turbid, yellowish or grayish, and infiltrated with pus. Often the brittle or rotten vessel gives way, and hæmorrhage follows. Secondary hæmorrhage in wounds, hæmopti-

sis from phthisical lungs, hæmorrhage from cancerous ulcerations, etc., are all of this nature; and in the same way fatal bleeding may occur from suppurative inflammation of the umbilical cord in infants. At times, as in tuberculosis, the necrotic process takes on a caseous character. Suppuration in wounds is chiefly conditioned by the invasion of micrococci.

Sometimes purulent arteritis with necrosis is due to the entrance of irritant matters into the blood, as happens in embolism where the emboli are virulent or infective (Art. 116). When the destructive process spreads from the vessel to the neighboring tissue, abscesses are formed.

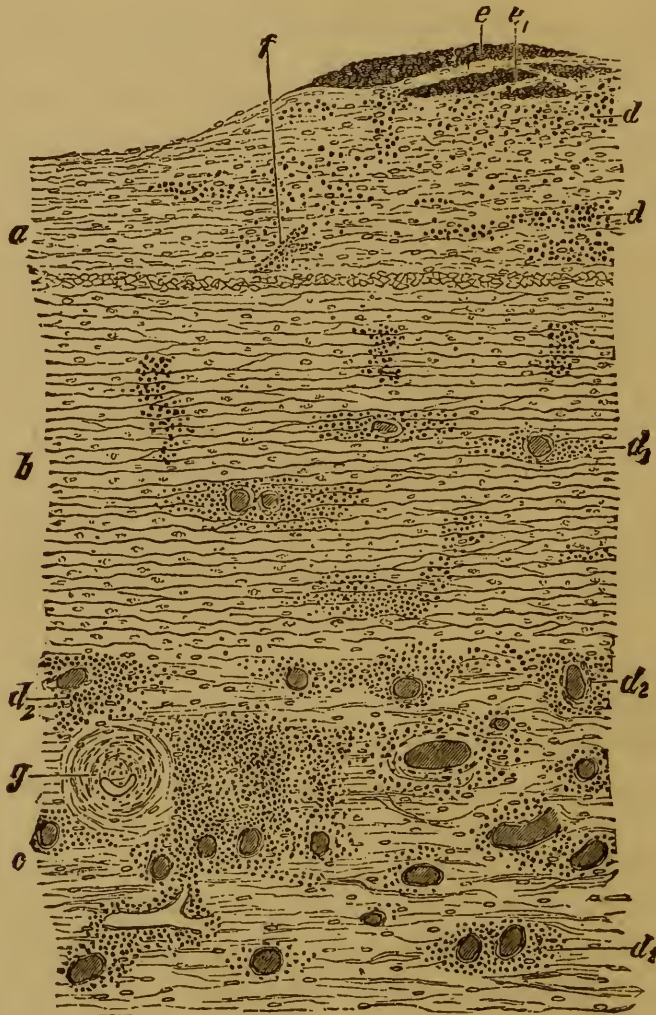

FIG. 118.—SECTION OF THE AORTA IN ACUTE AORTITIS.

(Carminé staining : $\times 45$.)

a, intima thickened by previous inflammation.
 b, media with infiltrated leucocytes d_1 .
 c, adventitia with infiltrated leucocytes d_2 .
 d, infiltrated leucocytes.

e, granular fibrin lying on the intima.
 e_1 , the same within the intima.
 f, blood-vessel within the hyperplastic intima.
 g, small artery contracted by sclerosis of its walls.

The pus-corpuscles which in these processes accumulate in the substance of the vessel-wall are in part derived from the vasa vasorum, in part from the surrounding vessels.

Purulent phlebitis occurs under the same conditions as purulent arteritis. The walls of the veins are thickened and discolored, and the intima is turbid. The lumen very frequently contains fresh or softened and puriform thrombi. The purulent inflammation of the vessel may be preceded or followed by coagulation of its contents. The relation of the two processes is often as follows: incipient inflammatory change in the vessel-wall gives the condition for thrombosis; a thrombus forms and is invaded by micrococci; it then breaks down into a puriform irritant mass, which in its turn intensifies the inflammatory change in the vessel-wall to the pitch of suppuration and necrosis. Examples of the process (known as **thrombophlebitis**) are frequently met with, as in the radicles of the portal vein, near ulcerated patches in the intestine, such as occur in dysentery and in the veins of suppurating wounds. If the softened and infected thrombi pass into the general circulation, we have pyæmia and metastatic abscesses as the result.

292. **Hyperplastic arteritis**, in its early stages, is best studied in cases of what is called **acute aortitis**, an affection which however is rarely seen exemplified in the post-mortem room. It is rapidly fatal only when it is very extensive; minor cases usually recover.

The changes it produces are exactly similar to those described under endocarditis and myocarditis.

The inner lining of the affected vessel looks turbid and somewhat loosened, or gray translucent granulations rise from its surface, or larger irregular vegetations resembling closely those seen in the endocardium. Thin films of fibrin often lie over the inflamed patches.

The middle coat and the adventitia, but especially the latter, show patches of gray or grayish-red; but it rarely happens that their extent is large enough to allow them to be readily recognized by the eye alone.

When the more seriously affected parts are examined microscopically, it is seen that all the coats of the artery are attacked; the characters of the change being the extreme distention or congestion of the vasa vasorum, and the presence of cellular, coagulated, and granular masses of exudation (Fig. 129 d d_1 d_2 e e_1). Sometimes the adventitia (c) shows the most striking changes; being greatly thickened in consequence of abundant cellular infiltration and of nodular clusters of cells (d_2) surrounding the vasa vasorum. The infiltrations in the media are also clustered around the vasa vasorum (d_1), and often reach considerable size.

The intima contains accumulations of leucocytes (d) in the meshes of its connective tissue, in addition to granular fibrinous coagula (e e_1) which lie either within (e_1) the distended meshes or on the surface (e).

The cellular infiltration in aortitis is derived from the vasa vasorum, as is evidenced by the clustering of the cells around these vessels. Where the cells are more remote from the vessels, as in some parts of the intima, we conclude that they have migrated.

References :—KÖSTER, *Sitzungsber. d. niederrhein. Gesell. f. Natur u. Heilk. in Bonn* 1877 ; KÖSTER, *Die Pathogenese d. Endarteritis* 1871 ; JACCOUD, *Path. interne* t. 1873 ; STROGANOW, *Recherches sur l'origine des éléments cellulaires dans l'endartérite de l'aorte*, *Arch. de physiol. norm. et path.* 1876 ; WINIWARTER, *Arch. f. klin. Chir.* XXIII. ; LÉGER, *Étude sur l'aortite aiguë* 1878 ; JAHN, *Virch. Arch.* vol. 72 ; TROMPETER, *Ueb. Endarteritis* In. Diss. Bonn 1876 ; TALMA, *Virch. Arch.* vol. 77 ; GIOVANNI, *Arch. ital. d. biol.* I. ; CORNIL and RANVIER ; *Man. of Path. Hist.* I., 1882, *Arch. de physiol.* 1868 ; POULIN, *Gaz. hebdom.* 1879 ; ISRAEL, *Virch. Arch.* vol. 86 ; ORTH, *Lehrb. d. spec. path. Anat.* I., 1883.

293. If the patient does not die during the early stages of the disease, the process of repair begins and new fibrous tissue and capillaries are developed at the affected spots. When the exudation has been slight it may be entirely re-absorbed ; but if the inflammation is kept up fibroblasts are developed, and from them new fibrous tissue. Whether the fixed tissue-cells or the white blood-cells take the chief share in building up the new-formed tissue is hard to determine.

Three forms of arterial inflammation are distinguished according to the coats chiefly affected, namely endarteritis, mesarteritis, and periarteritis ; but the forms very frequently occur in combination.

If **endarteritis** becomes chronic, and new fibrous tissue is formed in the intima, broad slightly raised *plaques* are produced, which often appear in large numbers and of great size in the larger arterial trunks, and especially in the aorta. As Fig. 129 (a) shows, they consist of dense fibrous tissue resembling scar-tissue ; the normal structure of the intima is usually lost. New vessels are nearly always formed (Fig. 129 f). In other cases the new tissue is looser, more resembling areolar or mucoid tissue. Such hyperplasias of the intima are called **scleroses** (Arts. 297–298) ; they occur both in large and in small vessels, and in the latter may produce considerable contraction of their calibre. The process has therefore been also described as **obliterating endarteritis**. Once it has begun it is apt to recur, increasing the size of the old patches and starting new ones ; it is thus progressive in its character.

Mesarteritis is generally an accompaniment of endarteritis. Fibrous deposits appear in the middle coat, while the normal elements and especially the muscular fibres perish by degrees. The changes in the middle coat seldom reach the same pitch as those in the intima ; but here and there the normal tissue may be entirely displaced by new scar-tissue.

Periarteritis leads to fibrous thickening and condensation of the adventitia. In vessels which lie freely in the tissues the thickenings are diffuse or aggregated into coarse bands or nodes. The latter variety has been described by KUSSMAUL and MAIER as *periarteritis nodosa*.

Hyperplastic phlebitis corresponds to hyperplastic arteritis, and like it is an inflammation leading to fibrous hyperplasia. The forms endophlebitis, mesophlebitis, and periphlebitis are distinguishable. It is rarer than arteritis as a simple or primarily vascular disorder. The thickenings formed in the intima of the veins are by no means so remark-

able as those of the arteries. Fibrous hyperplasia of the walls of the veins most frequently results from venous thrombosis, or from chronic parenchymatous inflammations of the surrounding tissues which have spread to the veins.

KUSSMAUL and MAIER (*Deutsch. Arch. f. klin. Med.* 1.) met with a case in which the arteries of the most diverse organs were beset with nodes and nodules from the size of a pea to that of a millet-seed. The nodules were partly cellular and partly fibrous; they were seated chiefly in the adventitia, but some of them were in the media. MEYER describes a like case (*Virch. Arch.* vol. 74).

294. The **ætiology of the hyperplastic inflammations** of the vessel-wall is not always the same. It is to be remembered that the inflammatory processes which lead to fibrous hyperplasia in any organ may all of them affect the included vessels, and may thus lead to thickening of the vessel-walls. Often the adventitia is the coat most affected, but the other coats do not by any means always escape. These forms of arteritis and phlebitis are obviously due to the same causes as those which lead to the corresponding organic affections.

Even the inflammations which are limited to the vessels themselves are not always due to the same kind of irritant or injury. The case resembles that of endocarditis, an affection which as we have seen may spring from more than one source. In the first place, the irritants or injuries which produce endocarditis may also produce endarteritis; the evidence of this being that in many cases both affections occur simultaneously. But it would seem that there are more varieties of injury capable of producing arteritis than of producing endocarditis; or at least that vascular inflammations occur under conditions where it is unusual to find endocarditis. Of the causes which may set up chronic vascular inflammations the chief are syphilis and tuberculosis.

295. **Syphilitic arteritis** was first closely studied by HEUBNER, who showed that it is of frequent occurrence. It is found in two chief forms, that is to say either as an independent disorder, or as part of a local syphilitic affection. In the former the affected vessel shows white or grayish thickening of the intima and of the adventitia. The vessel, such as a cerebral artery, may thus be beset with circumscribed grayish translucent patches, or be transformed into a coarse white or grayish cord. This form is not to be distinguished, either with the eye or the microscope, from arterial thickening due to non-syphilitic fibrous hyperplasia. The second form of syphilitic arteritis occurs in the midst of foci of syphilitic disease affecting the tissues generally; the vessels are surrounded either with diffuse cellular infiltrations (the so-called gummatous granulations), or with dense cicatricial tissue (Arts. 128-130). In such cases the coats of the vessel are more or less altered and thickened (Fig. 130).

The intima (*a*) and the adventitia (*d*) are usually more thickened than the media (*c*). While the process is still recent, not having yet passed the stage of granulation, the thickening of the intima is partly

due to an abundant development of fibrocellular tissue (*e*). The cells are in part small and round, in part fusiform or stellate (*f*) corresponding to certain forms of fibroblasts. The adventitia is similarly altered. The media is usually but little beset with migratory cells.

In more advanced cases where fibroid change has succeeded active inflammation, the thickened coats of the vessels are more fibrous and less rich in cells. The middle coat is either little altered, or here and there atrophied and fibrous. There is nothing specific in the histological character of the process; all we can say is that in the ordinary non-syphilitic inflammations of small arteries it is unusual to have so abundant an infiltration of cells as in syphilitic inflammations, and that the adventitia especially is not so subject to marked alteration.

The thickening of the vessel-wall in syphilis is often very considerable; it may indeed become so extreme that the lumen of the affected artery may be almost or entirely occluded.

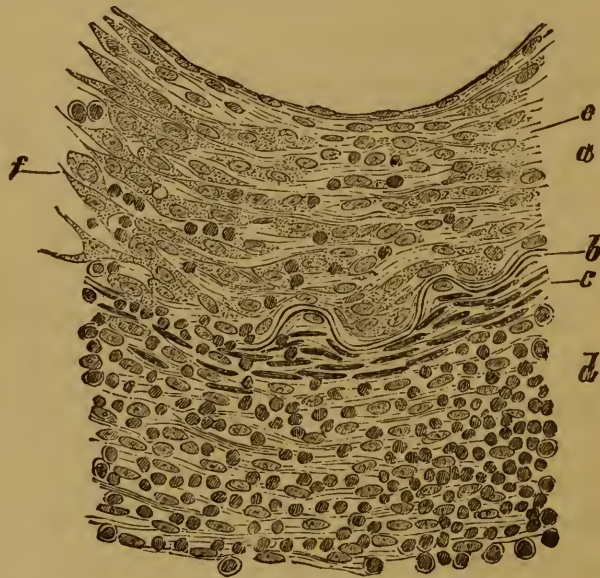


FIG. 130. SYPHILITIC ARTERITIS.

(Carmin staining: $\times 150$.)

a, greatly thickened intima, the thickening due to fibrocellular tissue (*e*) and new-formed cells (*f*).

b, fenestrated elastic membrane, broken through on the left side.

c, muscle-fibres of the media, beset on the left with large and small leucocytes.

d, adventitia thickened by fibrous hyperplasia and cell-infiltration.

e, fibro-cellular tissue of the intima.

f, new-formed cellular tissue with infiltrated leucocytes.

The walls of the veins are likewise subject to gummatous syphilitic inflammations.

The diagnosis of syphilitic arteritis rests in general more on the naked-eye appearances than on the minute histological characters. The specific nature of the affection will be determined mainly by the presence of other localized syphilitic affections, especially of a gummatous kind. If these last are not found, we must not pronounce the disease to be syphilitic unless we can find sure signs of it elsewhere, or unless we have excluded all other possible causes for the vascular

changes. There are no certain histological criteria for deciding on the presence of syphilis (HEUBNER, *Die luetische Erkrankung der Gehirnarterien* Leipzig 1874; *Ziemssen's Cyclop.* XII.). Even the abundance of cells found in the adventitia is not pathognomonic, for in the cerebral vessels especially tuberculosis may give rise to exactly similar appearances. See BRISTOWE (*Trans. Path. Soc.* 1859); HUGHLINGS JACKSON (*London Hosp. Reports* 1868); BAUMGARTEN (*Virch. Arch.* vol. 73, 76, 86, the last contains a number of references); VON LANGENBECK (*Arch. f. klin. Chir.* XXVI.); FRIEDLÄNDER (*Cent. f. d. med. Wiss.* 1876); EHRLICH (*Zeitschr. f. klin. Med.* I.); HUBER (*Virch. Arch.* vol. 79); BIRCH-HIRSCHFELD (*Arch. d. Heilk.* XVI.); LANCEREAUX (*Gaz. d. Hôp.* 21, 1876); GREENFIELD, GOWERS, and others (*Trans. Path. Soc.* 1877-78).

296. **Tuberculous inflammation of the vessel-walls** is very common, inasmuch as arteries and veins running through tuberculous organs are readily invaded by the disease. Tubercles and more diffuse tuberculous patches may appear in their walls; and if the granulomatous focus becomes caseous, the vessels undergo the same transformation. If the diseased vessel be an artery it often ruptures and gives rise to hæmorrhage; if it be a vein the disintegration of the wall may admit products of disintegration and bacilli into the blood-current. The result is an eruption of tubercles at the spot whither the bacilli are carried by the blood.

Fibrous hyperplasia may also be set up as a consequence of tuberculous inflammation. Most commonly it is the adventitia which becomes thickened, though at times a like thickening is met with in the intima. It may become so considerable that the vessel is almost or quite occluded. The same result may follow when thrombosis is set up in a vessel whose wall is beset with tuberculous granulations.

References:—RINDFLEISCH, *Ziemssen's Cyclop.* v.; MARTIN, *Recherches anat.-path.* Paris 1879; CORNIL, *Journ. de l'anat.* XVI.; KIENER, *Arch. de physiol.* VII.; MÜGGE, *Virch. Arch.* vol. 76; ARNOLD, *ibid.* vol. 88; WEIGERT, *ibid.* vols. 77, 88.

CHAPTER XV.

SCLEROSIS AND ATHEROMA.

297. **Sclerosis** in an artery implies the existence of local thickenings of its inner coat. They appear as slight broadened prominences, rising above the level of the normal intima as definite flat or convex *plaques* or patches. The margins may be steep or sloping, the surface is smooth. The patches may be translucent or almost gelatinous, or cartilaginous, or white and densely fibrous.

These patches appear in arteries of all sizes—from the aorta just above its valves to the smallest arteriole. They are often few in number; but in other cases they are extraordinarily numerous, cases occurring in which the intima of the aorta is so beset that there scarcely remains a healthy spot on its surface.

If the sclerosis is at all marked there are always found, in addition to the grayish or cartilaginous patches, other *plaques* of an opaque white or yellowish-white color. These may be smooth or rough; and not infrequently the tissue has disintegrated and fallen away from them, leaving so-called ulcers with white detritus lying on their floors; or the rough and ulcerated spots may be covered with thrombi. The white or yellowish *plaques* are known as **atheromatous patches**, and the eroded spots as **atheromatous ulcers**, the process as a whole being described as atheroma of the arteries. It is thus a sequel of sclerosis.

Very often a third change is associated with these, namely the **calcification** of the affected spots. When this occurs the white atheromatous patches become hard and rigid to the feel, giving one the impression of a plate of bone lying beneath the superficial layer.

In the veins these changes are much less common, and in general much less marked; but they do sometimes occur. Calcification is oftener met with than simple atheroma.

References:—WILKS and MOXON, *Path. anat.* London 1875; MEYER, *Arch. d. physiol.* VII.; NEUMANN, *Arch. f. mikrosk. Anat.* XVIII.

298. Sections show well the seat and characters of sclerotic and atheromatous change (Fig. 131). The intima (*a*) is generally the most affected, while the media (*c*) is often unaltered, and the adventitia (*h*) only slightly infiltrated. In other cases the adventitia may be somewhat thickened and the media atrophied. The change in the intima consists of more or less extensive but generally unilateral thickening. At the

oints where the altered passes into the unaltered tissue the thickening is made up of fibrous tissue (*g*) more or less notably infiltrated with leucocytes. The same is true of the innermost layers of the altered intima; but the deeper layers in contact with the elastic bounding membrane consist of pale indistinctly fibrillated tissue (*e*), which is devoid of nuclei and almost entirely necrosed; they contain numerous aggregations of granular detritus (*f*). The granular masses consist partly of albumen, partly of fat, and older foci of softening nearly always contain tablets of cholesterin (*f*₁). Atheroma thus appears to be essentially a necrosis with granular and fatty disintegration of the thickened intima.

The atheromatous ulcer is produced by the advance of the disintegrating process towards the lumen of the vessel, and rupture of the innermost layers of the intima. We may conceive how readily such a

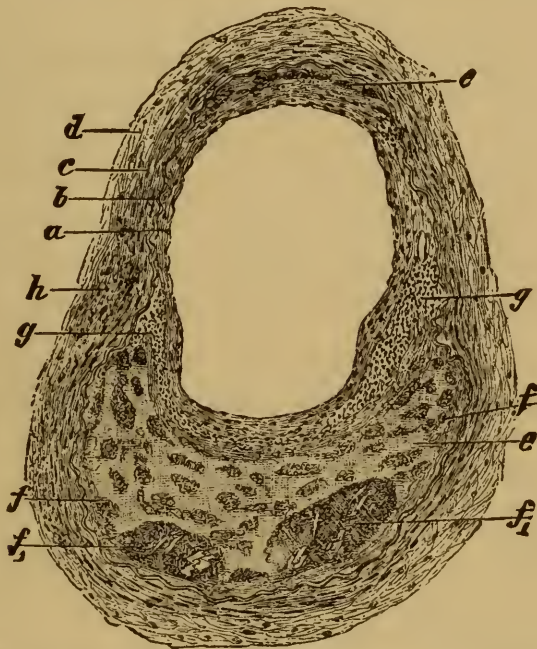


FIG. 131. ATHEROMATOUS CEREBRAL ARTERY (× 50).

a, intima considerably thickened.
b, bounding elastic lamella of intima.
c, media.
d, adventitia.
e, necrosed denucleated tissue with masses
of fatty detritus *f* and

*f*₁, detritus with cholesterin-tablets.
g, infiltrated leucocytes in the intima.
h, infiltrated leucocytes in the adventitia.

rupture might occur, if we note that on the post-mortem table very slight pressure on an atheromatous patch often suffices to break in the surface layer and convert the patch into a cavity.

299. As regards the **genesis of sclerosis and atheroma** we must remember (Art. 292–293) that thickening of the intima may be the result of a process beginning with inflammatory infiltration, and leading to the formation of new fibrous tissue. We may therefore say that sclerosis and atheroma of the arteries are in many cases the result of a chronic endarteritis, which began as an acute affection.

But this is not always so; or at least we have not always evidence enough to justify the hypothesis. Especially is this the case with the gradually developed forms found in advanced age. The affection is either limited to the aorta or to the arteries of one or other organ, or it is more or less diffused over the entire arterial system. This **senile atheroma** does not begin in inflammation, but either in degeneration or metaplasia.

VIRCHOW has shown that in many instances the first step is a kind of gelatinous degeneration of the intima, leading to swelling and loosening of its texture. Then ensues proliferation of the tissue-elements of the intima, which may produce new fibrous tissue and bring about a thickening of the inner coat. But in extreme old age it is commoner to find the intima undergoing a kind of homogeneous or hyaline change, which is associated with a permanent thickening of its substance. Here and there the thickening may become considerable (Art. 288), and lead to the formation of raised *plaques* and patches. Retrogressive changes follow close on these metaplastic processes, and inflammation at length appears. The retrogressive changes are fatty degeneration, necrosis, and disintegration of the altered tissue. As we have already said, such retrogressive changes may themselves be the starting-point of the affection. When once the process of degeneration, proliferation, and inflammation is started, it generally spreads more and more widely.

We are not as yet able to define more closely the precise limits of the processes leading to atheroma, namely primary inflammation, primary metaplasia, and primary degeneration. In many cases we can only form hypotheses as to the mode in which atheroma has arisen.

The process leading to sclerosis and atheroma in the aged is often alluded to as **arteritis deformans**, or *malum senile arteriarum*. It has been compared with the affections known as arthritis deformans and *malum senile coxæ* (VIRCHOW, *Virch Arch.* vol. 4, and *Gesamm. Abhandl.* (1856) p. 496); and the processes have indeed much that is apparently analogous.

LANGHANS (*Virch. Arch.* vol. 36) and KÖSTER (*Virch. Jahresb.* 1875) assert that a certain amount of thickening of the intima is so common in old age, that it may be regarded as physiological. GIOVANNI (*Arch. ital. de biol.* 1.) maintains that disorders of the innervation of the vessels may lead to atheroma; compare LEWASCHEW (*Virch. Arch.* vol. 92). ISRAEL (*Virch. Arch.* vol. 86) observed endarteritis in rabbits, in which he had experimentally caused one kidney to become contracted.

300. Sclerosis and atheroma often give rise to serious **disturbance of the circulation** and with it of the nutrition of the parts supplied by the affected vessels. Apart from the resistances to the blood introduced by the deformation of the inner surfaces of the blood-channels and the loss of elasticity of their walls, there is occasionally a considerable narrowing of the calibre (Fig. 131), and this may become so great that the artery is at length completely occluded (as in obliterating endarteritis). As the various prominences encroaching upon the lumen meet and coa-

lesce the vessel may ultimately be transformed into a solid cord. If collateral circulation is not speedily set up, the blood-supply of the part is cut off, and anæmic necrosis ensues. This is a very common occurrence in the brain. It may take place not only in small arteries but even in the largest trunks, especially at the points where branches are given off. Thus, for example, the subclavians and carotids may be occluded by thickening of the intima at their points of origin from the aorta.

A second result is thrombosis. It is produced by the change in the vessel-wall on one hand, and by the slowing of the blood-stream on the other. Minor vessels which are already narrowed may be completely blocked up by intercurrent thrombosis. In the aorta parietal thrombi are common. If they are loosened and swept off they cause embolism; and the same result follows when particles are carried away from atheromatous ulcers. Atheroma of the arteries may likewise lead to morbid dilatation (Art. 301) of the vessel, or even to rupture. Both results are due to the textural changes, and the diminished power of resisting the blood-pressure which the changes involve.

CHAPTER XVI.

CHANGES IN THE CALIBRE OF THE VESSELS.

301. A **true aneurysm** is a localized dilatation of an artery involving all three of its coats. When the dilatation has persisted for a time one or other of the coats may atrophy; the media being the first to disappear, while the intima often follows. In this way the wall of the aneurysm may ultimately in places consist of the adventitia alone.

When the dilatation extends over a considerable section of the artery, when for instance the entire thoracic aorta is uniformly dilated while retaining its cylindrical form, we have a **diffuse** or cylindrical aneurysm; a spindle-shaped dilatation constitutes a **fusiform** aneurysm; a localized unilateral bulging is a **sacculated** aneurysm; while an artery with some of its branches which is dilated and convoluted, and it may be in parts sacculated, is described as a **cirroid** aneurysm (or less aptly an aneurysmal varix, which term has properly another signification, Art. 311).

The forms just mentioned may of course be combined in various ways, so that intermediate and transitional varieties are common. In the case of sacculated aneurysms the diameter of the opening into the sac is often less than that of the sac itself.

The **racemose or anastomotic** aneurysm (otherwise described as an arterial vascular tumor) is a distinct variety. Here, as has been mentioned in Arts. 151 and 289, we have to do with a general dilatation of a multitude of arterial twigs and capillaries accompanied by hypertrophy of their walls.

Abnormal width of the arteries generally, apart from localized or aneurysmal change, may occur as a congenital or at least developmental anomaly.

302. The **development of an aneurysm** is in general to be referred to some pre-existent disease of the arterial coats. Sacculations are especially apt to occur when the intima and media are simultaneously affected by active disease or degeneration. Sclerosis and atheroma are the commonest causes, especially when the media also undergoes degeneration. In other cases affections of the adventitia may lead to aneurysm, when they are such as extend also to the media and set up inflammation or muscular degeneration there. All these affections diminish the elasticity and strength of the arterial wall, so that it stretches and gives way before the pressure of the blood. In accordance with the common mode

of genesis, we find the intima in most aneurysms highly atheromatous; the muscular elements of the middle coat are fatty and disintegrated or lost altogether; and the elastic fibres show signs of granular change. The media or intima or both may here and there be wanting entirely; while the adventitia is usually thickened and infiltrated with inflammatory exudations.

A form of aneurysm whose genesis is different has been described by PONFICK (*Virch. Arch.* vol. 58) under the title of the **embolic** aneurism. Fragments of calcified endocarditic vegetations lodge as embolisms in the wall of an artery, it may be in the brain for example; there they bore or work their way into the tissue of the wall, until at length it gives way and a sacculation is formed. Another special form is the so-called **hernial** aneurism, produced by the hernial protrusion of the inner coats through a weak or eroded place in the outer coat or sheath.

CHARCOT (*Senile and chronic diseases* (New Syd. Soc.) 1881) thinks that aneurysms start in degeneration not of the intima but of the adventitia, the inflammatory thickening of which induces atrophy of the muscular coat. ZIEGLER'S observations lead him to believe that this mode of development (from periarteritis followed by muscular atrophy in the media) does occur; but in the arteries of the brain, on which CHARCOT specially bases his conclusions, the process generally starts with the intima. The accumulations of infiltrated cells seen in the adventitia in such cases are secondary (VIRCHOW, *Virch. Arch.* vol. 3; CHARCOT and BOUCHARD, *Arch. de physiol.* 1868; LIOUVILLE, *Anévrismes miliaires* Thèse de Paris, 1871; ROTH, *Corresp. f. schweiz. Aerzte*, 1874; KRAFFT, *Die Entstehung der wahren Aneurysmen* In. Diss. Berne 1877).

For references to aneurysm depending on embolism see CHURCH (*St. Barth. Hosp. Reports* 1870), GOODHART and others (*Trans. Path. Soc.* 1877).

303. Seats of aneurysm. Aneurysms most commonly occur in the thoracic aorta; they may be diffuse, fusiform, or sacculated. Their favorite seat is the ascending and transverse parts of the arch. They often reach an astonishing size, and press against the sternum and costal cartilages, or against the lungs and the spinal column, according to their position. Soft or yielding parts are pushed aside or compressed, rigid parts like the bones of the sternum or spine are eroded or absorbed. The costal cartilages and intervertebral discs resist the pressure better, so that while the vertebral bodies are often deeply excavated the discs persist almost unchanged. The tissue immediately surrounding an aneurysm is in some parts infiltrated with inflammatory products, in others thickened and fibroid. It is the inflammation set up around the aneurysm which leads to the absorption of the bone it presses upon.

The abdominal aorta is likewise a common seat of aneurysms, which may reach a very considerable size.

The popliteal artery is the vessel most subject to aneurysm after the aorta; and then follow the other trunks, namely the carotid, subclavian, innominate, axillary, iliac, splenic, hepatic, renal, hypogastric, etc. The sacs formed in these arteries are very seldom of anything approaching the

size of aortic aneurysms. True cirroid aneurysms affect chiefly the common iliac and its branches, anastomotic aneurysms chiefly the vessels of the head. Somewhat indefinite dilatations are occasionally met with in the trunk of the pulmonary artery, but they are scarcely to be described as aneurysmal; in rare cases the valvular sinuses are more or less abnormally bulged. Large aneurysms of the pulmonary artery are very rare.

Aneurysms of the smaller arteries of the brain are of considerable importance. Aneurysmal sacculations of the arteries of the base may reach the size of a pea or of a bean. In the smaller arteries they are naturally smaller, and often cannot be made out with a lens (**miliary aneurysms** of CHARCOT). General or diffuse dilatation is met with chiefly in the basilar artery.

The small aneurysms met with in the twigs of the pulmonary artery in phthisis have a special interest. They are formed in consequence of inflammatory destruction of the vessel-wall starting in the adventitia, and belong in part to the class of hernial aneurysms.

304. **Consequences of aneurysm.** An artery which has once become aneurysmally dilated never returns to its normal state; the dilatation rather tends steadily to increase. The walls at the same time become thinner, inasmuch as the inflammation set up is unable to furnish any efficient substitute for the loss of healthy tissue. The consequence is that the sac ultimately gives way at some point or other, and, especially in the case of aortic aneurysms, **fatal hæmorrhage** ensues. Dangerous hæmorrhage may follow the rupture of arteries that are by no means large, notably those of the brain; fatal cerebral hæmorrhage or **apoplexy** is a very common occurrence. So too the rupture of minute aneurysms in the lungs often leads to fatal **hæmoptysis** in phthisis.

It is only in comparatively small arteries that the aneurysm is completely obliterated by the filling up of the sac with cicatricial tissue; probably the formation of such tissue is always preceded by the deposit of thrombi in the sac. The thrombi are then replaced by fibrous tissue in the manner described in Arts. 255 and 256. In large aneurysms we frequently find massive firm laminated decolorized or mottled **thrombi** more or less completely occupying the cavity. At various points we may find evidence of partial proliferation of the elements of the inner coat in contact with the thrombi, leading to the development of fibrous tissue; but the thrombi never undergo complete organization.

These somewhat incoherent thrombi form but an imperfect defence against the danger of rupture, as the blood may work its way between the thrombus and the vessel-wall; while the thrombi themselves may undergo softening, disintegration, or even liquefaction: occasionally calcareous salts are deposited and they become calcified.

CHARCOT asserts (*Senile and chronic diseases* 1881) that cerebral hæmorrhage always depends on the rupture of an aneurysm more or less minute. EICHLER

(*Deutsch. Arch. f. klin. Med.* XXII.), ZENKER (*Naturforscherversamm.* 1872), and ROTH (*Corresp. f. schweiz. Aerzte* 1874) admit that aneurysms are very generally found in such cases. But they are occasionally absent, and the truth probably is that they are a frequent but not an invariable cause of apoplectic hæmorrhage. See QUINCKE (*Ziemssen's Cyclopaedia* VI.); LANCEREAUX (*Traité de Path.* II.).

305. Dilatation of the capillaries is usually referred to as **capillary ectasis** when it is general ; more localized dilatations are called **capillary aneurysms**. Ectasis chiefly occurs as a result of chronic disorders of the circulation which lead to over-distention of the capillaries with blood ; in other words as a result of long-standing congestion or engorgement. The pulmonary capillaries and the intralobular hepatic vessels in mitral disease afford good examples. The condition often affects the capillaries over a wide area.

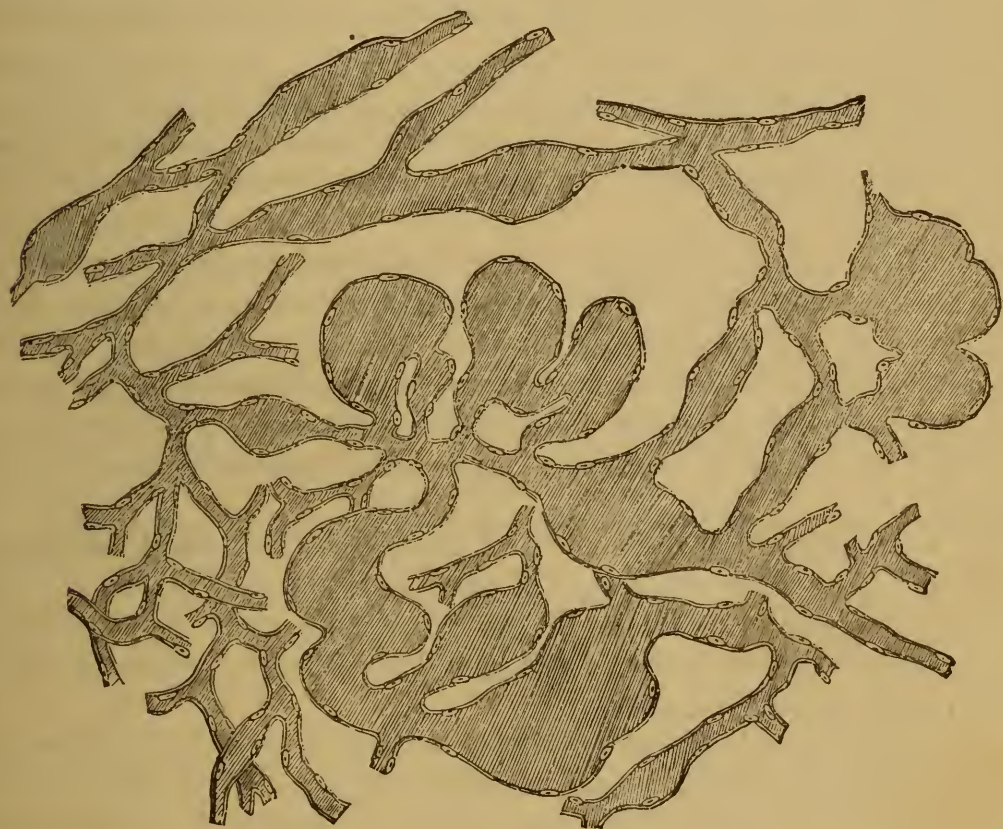


FIG. 132. DILATED OR ECTATIC CAPILLARIES.

(From an angioma or telangiectatic glioma of the brain : $\times 200$.)

Capillary dilatations limited to particular spots are usually due to causes a different kind. Some are congenital, as in so-called vascular nævi. These have already been treated under the head of angiomata in Art. 149.

Fig. 132 gives an idea of their general disposition. Congenital dilatations of the capillaries are most usually met with in the skin ; but they may occur elsewhere, as for instance in the brain (cerebral nævus).

Acquired capillary ectases generally arise in consequence of some morbid change in the tissue in which they lie ; they are common in parts

that have undergone atrophy or shrinkage. It almost appears as if the capillaries were striving to fill up the space left unoccupied by the receding tissue (compare Art. 150 on the formation of cavernous angiomata in the liver). Similar ectases are found in new-formed tissue, whether inflammatory or neoplastic. In these cases it is generally the new-formed vessels which appear dilated. They have either been over-large from the beginning, or have been dilated by some not easily recognizable cause after their first formation.

The capillary ectases occasionally met with in the brain VIRCHOW believes (*Virch. Arch.* vol. 30, with cases) to be in part congenital, and so to be properly classed with the *nævi*; ROTH is of the same opinion. If this be so the specimen figured in Fig. 132 from a telangiectatic glioma might exemplify a congenital condition of the vessels, existing therefore before the development of the substance of the glioma; but of course the point cannot be finally decided (HESCHL, *Wiener med. Woch.* 1868).

The dilatation of the capillaries in atrophic or shrunken tissues and in new-formations is probably dependent on several factors. It is of course a necessary condition that the capillaries shall always be full of blood; so that the shrinkage or atrophy must go on in such a way as not to exert pressure on the capillaries and so to empty them.

306. Dilatations of the veins are described as **phlebectases** or **varices**. They are very common, and occur chiefly as a consequence of mechanical hindrances to the emptying of the veins. Thus they are met with in connection with local or general engorgement, compression of the veins, venous thrombosis, imperfect action of the heart, etc. Their formation is favored by unhealthy conditions of the vessel-walls or their surroundings.

In accordance with their mode of genesis we find them occurring chiefly in places where the venous circulation is normally placed at a disadvantage, especially therefore in the lower half of the body. Their development may constantly be watched during life in connection with the veins of the legs and anus.

The cutaneous veins are either dilated uniformly and over a considerable extent, or bulged into fusiform or irregular sacculations. They are often at the same time elongated and convoluted, the bends of the convolutions being saccular. If two such sacculations are in contact, the vessel-walls may become adherent at the point, and the intervening tissue gradually disappearing by absorption, a new opening may be established between the two. Cavernous sinuses are thus formed, especially in the anal region: they form livid saccular tumors on the hæmorrhoidal veins surrounding the anus, and are referred to as **hæmorrhoids** or **piles**.

Varices affecting the internal organs are most frequently met with in those of the pelvis. **Varicocele** is a dilated and tortuous condition of the veins of the spermatic cord, occurring more frequently on the left side than on the right.

Varices are often not without danger to the patient, especially if they

exist in regions exposed to mechanical injury. Hæmorrhoids are often subject to rupture and hæmorrhage, as well as to inflammation (periphlebitis). Such inflammation may lead to fibrous hyperplasia or to abscess; the latter when bacteria settle in the inflamed tissues. Varicose patches of skin are especially apt to become inflamed on slight occasion, and in this way troublesome and indolent ulcers are produced. These are known as **varicose ulcers**.

Thrombi often form in dilated veins, and when they become calcified constitute the so-called vein-stones or **phleboliths**. In other cases the thrombi disintegrate and give rise to embolism. At times the thrombus becomes organized; the vein is filled up with fibrous tissue, and transformed into an impervious cord.

307. The processes by which arteries and veins may become narrowed or obliterated have already been more than once referred to under obliterating arteritis and the organization of thrombi. These play the chief part in the occlusion of the larger vessels, by setting up thickening of their walls or development of new tissue in their interior; in the smaller vessels they may lead to the conversion of the patent channel into an impervious fibrous cord.

Vessels are thus occluded by changes in their walls or in their contents; but they may likewise become narrowed or obliterated by compression from without, or by morbid processes affecting the tissues in which they lie. The veins are especially liable to such accidents: by the formation and contraction of cicatricial tissue around them large veins, even the vena cava, may be completely obliterated.

See EPPINGER (*Die narbige Obliteration der Vena cava inferior*, *Prag. med. Woch.* 1876).

CHAPTER XVII.

RUPTURE OF THE COATS OF THE VESSELS.

308. Aneurysms and varices may burst (Arts. 304 and 306), and this is the commonest cause of spontaneous hæmorrhage. But rupture may also occur in undilated vessels, when inflammatory and degenerative changes have reduced the natural resisting power of their walls. Lastly, various forms of injury may bring about the rupture of healthy vessels. Simple increase of blood-pressure does not lead to rupture in vessels that are really healthy.

When an artery gives way the ensuing hæmorrhage is great; it continues until the pressure of the blood accumulating in the tissues is as great as that within the bleeding vessel. The mass of gore and infiltrated tissue produced when the extravasated blood coagulates is called an **arterial hæmatoma**.

The rent in the vessel is closed by an aggregation of cohering white blood-cells, which solidifies into a colorless button-shaped plug projecting inwards and outwards from the plane of the rent (SCHULTZ). The plug within the vessel is after a time partly absorbed, and bulged outwards by the pressure of the blood. A sac is thus formed the interior of which communicates with the lumen of the vessel, while the exterior wall is mainly formed by colorless fibrin and the clots resulting from the primary hæmorrhage. Such a sac is called a **false or spurious aneurysm**; and is distinguished from a true aneurysm by the fact that the coats of the vessel form no part of its wall. If plastic inflammation is set up owing to the presence of the clots, an external sac-wall of granulation-tissue may be formed, and this may develop into cicatricial tissue. The fibrinous sac of the false aneurysm may give way again and lead to fresh hæmorrhage. In other cases the rent in the vessel is effectively closed by the transformation of the fibrinous plug itself into fibrous tissue. According to SCHULTZ this transformation is due to the white blood-cells which lodge in the cavity of the sac, and assume the functions of formative cells. White blood-cells likewise lodge in the meshes of the fibrinous sac-wall, and develop into large and active formative cells; these presently get the upper hand as it were, and the fibrin gradually disappears. Fibrous tissue is developed, and new vessels are formed in it, connected partly with the lumen of the old vessel and partly with the

vessels of the neighboring parts. The wall of the vessel itself takes no active part in the process; while the clots lying around it are absorbed.

Wounds of veins heal in the same way as those of arteries; it is rare for a sac or **false varix** of any size to be formed.

See KLEBS (*Beiträge z. Anatomie d. Schusswunden* 1872); CZERNY (*Virch. Arch.* vol. 62); SCHULTZ (*Deutsch. Zeitsch. f. Chir.* IX); PFITZER (*Virch. Arch.* vol. 77); HOLMES (*Syst. of Surgery* III. London 1883); BARWELL (*Intern. encyc. of Surg.* III. London 1883).

309. Sometimes, in consequence of disease or injury of one or other of the arterial coats, the inner and middle coat give way, while the adventitia resists the stress of the blood pressure. The result is that the blood does not at once escape out of the vessel, but strips the middle coat away from the adventitia. A blood-tumor is thus formed which is called a **dissecting aneurysm**. This variety of false aneurysm is chiefly met with in the ascending aorta, and in the smaller arteries of the brain. In the latter case, spindle-shaped dilatations are produced, which are bounded externally by the adventitia while the tube formed by the intima and media runs through the axis. In the case of the aorta, the adventitia is generally stripped loose over a considerable extent. The stress of the blood may indeed separate the adventitia from the other coats throughout the entire length of the aorta, and up the larger trunks, the dissection being only limited by the vessels passing into tissues which bind them down with some firmness. The mass of blood thus intruded between adventitia and media may be of quite remarkable thickness.

See PEACOCK (*Path. of the heart and arteries* Edinburgh 1849); FRIEDLÄNDER (*Virch. Arch.* vol. 78); FAGGE (*Med. chir. Trans.* 1869, with cases).

310. The **varicose aneurysm** deserves special mention. It is occasionally produced by the adhesion of a true aneurysm to a vein, the adhering tissues of the walls becoming gradually absorbed, so that a free communication is at length formed between artery and vein. In other instances, a false aneurysm may become connected with a vein, as when in artery and vein are simultaneously wounded by the same puncture. A true aneurysm intervenes between the two vessels in the former case, a false aneurysm in the latter case; we must thus distinguish true varicose aneurysm from false varicose aneurysm.

311. Occasionally, as the result of a wound we may have a direct connection of the channel of an artery with that of a vein, so that arterial blood pours into the vein without passing through an aneurysmal sac at all. This condition has been described as **aneurysmal varix**. The pressure of the arterial blood gradually dilates the vein, giving it a varicose appearance, and if the condition persists, its wall may become notably thickened.

The non-traumatic forms of varicose aneurysm specially affect the great vessels of the thorax; the traumatic form generally occurs between

the median basilic vein and the brachial artery, at the spot where bleeding from the arm is practised.

312. The **vascular neoplasms**, or tumors in whose structure the blood-vessels play an essential part, have already been discussed in the General Pathological Anatomy. Of this class the angiomata (Arts. 149, 150), the angiosarcomata (Art. 161), and the cylindromata (Art. 163) are the chief species.

Tumors of all kinds may, of course, involve the walls of the blood-vessels in their growth. The adventitia is specially liable to be implicated in carcinomatous or sarcomatous proliferation. The media and intima resist the invasion longer, especially in the case of the arteries; the veins are less resistant. The walls of the veins are often broken into by cancerous growths, so that tumor-particles gain entrance to the blood-current; and in this way cancerous thrombosis is set up. If tumor-germs are swept off from the thrombi, they may give rise to metastatic growths at some other point of the vascular system where they lodge.

CHAPTER XVIII.

THE LYMPHATICS.

313. The **morbid changes** occurring in the lymphatic system do not admit of complete treatment apart from that of the various organs. The lymphatics have their ultimate radicles in the very substance of the tissues ; and arise in the natural meshes and lacunæ which exist in them. Into these meshes or lymph-spaces passes the liquid transuded from the blood-vessels ; the meshes being continuous with lymph-channels, which are devoid of special walls and are only marked off from the parenchyma of the tissues by a layer of endothelial cells. These channels are the radicles of the lymphatics, and are abundant wherever connective tissue is found.

It must be very rare for demonstrable changes to take place in these minute lymph-channels without simultaneous disease of the tissues that enclose them ; they and the tissues are in too intimate relation for one to suffer without the other. The same holds even for the larger lymphatics, though they have walls of their own in addition to the endothelial lining ; it is indeed only the largest lymphatics of all that give marked evidence of their independence.

314. The lymphatics are not frequently inflamed, an affection described as **lymphangitis**, but more properly **perilymphangitis**.

It is generally secondary to some inflammation of the tissues ; the lymph from the inflamed area acting as an irritant on the vessels through which it flows and on the tissues which environ them. It is rare for an irritant capable of setting up inflammation to reach the lymphatics from any other source than from a previously inflamed part. The secondary inflammation may extend far beyond the seat of the primary affection : thus it may reach from a wound in the hand up into the lymphatics and glands of the axilla. During life the affection is recognizable by the existence of red and painful streaks extending from the initial wound to the nearest lymphatic glands.

Minor degrees of inflammation are hardly if at all to be recognized *post mortem*, the redness generally disappearing soon after death ; only when the lymphatics and their contents and surroundings have undergone considerable inflammatory change are the traces plainly visible. Under the microscope however it is not all difficult to make out the

inflamed lymphatics which ramify from the neighborhood of an inflamed area.

The histological changes associated with lymphangitis are mainly these:—the contents of the lymphatics are much more abundant, and much richer in cells, than normal lymph; it is often purulent in appearance; in other cases it is fibrinous or fibrino-purulent; where the inflammation is purulent the endothelium of the lymphatics is shed or disintegrated, in milder forms it is swollen and protuberant; occasionally subdivision of nuclei and cells is observed; the tissues surrounding the vessel, and the vessel-wall, are inflamed with migrated cells, and the blood-vessels are congested; only in the mildest cases of all is the change limited to swelling and desquamation of the endothelium.

The outcome of lymphangitis is either complete restoration *ad integrum* by re-absorption of the exudation and regeneration of the lost endothelium, or necrosis and abscess of the vessel and the tissue surrounding it, or lastly fibrous hyperplasia and induration of both. The latter occurs in chronic inflammatory conditions, and may lead to the obliteration of the vessel.

The infective granulomata may invade the lymphatic system, and the lymphangitis set up often exhibits no special peculiarities; but actual granulomatous change may likewise be induced, and then exhibits its specific characters. In this respect tuberculosis is the best example, as the affection is propagated with special readiness by way of the lymphatic vessels (Art. 122.)

References on lymphangitis and the associated changes:—VIRCHOW, *Virch. Arch.* vol. 23; LÖSCH, *ibid.*, vol. 44; BAUMGARTEN, *Cent. f. d. med. Wiss.* 3, 1882, with further references. On tuberculous disease of the lymphatics see KLEBS (*Virch. Arch.* vol. 44); LÉPINE (*Arch. de physiol.* 1870); PONFICK (*Berl. klin. Woch.* 1877); WEIGERT (*Virch. Arch.* vol. 88).

315. Inflammatory processes affecting the wall of a lymphatic and the surrounding tissue, pressure from without, the eruption of tumors or parasites into the channel, and other like causes, may bring about the **occlusion** of the vessel. If the number of lymphatics thus obliterated is not great, while other vessels remain open so that the lymph of the part can find an exit, no further change is usually induced. Even the thoracic duct may be occluded without serious danger, for other collateral paths are opened up. But if the efflux of lymph is entirely prevented, as in filarial disease (Art. 235), engorgement of the vessels with lymph ensues and the lymphatics become gradually dilated, forming what is called **lymphangiectasis**. This affection may however develop without demonstrable impediment to the outflow of lymph, generally in connection with repeated attacks of local hyperæmia or inflammation, but at times also without any such apparent cause.

Lymphangiectasis following parasitic obstruction and inflammation is chiefly observed in the form of cutaneous and subcutaneous hyperplasia

known as **elephantiasis**. The skin is thickened and on section allows an abundance of clear lymph to escape from the dilated lymphatics. The degree of the dilatation varies of course in different cases: sometimes the epidermis is raised in blisters and bullæ by the accumulated lymph.

Dilated chyloferous lymphatics are very often met with in the mesentery: the usual cause is obstruction due to inflammatory or neoplastic growths seated in the mesentery or thoracic duct. Sometimes the obstruction is due to lymphatic thrombosis. The dilated vessels look like straight cylindrical ridges or convoluted saccular or beaded cords; their contents are either white and limpid or pulpy and caseous.

Lymphangiectases, not associated with engorgement or inflammation, are generally congenital or depend on congenital defects. The affection known as lymphangiectatic **macroglossia** and **macrocheilia**, a peculiar overgrowth of tongue and lips, is due essentially to dilatation of the lymphatics of the parts. Lymphangiectases of the skin such as are often met with in the inguinal region, scrotum, labia pudendi, and on the thorax, are of the same nature. They sometimes form circumscribed tumor-like swellings and are hence classed with tumors as lymphangiomata (Art. 152). It is not possible to draw a sharp line between the swellings which we may fitly call tumors and the others.

The rupture of lymphatics and lymphorrhagia have been referred to in Art. 31.

On the consequences of closure of the thoracic duct see HELLER (*Deutsch. Arch. f. klin. Med.* x.); TURNER (*Edin. med. Journ.* 1859); STILLING (*Virch. Arch.* vol. 88).

On lymphangiectasis and lymphorrhœa see Arts. 31, 152; GEORJEVIC (*Arch. f. klin. Chir.* XII.); PETTERS and KLEBS (*Prag. Vierteljahrsschr.* 125); MANSON (*Med. Times and Gaz.* 2, 1875, and *The Filaria sanguinis hominis* London 1883); WIENKOWSKI (*Wien. med. Woch.* 33, 1877); DÉSSERT (*Des dilatations lymphatiques*, Thèse de Paris no. 131, 1877); LESSE (*Ludwig's Arbeiten* 1872); QUINCKE (*Arch. f. klin. Med.* XVI., with references to cases); NIEDEN (*Virch. Arch.* vol. 90); WEGNER (*Arch. f. klin. Chir.* XX.); LEWINSKI (*Virch. Arch.* vol. 91). On macroglossia see BARKER (*Holmes's Syst. of Surgery* II. London 1883, with references).

316. In addition to the lymphatic tumors described as lymphangiomata we have a class of growths specially affecting the lymphatic vessels, and known as **endotheliomata** or **endothelial cancers**. They have been described chiefly as tumors of the serous membranes, of the pia mater, and of the skin; and they are either flattened and diffuse, or circumscribed. According to the principles already laid down (Art. 166), they are to be reckoned as sarcomata, characterized by endothelial proliferation and by the formation of peculiar nests and clusters of cells lying in a kind of fibrous stroma; the structure thus resembles in many points that of carcinoma. But it must be noted that many tumors described as endotheliomata have been really genuine carcinomata, which had irrupted into the lymph-channels. This is true of many of the so-

called endotheliomata not only of the skin but also of the serous membranes (Art. 358).

The endothelial cells of the lymphatics may take part in the growth of any of the connective-tissue group of tumors; but they do not give rise to any special peculiarities of structure.

The lymphatics very frequently participate in the growth and **propagation of the epithelial neoplasms.** This is notably the case with regard to carcinoma, which often breaks into the lymph-channels and there forms cancerous nodules and bands. Thus from a mammary carcinoma infection may spread to the lymphatics, not merely of the neighboring surface tissues, but even of the pleura and subpleural connective tissue. In this way long trains and cluster of cancer-nodules may be formed following the lines of the pleural lymphatics. The share taken by the endothelial cells in the process of propagation is still under discussion. Many are of opinion that they give rise to cancer-cells. This is very far from being demonstrated, but it is perhaps possible. The author has observed in some instances that the endothelial cells were proliferous, but has no evidence that they became transformed into cancer-cells. Meanwhile it is probably true that if they produce tissue at all, it is fibrous tissue; that is to say they give rise to cancer-stroma, not to cancer-cells.

On endothelioma see Art. 161; KÖSTER (*Die Entwicklung d. Carcinome* 1869); PAGENSTECHER (*Virch. Arch.* vol. 45); EBERTH (*Virch. Arch.* vol. 49); ARNDT (*ibid.* vol. 51); PERLS (*ibid.* vol. 56); WALDEYER (*ibid.* vol. 55); WAGNER (*Arch. d. Heilk.* (1870) XI.); NEELSEN (*Arch. f. klin. Med.* XXX., with cases and references).

SECTION III.

THE SPLEEN AND THE LYMPHATIC GLANDS.

CHAPTER XIX.

STRUCTURE AND FUNCTIONS OF THE SPLEEN.

317. Structure of the spleen. The spleen plays a peculiar and important part in connection with the elaboration and metabolism of the blood; and its relation to the blood accounts in some measure for its anatomical structure and for its special relation to the vascular mechanism. The proper or characteristic tissue of the spleen is the pulp, and this is so intimately connected with the vascular system that its interspaces constantly contain both the fluid and the corpuscular elements of the blood in abundance. The volume of the adult spleen is from 150 to 180 ccm.

The **spleen-pulp** consists of a delicate membranous reticulum or 'honeycomb' traversed by stouter strands or trabeculæ originating in the capsule or in the fibro-cellular (lymphadenoid) sheaths that ramify with the vessels from the hilum. The interspaces of the reticulum are in communication with wide, thin-walled capillaries and veins deriving their blood-supply from the arteries, which enter at the hilum and bifurcate dichotomously into minute arterioles. The capillaries of course intervene between the arterioles and the radicles of the veins. It has been shown that the capillary-walls are not continuous but interrupted, so that blood can permeate freely the meshes of the pulp. And even if, as some maintain, there are no easily-visible clefts or pores in the vessels, it is at least certain that the walls are in so far more pervious than the walls of other vessels that the corpuscles pass through them with great ease, and that the mass of the pulp is in part made up of blood-cells. The reticulum contains lymphoid cells, larger round colorless cells with one or more nuclei, and ordinary red corpuscles, together with corpuscle-carrying cells, pigment-granule cells, and free yellow or brownish pigment. This pigment in conjunction with the blood gives the spleen its brownish-red color.

The spleen contains besides certain special structures known as **malpighian follicles** (or corpuscles). They are composed of lymphadenoid tissue, continuous with the cellular connective tissue sheathing the arteries and forming indeed but a modification of it. They contain colorless cells only, and their blood-vessels are narrow capillaries, which unite and open into wide venous channels or sinuses at the periphery of

the follicles. The color of these lymphoid follicles is therefore pale or grayish-white.

The capsule and the trabeculæ contain numerous unstriated muscular fibres, which are arranged with some regularity.

The outer form of the spleen is somewhat variable, but it is generally more or less flattened or tongue-shaped. It is often remarkably lobulated, or at least deeply indented. Small detached **spleniculi**, from the size of a bean to that of a hazel-nut, are occasionally found near the spleen. Misplacements of the spleen are common, and it is occasionally wanting altogether.

318. The **functions of the spleen** are as yet imperfectly ascertained. It is very probable that the red corpuscles are broken up within its meshes; that is to say that worn-out or useless red corpuscles pass into the splenic tissue (Art. 268) and there undergo further changes. According to QUINCKE and KUNKEL a part of the iron contained in the red corpuscles which are disintegrated is utilized in the formation of new ones, while another part passes into the liver for elimination. Recent researches have thrown doubt on the formerly-accepted theory that red corpuscles are manufactured in the spleen itself. The most recent investigators are divided on the question, NEUMANN being against the older view, and TIZZONI for it. BIZZOZERO rejects altogether the idea that blood is normally manufactured in the spleen after the close of the foetal period; but he thinks the spleen may resume such a function in certain peculiar conditions, as in anæmia. So much at least is sure, that the red corpuscles met with in the splenic pulp are not new-formed, but have escaped from the blood-vessels; and that they either return to the blood after undergoing some alteration, or are destroyed. If new cells are furnished to the blood by the spleen at all, they are colorless cells derived from the lymphadenoid sheaths of the arteries.

The view that the worn-out and useless red corpuscles are brought to the spleen and there broken up is supported by pathological facts. When the disintegration of red corpuscles in the blood is by any cause (such as malaria, Art. 268) increased, the number of cells containing red corpuscles and pigment, and the amount of free pigment, in the spleen is likewise increased. The organ may indeed become thereby stained of a deep russet or slate color. We may suppose that the increased disintegration sets free more pigmentary matter that can be utilized in the formation of new corpuscles or eliminated through the liver, and so it accumulates in the spleen.

Foreign matters circulating in the blood are specially apt to be deposited in the spleen (Art. 266): it is clear that the diminished current in the wide capillaries and veins, and their pervious walls, greatly favor such deposition.

On the structure of the spleen see KLEIN (*Quart. J. micro. sci.* 1875, *Atlas of Histology* London 1880).

The more recent researches on the functions of the spleen have been those undertaken by NEUMANN (*Arch. d. Heilk.* xv., *Berl. klin. Woch.* 20, 1880, *Zeitschr. f. klin. Med.* III.), FOÀ and SALVIOLI (*Arch. p. l. scienze med.* IV.), BIZZOZERO (*ibid.* I., *Arch. ital. de biol.* I.), TIZZONI (*Acad. dei Lincei* x. Ser. 3, *Arch. ital. de biol.* I.), KORN (*Virch. Arch.* vol. 86), ROY (*Camb. Journ. of Physiol.* III.), WINOGRADOW (*Cent. f. d. med. Wiss.* 50, 1882). NEUMANN pronounces definitely against the view that during extra-uterine life the spleen takes any part in the elaboration of the blood. BIZZOZERO, FOÀ, and SALVIONI are of opinion that after serious hæmorrhage the spleen does aid in manufacturing new blood. TIZZONI likewise thinks that blood may not only be destroyed but produced in the spleen; resting his opinion on the results of extirpating the spleen in dogs. The proportion of hæmoglobin in the blood rises shortly after the operation; in about two days it returns to the normal, and then sinks more or less below it, to rise again after a certain interval. The last effect is due to the fact that not only is the blood-destroying function of the bone-marrow increased but also the blood-producing function. He finds that extirpation is occasionally followed by reproduction of splenic tissue in the form of numerous (60 to 80) nodules lying in the omentum, and more sparsely in other parts of the peritoneum. These cellular nodules when mature consist of malpighian follicles, pulp, and a capsule; and they may coalesce into larger masses. They contain young nucleated red corpuscles. FOÀ disputes TIZZONI'S account of the structure and function of these nodules, and does not believe that they have any relation to the presence or absence of the spleen (*London med. Record* July 1883). ROY has discovered that in health the spleen expands and contracts rhythmically by means of the muscular tissue contained in its capsule and trabeculæ; and he believes that the circulation of the blood through the organ is maintained not by the general blood-pressure but by the force of these rhythmical contractions.

CHAPTER XX.

DISORDERS OF CIRCULATION AND INFLAMMATIONS OF THE SPLEEN.

319. The amount of blood contained in the spleen is subject to considerable and incessant physiological variation. During digestion the organ increases in size from congestive hyperæmia, which passes away as the blood-supply diminishes on the contraction of the afferent arteries; the reduction in size being further aided by the tension of the elastic fibres and the contraction of the unstripped muscular fibres of the trabeculæ and the capsule.

Congestive hyperæmia may in like manner occur as a morbid condition exceeding the physiological condition in intensity and duration. In all the infective disorders of the system, as in typhoid and other acute exanthemata, in syphilis and in pyæmia the onset of the disease is accompanied by splenic hyperæmia. The spleen enlarges, and that in much greater proportion to its size than do the other organs which become hyperæmic at the same time: this is due to the fact that not merely are the capillaries and veins distended with blood, but also the mass of the splenic pulp which is in free communication with them. Such a spleen looks large and its capsule is tense; the pulp is deep red, and so soft that on section it may be easily scraped away. The malpighian follicles sometimes stand out distinctly as white nodules, sometimes are scarcely recognizable amid the swollen pulp.

320. The congestive hyperæmia may pass away rapidly, but it often persists for some time and further changes are set up in consequence. This is especially the case with the enlargement accompanying the acute infective diseases, such as typhoid, pyæmia, relapsing fever, ague, acute nephritis, and scarlatina. The spleen of a patient dead of typhoid at the beginning of the second week, or of septicæmia about the fourth or fifth day, appears not red but grayish or pale reddish-gray; its volume is greater than in simple congestion, reaching perhaps the double or the quadruple of its normal size. The pulp is extremely soft, almost diffluent, the softness being often however due in part to commencing putridity: in extreme cases the capsule may be so strained as to rupture.

In such a condition the spleen cannot be regarded as affected simply by excessive hyperæmia. The microscope shows that the vessels and

pulp are not distended with red cells as in hyperæmia, but that both contain an extraordinary number of white cells ; and it is these that give the tissue its grayish tint. Whence they come is not easy to determine, though it is highly probable they reach the spleen by the channel of the circulation. Possibly too the production of lymphoid elements within the malpighian follicles may be abnormally increased ; but the follicles show little or no sign of increase in size.

This form of enlargement of the spleen is in fact to be regarded as inflammatory, the evidence of a true **splenitis**. In support of this it may be mentioned that the exterior or capsular surface often shows signs of accompanying inflammatory change, such as turbidity of the capsule and deposits of fibrin upon it. It is of course more difficult to draw a hard and fast line between hyperæmia and inflammation in the case of the spleen than in other organs, for the spleen normally contains blood-cells which have escaped from the vessels.

The cells lying in the swollen grayish pulp are in part exactly like lymphoid elements, in part larger and with clear vesicular nuclei. A considerable number of the lymphoid cells contain red corpuscles or fragments of such in their interior ; a sign that the destruction of red corpuscles is not only not diminished but actually increased.

As foreign matters circulating in the blood are apt to be deposited in the spleen, it is very probable that organized infective matters may in like manner tend to lodge there, and so lead to inflammatory vascular changes. Many such organisms are probably destroyed in the spleen. See BIRCH-HIRSCHFELD (*Arch. d. Heilk.* XIII.), FRIEDREICH (*Samm. klin. Vorträge* 75), SOCOLOFF (*Virch. Arch.* vol. 66), FISCHL (*Prag. med. Woch.* 1879), KLEIN (*Trans. Path. Soc.* 1877).

321. The **consequences** of congestive hyperæmia and inflammation of the spleen are various.

As the general disease passes away the infiltrative swelling of the spleen-pulp usually diminishes. The red and white blood-cells that remained lodged in the pulp are gradually passed on, and the spleen recovers its normal bulk and appearance. As the swelling declines cells may be found containing not only fragments of blood-cells, but also oil-globules ; a sign that they are in process of decay.

In other cases the changes may be more permanent and assume the form of fibrous **hyperplasia** of the pulp, trabeculæ, vessel-walls, and capsule, together with enduring pigmentation. These changes are especially apt to occur when the hyperæmic condition recurs frequently (as in malaria), or when the inflammation takes on a formative or plastic character. Diffused or circumscribed thickenings then appear on the capsule, and may take the form of flattened lenticular nodules, or large dense cartilaginous patches. Occasionally the entire capsule is transformed into a coarse scar-like fibrous mass (BILLROTH, *Virch. Arch.* vol. 23 ; WILKS, *Trans. Path. Soc.* 1864).

Adhesions of the spleen to the surrounding structures in consequence

of inflammation (**perisplenitis**) are common ; false membranes may thus be formed uniting the spleen with the diaphragm, the splenic flexure of the colon, and the fundus of the stomach, and cause difficulty in dissecting out the spleen *post mortem*. But all such adhesions are not evidence of primary splenic inflammation ; inflammatory processes set up in the neighborhood of the spleen may induce secondary inflammation in the latter.

The appearance of the spleen varies in such cases ; it may be small and granular on the surface, or it may be considerably enlarged. The latter is notably the case in chronic malarial disease (**ague-cake**). The variety of size depends chiefly on the scantiness or abundance of the pulp ; but the trabecular frame-work may be hyperplastic and contribute to the general enlargement. The tint of the pulp also varies greatly. If it contains little or no pigment, it is bright red ; if pigment is abundant, it is brown or slate-colored. Its consistence is firm, so that on section it is not easy to remove the pulp by scraping. The number of lymphoid cells in the pulp is on the whole inconsiderable ; when pigment is present at all, these cells usually contain most of it in the form of yellow, brown, or black granules ; free pigment also occurs. The endothelial cells of the venules and some cells of the malphigian follicles likewise contain fine granules of pigment.

The trabeculæ are more or less thickened ; in marked cases the thickening may be recognizable by the unaided eye. It is only in very firm or hard spleens that the finer reticulum of the pulp is sensibly thickened. The walls of the arteries and veins are likewise thickened and pigmented, the pigment lying free in the walls or enclosed in cells. The changes in question are exhibited most markedly by patients who have suffered from malaria, but they are also met with in connection with other affections, such as typhoid. The pigmentary changes are due to increased destruction of blood-cells in the blood and the spleen.

322. Inflammation of the spleen rarely passes into **suppuration**. When it does the colorless cells accumulate in the pulp and follicles in great numbers, giving the whole tissue a yellowish-white tint. In very rare cases the entire substance suppurates ; the spleen being changed into a gray or grayish-red creamy mass. Circumscribed suppurations are commoner. The tissue about to break down takes on a grayish or yellowish-white color, and then becomes diffuent or liquid, forming **splenic abscesses**.

These occur chiefly in pyæmic affections, and in relapsing fever (PONFICK) ; that is to say in affections depending on bacterial invasion of the blood.

The tissue around a splenic abscess is generally discolored and infiltrated with pus ; it is less usual for the abscess to be shut off by an enclosing membrane of granulation-tissue. The abscess often breaks through the capsule ; and should the pus enter the peritoneal cavity,

fatal peritonitis ensues. But if adhesions have previously been set up between the spleen and the stomach-wall or diaphragm or colon, the abscess may break into the stomach or thorax or intestine.

See BESNIER (*Art. Rate in Dict. encyclop. d. sciences méd.*), PONFICK (*Virch. Arch.* vol. 60), MOSLER (*Ziemssen's Cyclop.* VIII.), WARDELL (*Reynolds' Syst. of Med.* v.).

323. Passive hyperæmia of the spleen follows upon such disorders of the circulation as interfere with the flow of blood through the splenic vein. Such are affections of the liver on the one hand, of the heart and lungs on the other. Cirrhosis of the liver is the chief of the former class, inasmuch as it often leads to the obliteration of the greater number of the portal capillaries within the liver.

When engorgement of the spleen has persisted for some time, the organ is usually found to be either normal in size or somewhat enlarged; it is rarely diminished. It is commonly more cup-shaped than in health, and the edges are more rounded. It is always firmer and sometimes actually hard, owing to the density of the pulp, which may be bright-red or dark in color. Hardly any of the pulp can be scraped off from the section; the trabeculæ stand out sharply; and the capsule is often thickened. The chief textural alteration in such a spleen is the increased amount of fibrous tissue it contains, the increase appearing in the trabeculæ and in the walls and sheaths of the vessels. The venous sinuses are of course dilated. Occasionally the reticulum of the pulp is found to be slightly thickened.

Anæmia of the spleen, such as follows upon great hemorrhage, is manifested by the very pale color of the tissue.

324. Embolic infarctions of the spleen, or the cicatrices to which they give rise, are very often to be observed in the post-mortem room. The emboli are generally derived from endocarditic vegetations or from thrombi of the heart or aorta. The infarcts are of various sizes; small ones may be as large as a cherry, larger ones may extend over as much as a half or more of the whole spleen. In the early stages of their existence they appear as pale yellowish (anæmic) or dark-red (hæmorrhagic) wedge-shaped patches with the base outwards, and on section project above the general level; in the hæmorrhagic patches the decolorizing process begins almost at once. The infarcts which one generally sees are either of one color throughout, or the centre is pale while the margin remains dark. When decolorization is well begun, the centre is brownish-red or orange or opaque gray or yellowish-white; the marginal zone, if there is one, will then be dark-red.

When the red or hæmorrhagic infarct is examined under the microscope it is seen that the veins, capillaries, and pulp are all distended with blood. The follicles are hæmorrhagic only at their margins, the centres being unstained. In decolorized infarcts the red corpuscles appear in part disintegrated, and in part distorted and discolored. The nuclei of the tra-

beculæ are no longer visible, the trabeculæ themselves being swollen and beset with oil-globules. The lymphoid elements are either gone, or in process of breaking up into granular and fatty detritus, and few nuclei are visible. At a later stage the reticulum and cells are alike transformed into a granular mass, in other words the entire tissue has perished by necrosis. Traces of the normal structure remain only in the marginal zone of the infarct, in which staining reagents still bring out the nuclei of the cells and the trabeculæ.

Plastic inflammation of the surrounding spleen-tissue accompanies the necrosis, a congested zone of demarcation is formed, and the necrotic mass is by degrees re-absorbed. After a time a dense shrunken radiating cicatrix is formed in the site of the infarct; it is often pigmented, or flecked with shining white spots. Large infarcts are sometimes imperfectly reabsorbed, so that the cicatrix encloses a necrotic caseous patch. If bacteria or other septic virus reach the seat of infarction, purulent or putrid inflammation may be set up instead of the changes just described.

See BILLROTH (*Virch. Arch.* vol. 23), COHNHEIM (*Untersuch. üb. d. embol. Processe* Berlin 1872), LITTEN (*Untersuch. üb. d. hæm. Infarct.* Berlin 1879), GUILLEBEAU (*Die Histologie d. hæm. Infarcts* In. Diss. Berne 1880), WEIGERT (*Virch. Arch.* vol. 79), HAMILTON (*Liverpool med.-chir. Journ.* 5, 1883; the existence of the red or hæmorrhagic form is questioned), ORTH (*Lehrb. d. spec. path. Anat.* I. Berlin 1883; the larger infarcts are stated to be nearly always of the anæmic form). English authors generally refer to such infarcts as fibrinous blocks or deposits.

CHAPTER XXI.

DEGENERATIONS AND INJURIES OF THE SPLEEN.

325. **Simple atrophy** of the spleen occurs chiefly in aged or marasmic patients, especially in case of long-standing anæmia. The organ is small, the capsule wrinkled and sometimes thickened. The pulp seems loose and pale; and the trabeculæ stand out sharply. Under the microscope the cells of the pulp are seen to be scanty and the blood-vessels imperfectly filled.

Amyloid degeneration is the most notable of the retrogressive processes affecting the spleen; two forms of amyloid spleen are distinguished—the ‘sago’ spleen, and the ‘bacon’ spleen.

In the **sago spleen** the malpighian follicles are the seat of the amyloid change. The spleen is generally somewhat enlarged and firmer than is normal. In the brownish- or grayish-red pulp lie light-brown hyaline translucent grains like boiled sago, somewhat larger than the normal follicles. When dilute solution of iodine is poured over the previously-washed surface, the grains become deeply stained of a brownish-red color: a section steeped for a short time in methyl-violet and then washed in alcohol containing a little hydrochloric acid shows the grains red on a bluish ground.

The uniformly lardaceous or **bacon spleen** is in general very considerably enlarged, and firm and resistant to the touch. On section the pulp shows diffuse or continuous patches which are hyaline or translucent, resembling somewhat the fat of fried bacon. Sometimes the greater part of the pulp is thus transformed, the normal tissue appearing in scattered islets only.

The amyloid change mainly affects the trabeculæ and the walls of the venous sinuses. The lymphoid elements of the follicles and the pulp-cells are affected secondarily. Amyloid trabeculæ swell up greatly and become nodulated or varicose. The cells lying in the interstices become atrophied and so perish; it is possible that some of them may be transformed into amyloid substance. Arteries whose lymphoid sheaths are degenerate may themselves either be free from change, or may degenerate in like manner. When the pulp becomes amyloid the walls of the capillaries and venules become thickened and degenerate.

See VIRCHOW (*Virch. Arch.* vol. 8), KYBER (*ibid.* vol. 81, with references), EBERTH (*ibid.* vols. 80, 84).

326. **Rupture** of the spleen may occur spontaneously when the organ becomes abnormally enlarged. Traumatic rupture is more common, and may occur in a healthy spleen or in one which has already undergone morbid change. Ruptures of any considerable size are followed by very grave hæmorrhage. If the hæmorrhage is stayed by the formation of a thrombus filling the rent, the wound may heal as in other organs; the clot is gradually absorbed and a scar takes its place. The same process takes place in other wounds of the spleen. Death sometimes ensues not from primary hæmorrhage but from suppurative inflammation set up in the wounded tissue.

CHAPTER XXII.

INFECTIVE GRANULOMATA OF THE SPLEEN.

327. **Tubercle** is very frequently found in the spleen. In attacks of general miliary tuberculosis miliary tubercles are nearly always developed both in the parenchyma and in the capsule. In chronic tuberculosis such tubercles as may happen to be produced in the spleen give rise to caseous nodes of various sizes. The tubercles are seated in the malpighian follicles, in the lymphoid sheaths of the vessels, and in the pulp. They may consist entirely of small cells or be caseous in the centre, according to their age.

Gummata rarely develop in the spleen, though they are sometimes met with in both congenital and acquired syphilis. They may be single or multiple, and form gray and translucent or yellow and opaque nodes with grayish margins, according to their age. The grayish margin consists of cellular granulation-tissue, which is stained intensely with coloring reagents, and passes gradually into the normal tissue of the pulp.

Syphilis may also manifest itself by a general **hyperplastic enlargement** of the spleen, which is observed mainly in the congenital form of the disease. The spleen of a new-born infant weighs about nine grammes or 0.3 per cent of the body-weight; in syphilitic infants the average weight of the spleen is, according to BIRCH-HIRSCHFELD, some fourteen grammes or 0.7 per cent of the body-weight. Its stroma is increased in amount, and the sheaths of the arteries infiltrated with cells. BIRCH-HIRSCHFELD found oil-globules and pigment-granules in the constituent cells of the pulp.

On syphilis of the spleen see WEIL (*Arch. f. klin. Med.* XIII.), WEVER (*ibid.* XVII.), BÄRENSPRUNG (*Die hereditäre Syphilis* Berlin 1864), WAGNER (*Arch. d. Heilk.* IV.), MOSLER (*Berl. klin. Woch.* 1864), GEE (*Brit. Med. Journ.* 1, 1867), GERHARDT (*Lehrb. d. Kinderkrankh.*), BIRCH-HIRSCHFELD (*Arch. d. Heilk.* 1875 and *Gerhardt's Handb. d. Kinderkrankh.* IV.), BÄUMLER (*Ziemssen's Cyclop.* III., for further references), TEPEL, (*Path. Anat. d. hered. Syph.* In. Diss. Berlin, 1874), BARLOW (*Path. Soc. Trans.* 1877).

CHAPTER XXIII.

HYPERPLASIAS AND TUMORS OF THE SPLEEN.

328. We have already (Art. 321) referred to various forms of enlargement of the spleen associated with acute infective diseases. Such enlargements are partly due to an increase of the pulp, and partly to an increase in the fibrous framework. But there is another and very important form of **splenic hyperplasia**, whose ætiology is altogether obscure, although it constitutes a grave disease.

This form of hyperplasia usually extends over the entire spleen; it is rarely limited to isolated patches. So far as is known the affection commences with an increase of the parenchyma as a whole, the constituent elements undergoing a general hyperplasia. The tissue is bright-red and soft, while the follicles are not separately distinguishable. In a much rarer form of the disorder the malpighian follicles become hypertrophied, and stand out as grayish nodules or in white lobulated clusters.

As the parenchyma increases in size the originally soft tissue becomes firmer, and at the same time paler. The follicles are often still unenlarged, but they may at this stage become hypertrophied and form whitish nodes and clusters of considerable size. The capsule is in general somewhat thickened and beset with coarse fibrous patches of various sizes; and adhesions are often formed with the surrounding organs. The enlargement thus brought about may be very remarkable, the weight of the spleen sometimes reaching three or four kilogrammes.

In the earlier stages the hyperplastic enlargement of the pulp and follicles, in so far as it is independent of the amount of blood present in the spleen, is due to an increase in the number of the constituent cells. When the follicles develop into nodes of any size they compress the spleen-pulp between them, and it often becomes atrophied in consequence. It is then found to contain fatty cells and pigment-granules either free or enclosed in other cells. The section thus assumes a delicately mottled and speckled appearance, the brown and yellow atrophied and pigmented pulp alternating with grayish and yellowish follicular nodules. The disorders of circulation consequent on these textural alterations often lead to the formation of hæmorrhagic infarcts, and these according to their age appear as red, brown, or yellow patches.

In old hyperplastic spleens the enlarged follicles are found to have lost their original structure, and form fibro-cellular masses without any clear traces of the reticular or lymphadenoid type. The pulp itself may become more or less fibrous.

The changes just described may occur primarily in the spleen, or may follow upon like changes in the lymphatic glands and bone-marrow (Art. 344). In the former case a similar affection of the lymphatic glands is associated with the primary affection of the spleen. Afterwards tumors consisting of lymphadenoid tissue may form in organs which normally contain none of it.

The splenic as well as the lymphatic hyperplasia is very often associated with leukæmia (Art. 260), and is therefore often referred to as **leukæmic hyperplasia**. If no leukæmia exists, the affection is described as **pseudoleukæmia or Hodgkin's disease**, or as splenic (or lymphatic) anæmia. The latter description refers to the fact that patients suffering from the affection become profoundly anæmic and ultimately die of anæmic exhaustion.

We know nothing of the cause of leukæmic or pseudoleukæmic hyperplasia of the spleen. In some cases the affection has been preceded by some form of injury or infective disease, in other cases there has been nothing of the kind. We are as little able to say whether or not the two forms are identical. Their identity would seem to be indicated by the fact that they show no anatomical differences, and that one form may pass into the other. The affection may occur at any age.

When the process begins in the lymphatic glands (as in so-called **adenia**) and attacks the spleen secondarily, it is the lymphoid follicles of the spleen which first exhibit a hyperplastic multiplication of their cells.

References:—Art. 344; HODGKIN, *Med. chir. Trans.* XVII. (1832); VIRCHOW, *Virch. Arch.* vol. 5, and *Gesamm. Abhand.* 1856; MOSLER, *Path. und Therap. d. Leukämie* Berlin 1872, with references to the earlier literature of the subject; PONFICK, *Virch. Arch.* vols. 56, 58; BIRCH-HIRSCHFELD, *Gerhardt's Handb. d. Kinderkrankh.* III.; COHNHEIM, *Virch. Arch.* vol. 33; TROUSSEAU, *Clinical Medicine* (New Syd. Soc.) v.; EBERTH, *Virch. Arch.* vol. 51; LANGHANS, *Virch. Arch.* vol. 54, CORNIL and RANVIER, *Man. Path. Hist.* I.; MURCHISON and SANDERSON, *Trans. Path. Soc.* 1869-70, with cases and references; GREENFIELD, GOWERS, *ibid.* 1878; WILKS, *Guy's Hosp. Rep.* 1865, *Lancet* 1, 1878.

329. If we leave out of account the hyperplastic enlargements of the spleen just described, which resemble the true tumors in several respects and especially in the occurrence of associated metastatic growths, we find that **primary neoplastic tumors** of the spleen are very rare. Fibroma, sarcoma, and angioma, have been met with. LANGHANS has described (*Virch. Arch.* vol. 75) a case where an injury was followed by the growth of a pulsating cavernous angioma of the spleen with metastases in the liver, the splenic growth occupying nine-tenths of the already greatly enlarged bulk of the organ. Dermoid tumors are likewise very rare. Cysts containing blood or serous liquid are sometimes met with.

Metastatic growths, especially carcinomata, are more common than

the primary forms; secondary carcinoma usually taking the form of rounded nodules.

Pentastoma (Art. 225) is the commonest of the **animal parasites** infesting the spleen. It forms nodes as large as a pea, which are usually calcified. Echinococci and cysticerci are also occasionally met with.

CHAPTER XXIV.

ATROPHY AND DEGENERATION OF THE LYMPHATIC GLANDS.

330. The **lymphatic glands** stand to the lymphatic system somewhat in the same relation as the spleen to the blood-vessels. The glands may be described as masses of lymphadenoid tissue (that is to say, of reticular fibrous tissue containing lymphoid cells in its meshes) aggregated here and there around the lymph-channels. They contribute to the lymph the lymphoid elements produced in their follicular mesh-work, and perhaps exert upon it some chemical influence besides.

The lymph passing through the glands is derived from a threefold source. The chief source is the transudation from the blood. This permeates the tissues, giving up to them some of its constituents and taking up from them some products of their metabolism: while at many points of the body, and especially at the absorbing mucous surfaces, substances enter and mingle with the lymph which are originally derived from without the body.

From the normal sources of the lymph the lymphatic glands may in like manner receive noxious matters; and these may be such as to induce more or less grave disorders of function, and even of anatomical structure. Thus the lymphatic glands are liable to secondary disease, following upon primary disease of the tissues whence their lymph is derived.

In addition to these the lymphatic glands are subject to various forms of independent disease, which are partly retrogressive and partly progressive or constructive in their nature.

331. **Simple atrophy.** In advanced age the lymphatic tissues generally are observed to undergo senile diminution; the lymphatic glands become smaller, and the lymphadenoid tissue of the mucous membranes becomes scantier. The thymus gland, which is of the same nature, dwindles away in the early years of life.

The decrease in the volume of the lymphatic tissues is due to a diminution in the number of their lymphoid elements. In the case of the thymus these elements disappear wholly, and the remaining connective tissue becomes transformed into fat.

This general physiological retrogression may be imitated under morbid conditions, especially in the general marasmus of children; but

wasting of the lymphatic tissues may also follow upon localized disease. The mesenteric glands are those most apt to atrophy.

In such cases the lymphoid elements, and chiefly those of the medullary cylinders, are the first to disappear. Sometimes the lymphoid elements entirely disappear and the reticulum is changed into adipose tissue, beginning at the hilum. Atrophied lymphatic glands, if not morbidly pigmented, have a light gray tint and are usually firmer than is normal: when transformed into fatty tissue, the change is sufficiently apparent.

332. **Amyloid degeneration** of the lymphatic glands is a common affection. Usually other organs are affected by it at the same time; it is rarely confined to the glands alone. When it is, the cause is nearly always some chronic suppuration within the territory whence the lymph-

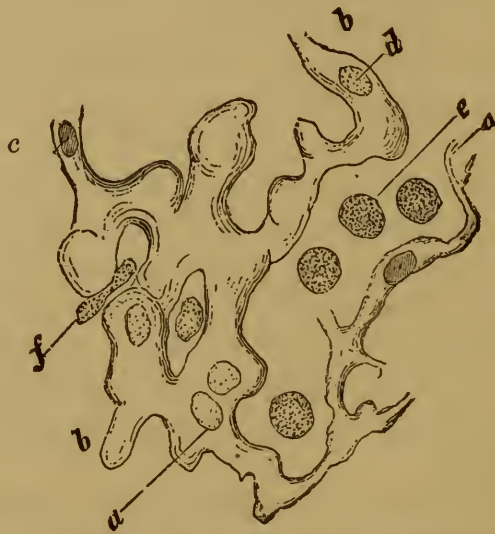

FIG. 133. AMYLOID SWELLING OF THE ADENOID RETICULUM.

(After *EBERTH*: methyl-violet staining: $\times 350$.)

- | | |
|-------------------------------|--|
| <i>a</i> , normal reticulum. | <i>d</i> , degenerate nucleus. |
| <i>b</i> , swollen reticulum. | <i>e</i> , normal lymphoid corpuscle. |
| <i>c</i> , unaltered nucleus. | <i>f</i> , atrophied lymphoid corpuscle. |

supply of the affect glands is drawn. If the amyloid change is at all advanced it is often distinguishable by the dull grayish tint and firm consistence of the glands on section; to make certain however, we must employ the iodine or methyl-violet reaction, or examine the glands microscopically. When they are really amyloid the iodine brings out brownish-red flakes and patches in the lymphoid tissue or on the walls of the blood-vessels. Sometimes the sinuses are most affected: in other and more usual cases it is the follicles and interfollicular septa. The capsule is frequently more or less thickened.

When a markedly amyloid lymphatic gland is closely examined, it gives one the impression that the masses of amyloid substance are partly the lymphoid corpuscles transformed into shining blocks, and partly the reticulum and septa which have become swollen and hyaline. *EBERTH*

however has shown (*Virch. Arch.* vol. 80) that the lymphoid corpuscles very rarely if indeed ever take part in the amyloid change. The shining amyloid blocks, which are of about the same size as the corpuscles, are really derived from the degenerate reticulum.

The process of degeneration begins with a hyaline thickening of the reticular trabeculæ (Fig. 133 *a*). Then the trabeculæ become nodulated (*b*) and form contiguous blocks or lumps. The nuclei of the reticulum (*c*) often remain unaltered for an astonishingly long time. They ultimately become very pale (*d*), cease to stain blue with methyl-violet, and then break up and disappear. The lymphoid corpuscles diminish in proportion as the reticulum thickens, and may here and there disappear entirely. In the larger vessels it is chiefly the media which is affected, in the capillaries it is the adventitia.

Hyaline degeneration of the lymphatic glands has quite recently been described by CORNIL; it has a certain resemblance to amyloid change but is essentially distinguished from it by the absence of the reaction with iodine and methyl-violet (Art. 63). The change in some instances affects mainly the blood vessels of the gland (WIEGER, *Virch. Arch.* vol. 78), which are transformed into hyaline tubes by the thickening of their walls and the narrowing of their channel. In other cases hyaline masses are formed from the reticular cells; the hyaline masses are probably related to the colloid substance (Art. 56). Their presence is recognizable by the whitish somewhat opaque trabeculæ which run through the grayish-red tissue of the gland. Calcification often sets in when the degeneration reaches a certain stage.

There is another variety of homogeneous degeneration which deserves mention. It is met with chiefly in glands which are the seat of larged-celled hyperplasia (Art. 340), or of tubercle (Art. 342). It was shown in Art. 39 that this variety of degeneration is closely allied to caseation (Art. 333). Some authorities (such as ARNOLD, *Virch. Arch.* vol. 87) see in it a special kind of degeneration, which only in its advanced stages leads to caseation.

Reference:—CORNIL, *Journ. de l'anat. et de la phys.* 1878; CORNIL and RANVIER, *Man. Path. Hist.* vol. I.; WIEGER, *Virch. Arch.* vol. 78; PETERS, *Virch. Arch.* vol. 87; VALLAT, *Virch. Arch.* vol. 89; VIRCHOW, *ibid.* vols. 85, 89.

333. Fatty degeneration, calcification, and necrosis of the lymphatic glands occur mainly as consequences of inflammatory disease. Fatty change and soft caseous necrosis are best exemplified in connection with the specific inflammations of scrofula and tuberculosis. A lymphatic gland already altered or enlarged, and it may be pigmented, exhibits on section one or more isolated caseous foci, or is transformed entire into an opaque white cheesy mass contained in a fibrous capsule. In later stages such glands may take up fluid and become diffuent or liquefied, or they may become calcareous.

The second or firm variety of caseous necrosis begins as a homogeneous degeneration. It occurs mainly in hyperplastic (Art. 340) and tuberculous (Art. 342) glands, which often have a glassy or translucent appearance even to the naked eye. The process is found on examination to start in a uniform or homogeneous transformation of the entire tissue,

or of single cells in it, which take the form of shining flakes or lumps and gradually lose their nuclei. If the tissue so changed passes on into the soft variety of caseation, it breaks up into a granular friable mass.

Necrotic patches, made up of grayish friable moist tissue, are formed in the glands generally after acute inflammatory swelling, such as often accompanies typhoid fever and diphtheria. The lymphoid cells are

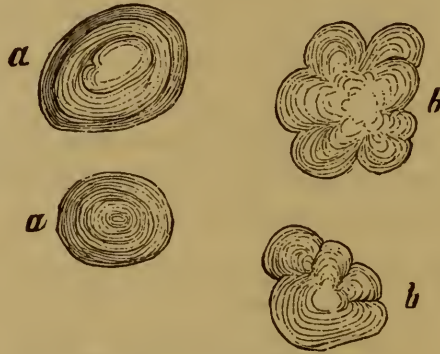

FIG. 134. CHALKY CONCRETIONS.

a, from an inflamed omentum.

b, from a tuberculous lymphatic gland.

partially transformed into pale denucleated lumps, which speedily disintegrate.

Such patches may go on to gangrenous putrefaction; or losing fluid may become condensed and cheesy-looking. In the latter case calcification often follows, and the entire gland may be transformed into a chalky or mortar-like mass.

Stratified concretions (Fig. 134 *b*) not infrequently take the place of diffuse calcareous deposits. They are especially common in connection with tuberculous disease.

CHAPTER XXVII.

FOREIGN SUBSTANCES IN THE LYMPHATIC GLANDS.

334. Minutely divided **foreign substances** which have gained access to the lymphatic vessels are intercepted and retained for a longer or shorter time in the glands. Thus after hæmorrhage into the tissues the red corpuscles or their remains are conveyed to the glands, and deposited there within the carrier-cells.

At first these carrier-cells with the corpuscles or pigment (hydrated ferrous oxide, Art. 268) they contain are met with mainly in the sinuses (Fig. 135); but afterwards they enter the follicles. Occasionally the deposit may be so large that the proper structure of the gland is obscured by it. The appearance of the gland is altered greatly, and it may be stained dark brownish-red or russet, so as occasionally to recall the look of the spleen-pulp, especially when the coloring-matter of the blood in solution passes into its substance as well as the insoluble pigment.

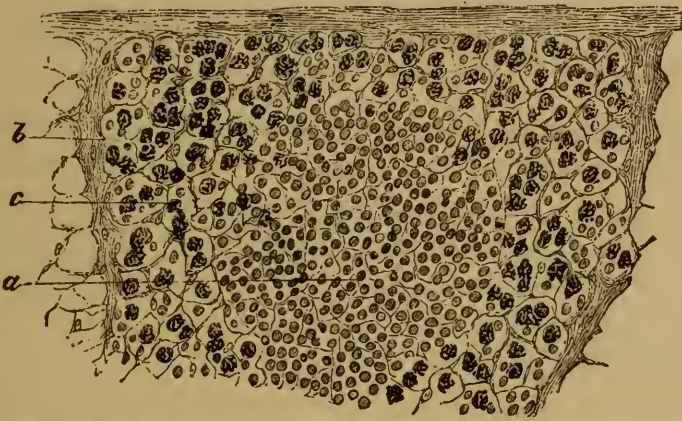


FIG. 135. SECTION OF A LYMPHATIC GLAND CONTAINING PIGMENT-GRANULE CELLS.

(*Carmine staining*: $\times 80$.)

a, follicle.

b, trabeculæ.

c, pigment-granule cells.

Other substances may in like manner be retained in the glands, and if they have any proper color the gland of course becomes pigmented. The most familiar instance is the gray or black pigmentation of the bronchial glands by matters inhaled with the air as dust. When blue or red colors have been used in tattooing the skin, the glands which receive the corresponding lymphatics are often found after a time to contain some of the insoluble pigment.

See VIRCHOW (*Cellular-pathologie* 4th ed. p. 224, *Virch. Arch.* vol. 35), BILLROTH (*Beiträge z. path. Hist.* (1858) p. 135, *Virch. Arch.* vol. 21), REBSAMEN (*Virch. Arch.* vol. 24), ORTH (*Virch. Arch.* vol. 61), HINDENLANG (*Virch. Arch.* vol. 79), SOYKA (*Prag. med. Woch.* 1878), VON INS (*Arch. f. exp. Path.* v.) KELSCH (*Arch. de physiol.* 1875).

335. The **consequences of foreign deposit** in the glands depend on its amount and on its physico-chemical nature. Many substances, such as calcium carbonate, are dissolved; others like coal-dust, stone-dust, or cinnabar remain and lead to permanent pigmentation. They lie enclosed in lymphoid cells (Fig. 136 *c*), or lodged in the reticulum and trabeculæ. If the amount present is small the changes induced are

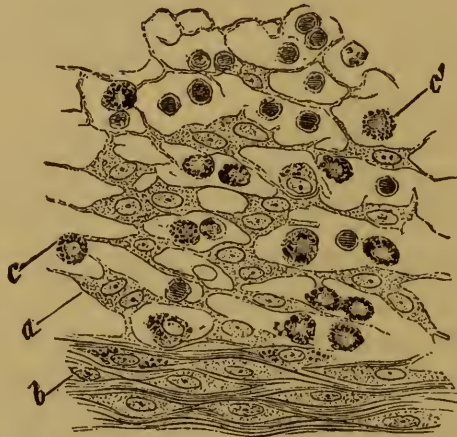

FIG. 136. SECTION OF A SLATE-COLORED BRONCHIAL GLAND.
(*Carmin staining* : $\times 250$.)

a, reticulum of large cells. *b*, fibrillated connective tissue,
c c', pigment-carrying cells.

trifling; larger amounts lead to the shrinking of the gland. The lymphoid elements dwindle and disappear, while the meshes of the reticulum become filled with pigment-carrying cells (Fig. 136 *c* and *c'*) and free pigment. The reticulum may be unaltered, or in part hyperplastic (*a*), in which case it is made up of juicy branching and anastomosing cells. Dense fibrillated connective tissue (*b*) is often formed in places, and this too contains pigment.

Chemically active substances have of course a very different effect, as also such living micro-organisms as may reach the glands. They usually set up more or less violent inflammation, and not infrequently lead to necrosis.

CHAPTER XXVIII.

INFLAMMATIONS OF LYMPHATIC GLANDS.

336. **Acute lymphadenitis.** Acute inflammation of the lymphatic glands is usually set up by irritants brought to them by the lymph. In many cases the irritant can be proved to be bacterial, in other instances its nature cannot be ascertained. An inflamed gland is swollen, and often greatly swollen. On section it appears red, and moister and softer than usual, and it often contains hæmorrhagic patches. The abnormal redness may be confined to the cortex, or extend also to the medulla. During the later stages the redness decreases again; and the section becomes mottled, or uniformly grayish, yellowish, or white. The condition of the tissue varies with these changes of tint. Where it is red, the blood-vessels are dilated and distended with blood; the reticulum both without and within the follicles being likewise distended with cells and liquid, while red corpuscles are often found lying free in the parenchyma. Where the tissue is pale, the accumulation of colorless cells has gone on, while the hyperæmia has diminished. The reticulum is seldom notably altered at first, but as the inflammation proceeds it usually breaks down here and there. The number of glands affected by the same inflammation varies much; sometimes a single one, sometimes an entire group, is attacked.

It is difficult to determine with certainty the source of the leucocytes which gather in the reticulum of an inflamed lymphatic gland. The lymphoid cells of the follicles normally multiply by subdivision, and it is possible that in inflammatory conditions the multiplication may be increased. But we cannot exclude the possibility that part at least of the intruding leucocytes are derived from the lymphatics or blood-vessels.

337. The further stages and **terminations** of the acute inflammation are different in different cases. It may end in resolution and complete restoration, or in necrosis, gangrene, caseation, suppuration, or fibrous induration. But before reaching such terminations certain changes pass over the lymphoid elements. Many become fatty and break up into mere lumps of detritus; others undergo coagulative necrosis and change into pale turbid denucleated masses, or into granular flakes of fibrin. Others again are enlarged as if by dropsical swelling; or take on the appearance of formative or fibroblastic cells, being large and granular and having bright vesicular nuclei containing nucleoli.

Then there are large cells containing within them other lymphoid cells or red corpuscles or fragments of these, and incorrectly called 'brood-cells.' Lastly there are numbers of pus-corpuscles, with their nuclei broken into two or more fragments. These changes, only recognizable with the aid of the microscope, are variously combined in different cases; they are followed by the more obvious transformations.

When **resolution** occurs the altered leucocytes are re-absorbed and disappear. The gland becomes flaccid, and again appears hyperæmic; it then gradually resumes its normal condition. In **suppuration** patches of yellowish-white softening appear, and the tissue within them breaks down and liquefies. Not infrequently the entire gland breaks down in like manner forming what is called a **suppurating bubo**, and the inflammatory process then attacks the neighboring tissues. If the gland is near the surface of the skin redness and swelling are observed over the site of the bubo. The suppurating gland may then break into the surrounding tissue, or outwardly if it be superficial. In other instances the pus is partly absorbed, and the rest becomes condensed into a caseous mass. In both cases plastic inflammation is induced round the seat of suppuration; and fibrous tissue is developed round the remaining portions of the gland, if there be any, thus leading to induration; or round the caseous residue, which is thereby encapsuled. When the gland becomes **necrosed**, parts or the whole of the gland die outright, take on a dull gray tint, and become very friable or 'rotten.' If **putrefaction** follows, the tissue becomes dirty, foul-smelling; and semi-liquid. When the tissue was before highly hyperæmic or saturated with extravasated blood, the color of the necrosed gland may be slaty or even black. Necrotic and putrefactive processes of this kind of course set up inflammatory and destructive change in the surrounding tissues. The obliteration and **induration** of the gland require longer time. They are the result of defective reproduction of the lymphoid elements and excessive production and substitution of fibrous tissue, and properly come under the head of chronic inflammation (Arts. 338-341). **Caseation** likewise belongs strictly to the domain of the chronic inflammatory processes.

338. Chronic lymphadenitis. The chronic inflammations of lymphatic glands are in general accompanied by increase of their bulk, due to the formation in them of new cellular tissue. This tissue is generally very unstable and reaches only the lowest stage of organization; it is indeed scarcely correct to describe it as tissue at all. Less often it becomes more fully developed, and then it is more permanent in its character. Its structure usually bears little resemblance to that of normal lymphoid tissue, and often is so like neoplastic or tumor tissue that it is difficult for the histologist to be sure whether an enlarged lymphatic gland is really a tumor or merely a hyperplasia. The diagnosis in such cases depends much more on the clinical facts than on the structural appearances.

The tumor-like enlargements of the glands met with in chronic lymph-

adenitis are divisible into four groups according to their histological structure: (1) small-celled hyperplasia with a tendency to caseation or suppuration, commonly described as scrofulous lymphadenitis; (2) large-celled indurative hyperplasia; (3) trabecular or reticular indurative hyperplasia; (4) tuberculous enlargement.

Clinically all these varieties are referred to as **lymphoma**.

339. Scrofulous lymphadenitis, or small-celled hyperplasia of the lymphatic glands, is closely related to ordinary acute lymphadenitis and is in fact often a terminal stage of an acute inflammation, though it generally runs throughout a subacute or chronic course. The glands swell to a considerable size. Sometimes a single one is affected, sometimes an entire group such as the cervical or mesenteric glands.

At first the glands are soft and grayish on section; then caseous foci develop, or the whole gland is changed into an opaque white cheesy mass, which may be dry or pulpy or creamy according to the amount of water present. The tissue surrounding the caseous foci is in the early stages soft and grayish, consisting of lymphadenoid tissue infiltrated with inflammatory products; afterwards though still cellular it appears denser and firmer and contains a considerable amount of fibrous tissue. The capsule of the gland is especially liable to be thickened.

In the early stages the chief microscopic change which appears is the great accumulation of small leucocytes in the meshes of the adenoid reticulum. Few larger cells are visible, though cases differ in this respect. Sometimes a number of epithelioid cells are developed, and are aggregated in clusters; and now and then giant-cells appear. The reticulum itself seems little altered at first; but later on it breaks down here and there. When necrosis or caseation sets in the usual degenerative metamorphoses are visible; the cellular tissue is replaced by a mass of detritus, and only the nuclei at the margins where the dead tissue passes into the living can be brought out by staining reagents. In recent specimens this marginal zone is seen to contain numbers of fatty cells and pale coagulated masses. Occasionally the necrotic disintegration is preceded over a greater or less extent by uniform homogeneous degeneration.

340. Large-celled indurative hyperplasia of the lymphatic glands is distinguished by the transformation of the normal gland-tissue into a large-celled tissue having none of the characters of the original structure. The large-celled tissue consists in part of close-packed rounded or polygonal cells (Fig. 137 *b*), and in part of spindle-cells. There is but little intercellular substance, though in some spots distinct patches of fibrous tissue are seen. If the proper lymphadenoid tissue has not entirely disappeared, the remaining portions of it form reticulated bands (*a*) pervading the large-celled tissue. The latter stains less deeply than the small cells of the normal lymphadenoid tissue.

The process of transformation begins with an accumulation of leucocytes in the gland-tissue, followed by the development of epithelioid cells

with large nuclei. Only a few patches are formed at first, and these are chiefly confined to the follicles and trabeculæ, though they are also found in the lymph-sinuses. The development of the large cells can always be made apparent in sections by the use of staining reagents. The scattered patches then unite into more or less extensive ones, though at times the fusion is incomplete and the gland seems made up of isolated groups of large-celled nodules. We may thus distinguish a diffuse and a nodular variety of large-celled hyperplasia. The latter very much resembles tuberculous change, and the resemblance is occasionally increased by the occurrence of giant-cells within the nodules (Art. 342).

Hyperplastic glands of the kind described feel firm and dense, and may reach the size of a pigeon's egg, or even of a small hen's egg. The section looks uniformly grayish and somewhat translucent; after exposure

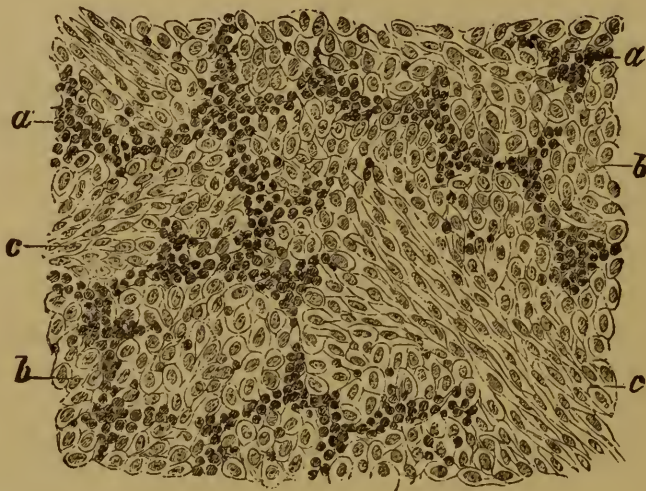


FIG. 137. LARGE-CELLED HYPERPLASIA OF A LYMPHATIC GLAND.

(Carminic staining $\times 150$.)

a, remnants of lymphadenoid tissue.

b, large celled tissue.

c, spindle-celled tissue.

to the air it becomes brownish. Little fluid can be obtained from it by scraping. In the nodular form of the affection the nodules stand out from the surrounding tissue by virtue of their tint and translucency. Soft caseation does not usually follow upon large-celled hyperplasia, but homogeneous or hyaline degeneration is common; it leads to the entire destruction of the cells, and must be reckoned as a form of firm caseation (Art. 39). The tissue becomes homogeneous and shining and loses its nuclei, or seems broken up into hyaline denucleated blocks. Now and again this stage passes into one of complete disintegration with granular crumbling of the tissue, not unlike soft caseation.

341. Fibrous indurative hyperplasia. Hyperplasia of the adenoid reticulum has already been referred to (Art. 335) in speaking of the consequences of long-continued deposition of foreign substances in the glands. The increase of fibrous tissue in such cases is however but slight, when

compared with the very notable fibrous hyperplasia which may result from chronic or often-repeated inflammation, and which may lead not merely to induration but to great increase in the size of the gland. The swellings thus produced may reach the size of a hen's egg, or more.

The capsule and fibrous septa are in general the parts most thickened and enlarged, or at least the more diffuse hyperplasia starts with them. The hyperplasia being thus due to the formation of new fibrous tissue, the affection is best described as a fibrous hyperplasia (or '**elephantiasis**') of the gland, and we may distinguish the **trabecular** or interstitial from the diffuse or **reticular** variety. The most typical examples are found in cases of elephantiasis of the skin and subcutaneous tissue. When the change has originated in the capsule or septa, the section of the gland is seen to be surrounded by a broad zone of fibrous tissue, and the grayish parenchyma is pervaded by lustrous white fibrous bands.

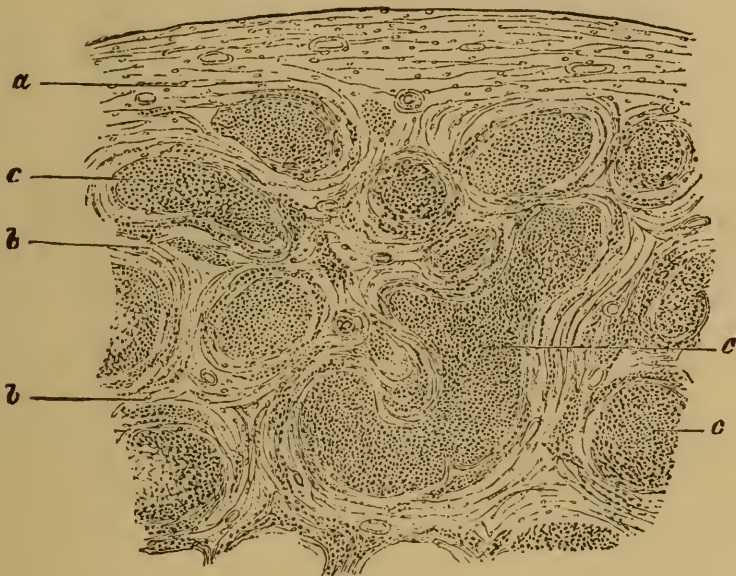


FIG. 138. FIBROUS HYPERPLASIA OF A LYMPHATIC GLAND.

(*Hæmatoxylin* staining: $\times 25$.)

a, thickened capsule.

b, fibrous bands pervading the gland.

c, isolated remnants of gland-tissue.

pressed by glands the fibrous framework is always greatly increased in proportion to the rest of the tissue; the fibrous septa and sheaths of the vessels become thick fibrous cords (Fig. 138 b), and the essential parenchyma is reduced to isolated patches (c) scattered through the gland, and compressed by the fibrous overgrowth.

When the hyperplasia is more generally diffused, the gland on section has a uniform light-gray tint and is uniformly dense and firm.

342. **Tuberculous lymphadenitis** is a very common and a very noteworthy affection. The tuberculous bacillus usually reaches the glands by way of the lymphatics; and as it sets up tuberculous disease at its point of entrance into the body, the affection of the glands is what we

usually speak of as secondary. But cases occur in which the initial affection is slight or transient, and so may escape notice altogether; while the glandular affection appears to be primary. Thus we meet with tuberculous cervical glands in patients who show no signs of tuberculous or even of inflammatory disorder at any of the possible points of entrance of the virus—conjunctiva, nose, tonsils, pharynx, ear, etc.

Tuberculous glands are often greatly enlarged, and are firm and fleshy in texture; the section being light grayish-red, or white, or yellow. The separate tubercles are only to be made out by close examination, or with the aid of a lens; they form small grayish-white translucent nodules. When they become caseous and so turn to an opaque yellowish-white, they are more easily detected. Sometimes the tissue is on the whole more

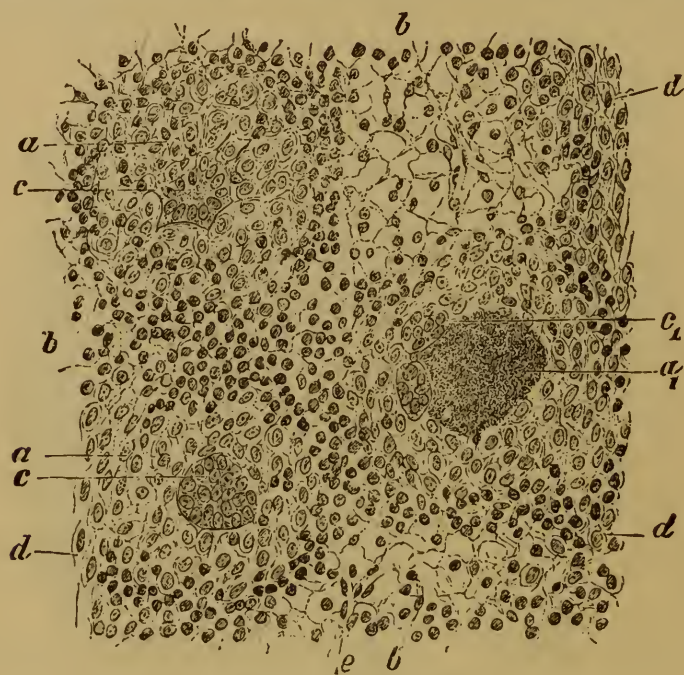


FIG. 139. TUBERCULOSIS OF A LYMPHATIC GLAND.

a, fresh tubercle.

*a*₁, caseous tubercle.

b, lymphadenoid tissue.

c, giant cell in the centre of a tubercle.

*c*₁, giant-cell at the border of a caseous focus.

d, large-celled lymphadenoid tissue outside the tubercles.

e, lymphoid cells.

soft and juicy, and gray or grayish-red; the tubercles appearing as light-gray or opaque white nodules, or aggregated into larger caseous foci. Now and then no tubercles can be seen by the naked eye at all, and it may even be that the appearance of the gland generally is altogether normal. Tuberculous glands from the root of the lung are usually pigmented, and not infrequently indurated also.

The number of tubercles present may of course vary greatly; it is often very large, and the individual tubercles have a perfectly typical appearance. The giant-cells of tubercle (Fig. 139 *c*) especially can be well studied in such glands.

The formation of a tubercle begins with an accumulation of small

leucocytes in the follicles and alveoli; and epithelioid cells with large nuclei are then developed out of the leucocytes. In stained preparations this transformation is manifested by the appearance of the youngest tubercles as clear spots surrounded by a zone of deeply-tinted leucocytes (Fig. 139 *a*). Giant cells (*c*) sooner or later appear; and ultimately the tubercle becomes caseous, the central parts becoming homogeneous and denucleated and breaking up into granular detritus. More rarely the caseation precedes the formation of the large cells; or the process may end with the stage of homogeneous change (Art. 333).

The region outside the tubercle is often infiltrated with small cells, the infiltration extending as far as the sinuses, the capsule, or the fibrous tissues of the hilum. The reticulum is either unaltered or slightly thickened, its cells seeming to be somewhat swollen. Or a large-celled hyperplasia of the lymphadenoid tissue (Fig. 139 *d*) takes place in patches outside the tubercles, in some cases leading to the formation of coarse fibrous tissue. The latter occurs chiefly in chronic tuberculous disease.

The glands most commonly affected with tuberculosis are those of the mesentery, the root of the lung, and the neck: the other glands become tuberculous much less frequently.

The actual frequency of tuberculosis of the lymphatic glands is not easily determined by mere anatomical investigation, for it is often very difficult to decide whether a given glandular affection is tuberculous or not. The large-celled hyperplasias (Art. 340) have in the above account been separated from the tuberculous affections; but it is not unlikely that tuberculosis may assume the former type, and that some of the so-called scrofulous inflammations of the glands in which no typical tubercles can be found are really due to the invasion of the tuberculous virus. In future we shall no doubt be able to settle such questions in any given case either by demonstrating the presence or absence of the *Bacillus tuberculosis*, or by testing the infective character of the morbid material by means of inoculation. Tuberculous lymphadenitis is apparently a very common affection, and occurs in patients otherwise free from tuberculosis; that is to say, it may remain as a purely local affection.

See SCHÜPPEL (*Die Lymphdrüsentuberculose*, Tübingen 1871), CORNIL (*Journ. de l'anat. norm. et path.* 1878), J. ARNOLD (*Virch. Arch.* vol. 87), BAUMGARTEN (*Samm. klin. Vorträge* 218), TREVES (*Scrofula and its gland diseases*, London 1882), BERGMANN (*Gerhardt's Handb. d. Kinderkr.* VI.), ORTH (*Lehrb. d. spec. path. Anat.* I.).

Syphilitic inflammation of the lymphatic glands (**hard bubo**) possesses no distinctive histological characters. The accumulation of leucocytes in the follicles, alveoli, and sinuses is usually considerable, and the capsule and tissue of the hilum are also infiltrated with cells.

CHAPTER XXIX.

TUMORS OF LYMPHATIC GLANDS.

343. The non-inflammatory tumors of the lymphatic glands fall into two main groups, according to their histological structure. The first group includes all growths whose general type is that of normal lymphadenoid tissue; the second includes those in which the normal tissue is displaced by tissue of a different kind. The tumors of the first group are variously known as lymphomata, lymphadenomata or adenomata simply, and lymphosarcomata; those of the second group are chiefly sarcomata. The former are homœoplastic, the second heteroplastic growths (Art. 138). It is not always easy to determine whether a given glandular growth, homœoplastic or heteroplastic, is to be reckoned as a true tumor in the stricter sense of the term. Many of the homœoplastic formations have the anatomical characters of hyperplasia, rather than of neoplasm. And these characters are to some extent borne out by the fact that the function of the gland often becomes more active as its growth increases, that is to say a larger number of white corpuscles are contributed by it to the blood (**leukæmic lymphoma**). On the other hand there are cases in which glandular growths of like structure exhibit the clinical characters of tumors, that is to say they form metastases and induce cachexia (**malignant lymphoma**); and the cachexia—taking the form of emaciation, dropsy, coma, delirium, etc.—may result in death.

Owing to the difficulty of distinguishing neoplasm from hyperplasia, we shall in what follows describe all the glandular growths under the general head of tumors, classifying them according to their structure.

It is highly probable that closer investigation of the development of the glandular tumors will make it possible to distinguish the various forms more accurately than we are at present able to do. We are now unable to give any explanation of the fact that of two cases of lymphoma which are histologically identical, one should involve alteration in the blood, and the other should not. And we know as little the reason why one lymphoma should continue to be a purely local affection, and another of the same texture should lead to metastatic infection of other groups of glands or of organs which normally contain no gland-tissue.

KLEBS has suggested that leukæmic lymphoma may be an infective disorder due to an extraneous virus, and he has therefore classed it with the infective granulomata. This view has much in its favor, but we are at present unable to advance any definite proofs of its correctness.

References:—Art. 328; VIRCHOW, *Krankhafte Geschwülste*. II.; WUNDERLICH,

Arch. d. Heilk. VII.; MURCHISON, *Path. Soc. Trans.* 1870; LANGHANS, *Virch. Arch.* vol. 54; POTAIN, *Dict. encyc. d. sciences méd.* (2d ser. 1870) vol. III.; HUMBERT, *Des néoplasmes des gang. lymphatiques* Paris 1878; VON WINIWARTER, *Arch. f. klin. Chir.* XVIII.

344. **Soft lymphadenoma** or lymphosarcoma is a soft almost fluctuating or diffuent growth, with a light-gray or grayish-white or grayish-red tint on section. It is sometimes speckled with small red islets corresponding to dilated vessels or small extravasations. An abundant turbid juice comes from the section when scraped. The tissue surrounding the gland is not usually altered, though sometimes neighboring glands cohere and coalesce into a single mass. Sometimes caseous patches occur within the growth. The juice consists of small leucocytes, mingled with a few larger and often multinuclear cells, spindle-cells from the walls of the vessels, red corpuscles, and free nuclei.

When examined with the microscope the follicles are seen to be greatly enlarged, the fibrous parts of the medullary tissue have disappeared, and the whole section of the gland has become like the cortex. In pencilled sections the reticulum is seen to be thickened; it has nuclei at its nodal points, and includes a multitude of lymphoid elements. The growth is thus due to a development of tissue similar to that of the normal gland-follicles.

The affection extends in some cases only to one or two glands, in others to whole groups. Other parts of the lymphatic system are very often affected at the same time, especially the malpighian follicles of the spleen and the lymphadenoid tissue of the alimentary canal, as it exists for example in the follicles of the tongue, the stomach, and the intestine. In young patients the thymus may likewise be affected. But lymphadenoma may also develop in parts which normally contain no lymphadenoid tissue, such as the bones, liver, kidneys, ovaries, etc.

The behavior of the blood varies, and two varieties of the disease are distinguished accordingly. In many cases no change can be detected, or only a diminution in the amount of blood. This variety is called by various names such as **Hodgkin's disease** (from its first describer), adenia (Trousseau), lymphosarcoma in a restricted sense (Virchow), malignant lymphoma (Billroth), and pseudoleukæmia (Cohnheim). In the second variety the white corpuscles of the blood are increased in number (leukæmia). The growth is then described as **leukæmic lymphoma** or leukæmic lymphadenoma. The examination of the blood suffices to distinguish the varieties; in other respects the affections are identical. (On the changes in the blood see Art. 260; on those in the spleen see Art. 328.)

The leukæmic increase of the white blood-cells very often leads to considerable deposits of them in the various tissues. The deposits may be diffuse or in agglomerated masses, and must not be confounded with the lymphadenoid growths.

LANGHANS (*Virch. Arch.* vol. 54) has proposed to call both varieties by the one name of **adenia**, distinguishing them as simple adenia and leukæmic adenia. Some such distinction would be better than the present confusion. We do not know the ultimate cause of the difference between the two varieties; cases are known in which the simple form has passed into the leukæmic, and inversely.

The spleen is affected in both forms. In simple or non-leukæmic cases it is sometimes firm, sometimes soft, the follicles are enlarged to the size of a hazelnut, and are grayish-yellow, vascular, and ecchymosed. It is rare for the spleen to be more intensely affected than the glands; while in leukæmic adenia the affection of the spleen is often the most marked feature of all.

References:—Arts. 260 and 328; CORNIL, *Arch. gén.* II. (1865) p. 207; COHNHEIM, *Virch. Arch.* vol. 33; HODGKIN, *Med. chir. Trans.* XVII. (1832); EBERTH, *Virch. Arch.* vol. 49; B. SCHULZ, *Arch. d. Heilk.* 1874.

345. **Hard lymphadenoma** or lymphosarcoma occurs as a primary growth most frequently in the superficial lymphatic glands; other groups may be attacked in the further course of the affection. For example, if the affection start in some of the cervical glands, the rest of the cervical glands, and the thoracic and abdominal glands lying near the large vessels, are attacked in succession. The glands are transformed into firm tough elastic or hardened knots, forming dense clusters in combination. Single glands may reach the size of a walnut.

The section of such a knot becomes very slightly concave, and but little juice runs from it; it looks pale yellowish-white, and may be translucent or opaque; sometimes small hæmorrhages appear in it. The capsule and surrounding tissue seldom exhibit any great degree of fibrous thickening.

On microscopic examination the lymphadenoid structure is seen to be preserved (LANGHANS), while the cells are increased in number and the reticulum is thickened. The cells resemble the ordinary lymphoid elements, a few being larger or multinuclear. The strands of the reticulum are broad and fibrillated, and they seem multiplied so that the network is closer and its meshes smaller than in a normal gland. The follicles and sinuses are no longer distinguishable. The adventitia of the vessels is thickened and is made up of shining fibrous bundles. Fatty degeneration, calcification, or softening rarely supervene. In later stages the follicles of the spleen may be affected, and be changed like the glands into hard nodules. The spleen is never primarily affected in this form of lymphadenoma. Similar nodules may be developed in the lymphadenoid tissue of the alimentary canal and in the thymus. Metastatic growths occasionally appear in the liver, kidneys, lungs, etc. Leukæmia does not accompany this affection.

Certain transitional varieties between hard and soft lymphadenoma have been described.

346. **Sarcoma** of the lymphatic glands is a somewhat uncommon affection. It occurs in single glands, or several of the same group are simultaneously affected and cohere into a nodular tumor. It often over-

passes the limits of the gland and invades the adjoining tissues. Secondary growths are usually developed. Small-round-celled sarcoma, spindle-celled sarcoma, fibro-sarcoma, and alveolar sarcoma or alveolar angiosarcoma, are all forms which occur. The latter form has a somewhat carcinoma-like structure, the epithelioid cells being grouped in clusters within an alveolar stroma.

It appears that the neoplasm may start in various parts of the gland-tissue. According to PUTIATA alveolar sarcoma begins in the tissue around the vessels. In other instances, especially in spindle-celled sarcoma, the connective-tissue framework is the primary seat of neoplastic proliferation (WINIWARTER). Some authors, like PUTIATA, maintain that the lymphoid elements may be transformed into tumor-cells.

See LANGENBECK (*Deutsche Klinik* 47, 1860), BILLROTH (*Beiträge z. path. Hist.* Berlin 1858), PUTIATA (*Ueb. Sarcom. der Lymphdrüsen, Virch. Arch.* vol. 69), VON WINIWARTER (*Arch. f. klin. Chir.* XVIII.), VAILLARD (*Revue de méd.* 1882).

347. Secondary growths. All the forms of tumor which give rise to metastases may affect the lymphatic glands. Cancers especially are apt to do so, and the glands become enlarged and altered as the disease advances. On section they have a white marrowy look, and cancer-juice can be obtained from them by scraping. The altered glands have not always the same appearance, any more than the primary tumor from which they are derived. Indeed the typical structure of the parent tumor is often very beautifully reproduced in the infected gland. The secondary growths likewise pass through the same series of changes as the parent tumor (Art. 174).

The gland-tissue is compressed and displaced by the cancerous growth. The cancer-germs brought to the gland in the first instance by the lymphatics begin to germinate in the sinuses. Cancer-nests are then formed, and the stroma of the tumor is developed out of the lymphadenoid tissue. In its first stages the cancerous change is often not apparent to the naked eye, and must be searched for with the microscope. Sometimes even the more advanced changes are not to be made out in fresh specimens without minute examination.

Sarcomatous metastases, like the carcinomatous, may originate in sarcoma-cells which have entered the gland through the lymphatic vessels.

SECTION IV.

THE SEROUS MEMBRANES.



CHAPTER XXX.

DEVELOPMENT OF THE SEROUS CAVITIES.

348. The **primitive body-cavity** is a large undivided space interposed between the alimentary tract and the body-wall, and shut off in all directions from the blood-vessels (HERTWIGS). Until recently it was held that the body-cavity was directly connected with the vascular system; HAECKEL indeed taught that it was originally in itself the first rudiment of a vascular system. But embryological research has now shown that this view is untenable. The blood-vessels and lymphatics arise independently of the body-cavity as excavations in the substance of the mesoblast, due to partial liquefaction of the tissue and the transformation of some of the cells into blood-corpuscles. The body-cavity on the other hand is originally a part of the primitive alimentary cavity or archenteron. Two lateral diverticula of this are formed and gradually abstricted from the central cavity which persists as the ultimate alimentary tract. These diverticula then converge ventrally and coalesce to form one cavity, the ultimate body-cavity; and this surrounds the alimentary tract except dorsally, where the primitive dorsal septum between the diverticula persists as the mesentery. The connection ultimately existing between the lymphatic system and the body-cavity are later and secondary developments (HERTWIGS and BALFOUR).

The mode of origin of the body-cavity indicates the true nature of its lining membrane. The cavity not being a mere lymph-space, like the sac of the arachnoid, is clothed not with endothelium but with an **epithelium** derived originally from the hypoblast. Under this single layer of epithelium lies a layer of connective tissue richly provided with blood-vessels and lymphatics, which latter communicate freely with the body-cavity through a multitude of ostia or **stomata**. The membrane formed by the layer of cells and the layer of connective tissue is known as a **serous membrane**; and, after the differentiation of the general body-cavity, as peritoneum, pleura, or pericardium, as the case may be.

This account of the origin of the vertebrate body-cavity has a pathological as well as an embryological bearing. If the cavity is not a mere lymph-space, its pathology is not strictly comparable with that of the lymphatic system. If its epithelial covering is originally derived from the alimentary or splanchnic epithelium its morbid changes will be related to those of the mucous membranes, and must be studied in con-

nection with them. Thus, for example, it may be important in discussing the genesis of neoplasms occurring in a serous membrane to bear in mind that its so-called endothelium is genetically a true epithelium.

Few affections of the serous membranes are independent or confined to them alone. Various organs are enclosed within the body-cavities and are thus in the closest relation to the serous membrane. The disorders affecting the membrane are consequently in the greater number of cases secondary to affections of the organs which it covers. These secondary affections will be discussed in treating of the respective organs; in the following chapters we shall deal chiefly with the primary or independent affections of the serous membranes.

The above account of the origin of the body-cavity differs essentially from that given in the first German edition, in which the widely-accepted view which regards the pleuro-peritoneal cavity as a mere lymph-space was adopted. The works of the HERTWIGS (*Die Coelomtheorie* Jena 1881) and BALFOUR (*Comparative Embryology* vol. II. ch. 13) have shed new light upon the subject; and though they differ in details the main fact of the derivation of the body-cavity from the primitive alimentary cavity seems established by them.

The fact that the serous membranes are capable of performing secretory functions seems to harmonize with the theory that they are originally derived from the secretory layer of the blastoderm, the hypoblast.

CHAPTER XXXI.

EFFECTS DUE TO DISORDERS OF THE CIRCULATION.

349. Disorders of the circulation affecting the serous membranes are very common.

Congestive hyperæmia such as accompanies the early stages of inflammation, and sudden diminution of the normal pressure within the serous cavity, may lead to intense reddening of the surface of the membrane. In passive hyperæmia it is the veins especially which are engorged, and often notably dilated.

Small circumscribed **hæmorrhages** are very commonly met with, both in inflammation and in fatal cases of infective disease, renal and cardiac disease, asphyxia, etc. When fresh they are red, but after a time they become brown or slate-colored. They are due either to alterations in the vessel-walls, or to extreme vascular engorgement with obstruction, or to both together.

Large hæmorrhages, in which blood escapes in quantity into the cavity, may result from very various causes. They are frequently due to mechanical injury by which a large vessel is opened, as in ruptures of the liver, kidney, spleen, lung, etc. Such are also the grave hæmorrhages that follow rupture of the heart or aorta or other artery depending on disease, and rupture of the foetal sac in tubal pregnancy. Sometimes no lesion can be made out, as in cases of hæmorrhagic diathesis. New-formed vessels in inflammatory tissue are especially apt to give way and bleed. Lastly, extreme engorgement such as ensues on thrombosis of the portal vein, or embolic occlusion of an artery, may cause very severe hæmorrhage.

The blood poured out into the serous cavity is quickly absorbed by the lymphatics which communicate with the cavity, unless special morbid alterations of the membrane stand in the way. Blood which remains liquid is very speedily taken up, in part without much alteration, and in part after solution or decolorization of the red corpuscles. Coagula are less manageable, but they too are ultimately absorbed. Extravasations in the membrane itself or in the subserous tissue are dealt with in the manner described in Arts. 112-116. As the blood disintegrates, either before or after its complete absorption, urobilinuria or hæmoglobinuria is observed.

VON RECKLINGHAUSEN (*Virch. Arch.* vol. 26) was the first to investigate with success the process of absorption of foreign substances (such as milk, tinted liquids, and blood) in the abdominal cavity. PONFICK (*Virch. Arch.* vol. 48) and CORDUA (*Ueber d. Resorp. von Blutergüssen* Berlin 1877) have made out certain further details. They injected fibrinous or defibrinated blood into the abdominal cavity, and found that the defibrinated blood was very rapidly taken up, and that almost without alteration. This observation has a practical value, for it suggests the possibility in the human subject of successful transfusion of defibrinated blood into the abdomen instead of into a blood-vessel. The blood-cells so absorbed survive when they reach the circulating blood.

Unchanged blood when injected into the abdominal cavity is much less readily absorbed, as clots form which become aggregated into considerable masses. These by their close contact with the serous membrane set up inflammation, are fixed down by exudations, and receive a covering of migratory cells. Large formative cells with an abundant protoplasm then appear on the surface of the clot. They are developed from the white blood-cells, and presently lead to the formation of new fibrous tissue, while new vessels are produced by off-shoots from the vessels of the serous membrane. Meanwhile the inner parts of the clot are disintegrating and dissolving. The red corpuscles are changed to grains of pigment or are taken up by carrier-cells (Art. 68), or give up their coloring matter which is deposited in the form of blood-crystals, while the albuminous detritus is absorbed.

Other matters capable of absorption, such as recent dead tissue, and to some extent tissue hardened in alcohol, are dealt with in like manner. Bodies that cannot be absorbed are usually overlaid with fibrous tissue and so fixed down. If they are altogether insoluble and non-irritating (like glass) they may remain for long in the cavity without setting up any inflammation.

350. Large accumulations of serous fluid in the body-cavities are very frequent. The accumulation is described as **ascites**, **hydropericardium**, or **hydrothorax**, according as it occurs in the abdominal, pericardial, or pleural cavity. The fluid is colorless or pale yellow, clear or opalescent, and sometimes after death it is found to be turbid from the presence of shed epithelium. Sometimes too it contains a few delicate shreds of fibrin. If jaundice is present, the fluid may be bile-stained; if hæmorrhage has occurred it may be blood-stained. If any solution of continuity has occurred in the larger lymphatic vessels of the abdomen, the ascitic fluid may be rendered white and milky-looking by the chyle which escapes (chylous ascites).

The effused fluid is poor in formed elements. Occasionally flakes of shed epithelium are found, in the form of large nucleated granular cells, containing fat-globules or otherwise disintegrating. Lymphoid cells are scanty. Hæmorrhagic effusions contain blood-cells; chylous effusions contain lymphoid cells and fine granules and drops of oil. When a tumor exists in the cavity the effusion may contain tumor-cells, which are usually in a state of fatty or mucoid degeneration. Highly fatty detritus if present in any quantity may give the fluid the look and consistence of whey.

We have already described the conditions under which fluid accumulates in the serous cavities (Arts. 23-25). The main cause of increased

transudation from the vessels is obstruction of the venous outflow, aided by damaged or degenerate conditions of the vessel-walls. Ascites is most commonly due to uncompensated cardiac disease, pulmonary emphysema, or degenerative change in the kidneys. It is also common in liver-disease by which any considerable extent of the portal territory is obstructed, and it often accompanies the development of abdominal tumors. According to QUINCKE (*Deutsch. Arch. f. klin. Med.* xxx.) it may make its appearance in girls about the time of puberty without apparent cause, disappearing as soon as menstruation is established.

The most immediate result of serous effusion is the displacement and compression of the organs it involves. This is very apparent in the case of the lungs, which may be thrust back against the spine by a large pleural effusion. The compression of the heart and abdominal viscera by effusion into their respective serous cavities is less marked, as the pericardium and peritoneum are capable of great distention. But even then serious impairment of the functions of the organs may ensue. Extreme ascites presses up the diaphragm and impedes the breathing; a great pericardial effusion may interfere with the action of the heart, chiefly by impeding the diastolic expansion. If effusion occur simultaneously in the several cavities, the disturbance of the visceral functions may become very grave.

The anatomical changes observable in the serous membranes in dropsical conditions are often very slight. They may be little more than result from the soaking of the serous and subserous tissue; or perhaps the veins may appear more or less dilated. After long-continued dropsy due to engorgement whitish thickenings and fibrous adhesions make their appearance on the surface of the membrane. The former are chiefly due to alterations in the epithelial cells, which are more or less swollen, partially lifted from the fibrous basis-tissue, and in process of desquamation or fatty degeneration. Proliferous cells with an abundant protoplasm and two or more nuclei are also to be met with. The vascular engorgement thus induces catarrh with desquamation and multiplication of the epithelium (Fig. 142). The fibrous tissue is often largely infiltrated with leucocytes, and these may after a time proceed to develop into new fibrous tissue, producing diffuse circumscribed thickenings of the serous membrane, and adhesions of separate parts.

CHAPTER XXXII.

INFLAMMATIONS OF SEROUS MEMBRANES.

351. **Inflammation of the serous membranes** is the most important of the affections to which they are liable. Our knowledge of its nature and general course is now full and complete. We mentioned in Art. 95 that COHNHEIM made his fundamental observations on the process of inflammation by means of experiments on the mesentery of the frog. In the human subject the omentum is very well adapted for microscopical examination, and that even without any special treatment; but

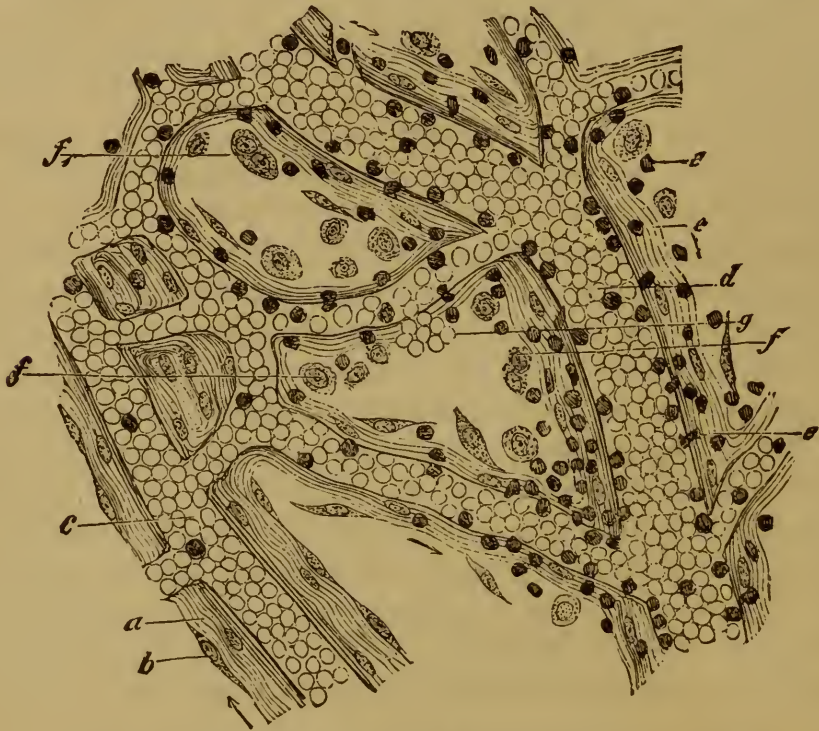

FIG. 140. INFLAMED OMENTUM FROM THE HUMAN SUBJECT ($\times 200$).

a, normal fibrous trabecula.

b, normal epithelium.

c, small artery.

d, vein with colorless blood-cells peripherally disposed.

e, colorless blood-cells migrated or migrating.

f, desquamated epithelium commencing to break down.

*f*₁, multinuclear cell.

g, migrated red blood-cells.

the inflammations of the pericardium and pleura are also easily investigated.

The first stage generally consists in the formation of an exudation

composed of blood-cells (Fig. 140 *e*) and liquid; and this collects in the meshes of the tissue or on its surface, while the epithelium desquamates and disintegrates (*f*). Only when the inflammation is very slight does the epithelium remain intact, or proceed to multiply: when the irritation becomes at all intense and the exudation abundant, the epithelium perishes.

Three chief forms of inflammation are distinguished according to the character of the exudation, namely the fibrinous, the sero-fibrinous, and the purulent. The fibrinous forms are often spoken of as adhesive or plastic, inasmuch as they generally lead to the formation of adhesions and false membranes between the serous surfaces.

352. Fibrinous and sero-fibrinous inflammations. In recent fibrinous inflammation the serous membrane is injected, and its surface turbid and dulled. The dullness appears especially when the surface is wiped; and is essentially due to the deposit of a light grayish or yellowish film of fibrin. If the deposit be at all thick, it may conceal the redness of the injection.

The first fibrinous deposits take the form of minute granular or reticulated masses. The epithelium lying between the little masses is often intact, but it may begin to be shed. In the more intense inflammations the epithelium may be changed into a homogeneous or granular and generally denucleated membrane, that is to say it undergoes coagulative necrosis. Such fibrinous deposits may be unaccompanied by any large amount of liquid exudation. What there is present is rendered turbid by shed epithelium and migrated leucocytes. An inflammation of this kind is often referred to as a '**dry**' inflammation (dry pleurisy, pericarditis, or peritonitis). It frequently results in adhesions of the serous surfaces.

When the exudation is more abundant, liquid is poured out and accumulates in the cavities. The pericardium or pleura becomes notably distended at the expense of the lungs. In the abdomen the liquid gathers first in the dependent parts; but as the effusion increases the organs may be compressed, and the abdominal wall greatly distended.

The proportion of cells and fibrin in the effusion varies greatly. When cells are abundant, the liquid is highly turbid; if red corpuscles have escaped from the vessels the liquid will be more or less reddened, and petechiæ may be observed on the surface of the serous membrane (**hæmorrhagic** inflammation). The fibrin forms threads and curdy flakes, which are translucent and yellowish, or opaque and whitish, according to the proportion of leucocytes they enclose. When very abundant the fibrin is precipitated on the surface of the inflamed membrane and forms a thick adherent layer. The surface of the layer is usually rough and occasionally even villous in appearance, as in the case of the heart (*cor villosum*), or it may take the form of reticulated or lattice-like prominences recalling the look of the reticular stomach of a ruminant.

When the amount of liquid effused is small and the fibrin abundant, thick **false membranes** are formed between the visceral and parietal layers of the serous membrane.

The extent of the inflammation varies much in different cases. In one case only a single patch of the pericardium may be inflamed, and in another the whole surface of a lung.

When the exudation has reached a certain point the inflammatory process ceases and, unless new irritation sets up new inflammation, the process of repair begins. This primarily consists in the **absorption** of the effusion; but it is generally associated with the formation of new fibrous tissue.

The liquid portions are of course the most easily absorbed; but the quickness with which this is effected is not always the same. If the blood-vessels and lymphatics readily resume their functions, the lymphatic channels and stomata being again opened up, the effusion may very speedily disappear. If the mouths of the lymphatics remain closed, the absorption may be very slow indeed.

Fibrin is less readily absorbed; but it is ultimately made more easy of absorption by disintegration and solution. Now and again residues remain unabsorbed, and these usually become calcified. The presence of fibrinous masses which act as dead or foreign bodies and set up renewed inflammation may bring about the development of inflammatory fibrous tissue. From four to six days after the beginning of a fibrinous pleurisy or pericarditis small new-formed vessels can be seen passing from the connective tissue of the serous membrane into the fibrinous masses which overlie it; they are made very apparent if the fibrinous covering is gently peeled off. This is a sign that tissue-formation has begun. In the deeper layers of the fibrinous membrane (Fig. 141) formative cells (*f*) can already be seen, and these are the builders of the future fibrous tissue.

The epicardial tissue (*a*) is beset with a multitude of leucocytes (*d*), the blood-vessels (*c*) are crammed with blood, the lymphatics (*e*) with cells and granular coagula. Leucocytes are aggregated in the meshes of the fibrinous membrane, and from them are developing formative cells (*f*), distinguished by their large transparent vesicular nuclei and their granular protoplasm. They are of various shapes, and form connections with the epicardial tissue and with each other. Fibrous tissue is ultimately developed from their protoplasm, and new vessels very soon arise between them as off-shoots from the epicardial vessels. As the fibrous tissue is gradually elaborated the fibrin disappears.

The consequences of the growth of the new tissue are various. If the amount of it is small, it may simply give rise to a slight thickening of the serous membrane taking the form of a more or less sharply defined lustrous white spot, spoken of as a callosity or **milk-spot**. If the new tissue is more abundant, it may take the form of thick almost cartilagin-

ous *plaques* or patches, or of diffused tendinous or scar-like thickenings.

353. **Plastic pericarditis.** Plastic inflammation of the pericardium is usually an independent affection, but it may be associated with endocarditis and myocarditis, or be the result of pleuritic or mediastinal inflammation.

Slight and localized pericarditis very often gives rise to the formation of the milk-spots just referred to; they may occur in considerable numbers and vary from a few millimetres to some centimetres in diameter. Sometimes the greater part or the whole of the pericardium may be covered with similar white thickenings.

The heart itself may be either free, or involved in adhesions; and these latter may consist of a few thread-like bands stretching from the visceral to the parietal layers, or they may extend over the entire surface, binding the heart everywhere to the parietal layer (*concretio pericardii*). Sometimes the adhesions are brittle and easily broken down; in other

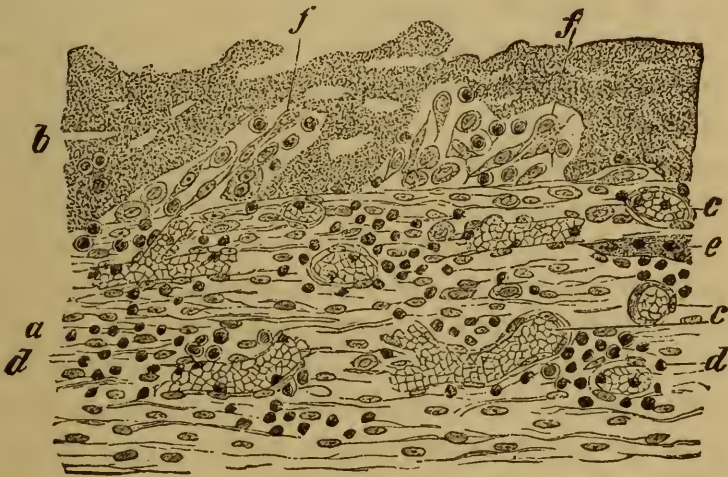

FIG. 141. ADHESIVE PERICARDITIS.

(Section through the pericardium and overlying false membrane: $\times 150$.)

- | | |
|---|---|
| <i>a</i> , epicardial or visceral pericardium. | <i>e</i> , lymphatic filled with cells and small granular coagula. |
| <i>b</i> , fibrinous false membrane. | <i>f</i> , formative cells within the false membrane, derived from migrated leucocytes. |
| <i>c</i> , distended blood-vessel. | |
| <i>d</i> , leucocytes infiltrating the tissues. | |

cases they are not to be separated without tearing the heart-wall. If the exudation has been highly fibrinous, fragments of unabsorbed fibrin may lie for long between the two surfaces, and may ultimately become calcified. A like change occasionally involves the new tissue itself, and thus the heart may come to be surrounded with a carapace of calcareous plates. Pericardial adhesions are a common cause of cardiac hypertrophy (Art. 279).

Plastic pleurisy occurs as an independent affection, and also as an accompaniment of various pulmonary inflammations. Slight attacks give rise to a moderate amount of pleural thickening, and to the forma-

tion of delicate adhesions. After long-continued or often-repeated inflammation very dense and extensive false membranes may be formed, and the resulting adhesions may be extremely firm and tough (see the Chapters on pulmonary affections). The absorption of the effusion is often slow, especially when it becomes condensed to a cheesy consistence. In this case it may become calcified, as may also the new-formed fibrous tissue in the adhesions.

Plastic peritonitis likewise occurs independently, and also as a secondary result of various inflammatory affections of the abdominal viscera. In the latter case it is usually localized to the neighborhood of the affected organ, such as the liver, spleen, ovary, stomach, etc. Simple thickening of the peritoneum is a less common result; but it does occur, especially in connection with the spleen (see Art. 321). Adhesions are usually formed, and are slight or dense according to the duration of the inflammation. Delicate false membranes are very apt to be the seat of hæmorrhage (hæmorrhagic peritonitis).

In general peritonitis, which is primary and chronic, very considerable thickenings of the membrane may be produced. They may be diffuse or localized, and are sometimes scar-like or even cartilaginous in density. The mesentery when so thickened usually contracts; the omentum may shrink into a kind of roughly-twisted rope (*peritonitis deformans*). The various organs are extensively adherent, the loops of the intestines being sometimes glued into a single mass, while the liver and spleen may be completely enclosed in adhesions. The effused liquid may be scanty or abundant, and the proportions of albumen and of cells it contains vary with the stage and intensity of the inflammation.

The peritoneal inflammation here described occurs chiefly as a result of intense engorgement of the abdominal vessels, such as follows upon valvular disease of the heart or hepatic disease: and it may be accompanied by an abundant dropsical or ascitic effusion.

354. **Purulent inflammation** of the serous membranes is either primary, or developed from an originally sero-fibrinous inflammation by an increase in the inflammatory migration of blood-cells. No sharp line can be drawn between sero-fibrinous and purulent inflammation; for various intermediate or fibrino-purulent varieties occur in which the exudation is pus-like, while at the same time it contains soft white cellular flakes and curds of fibrin. The organs are in such cases covered with a film of purulent fibrin, and may be cemented together by it.

The exudation sometimes becomes putrid, that is to say it becomes discolored and foul-smelling. This is most apt to occur in abdominal inflammation, depending on septic processes in the uterus or its appendages, or on the escape of fæcal matters from the intestine. The putrid exudation contains multitudes of micrococci, single or in chaplets, and occasionally microbacteria.

In all recent inflammations whether fibrino-purulent, purulent, or

putrid, the membrane is intensely injected, its connective tissue infiltrated with leucocytes, and its epithelium destroyed. The pus corpuscles of the exudation rapidly become fatty and break down. Purulent effusions are much less readily absorbed than serous effusions. Death often intervenes while the inflammation is at its height. In favorable circumstances the absorption may be complete; but usually the liquid parts only are removed, while the fatty disintegrated pus-corpuscles become condensed to a caseous mass which long lies unabsorbed, and may ultimately become calcareous. As the presence of the pus keeps up the inflammatory process granulations and fibrous tissue may at length be developed, producing fibrous bands and adhesions of great extent.

Thus the pleura, where it is in contact with a circumscribed purulent effusion (**empyema**), becomes covered with granulations and in time thickens into a dense tough fibrous membrane. If the pus is absorbed or removed by operation the thickened layers of the pleura grow together into a stout cicatricial adhesion. General purulent peritonitis and purulent pericarditis usually end fatally while the inflammation is still at its height.

CHAPTER XXXIII.

TUBERCULOSIS OF SEROUS MEMBRANES.

355. **Tuberculosis** attacks the serous membranes in three distinct ways. It may be a local manifestation of general miliary tuberculosis; or the tuberculous infection may be conveyed to the serous membrane from some contiguous focus of tubercle in one of the organs; or it may be primary, that is to say no other primary focus of infection may be discoverable.

Three forms may be distinguished according to their anatomical characters. In the first the tubercles appear without inducing any general inflammation; this is chiefly the case in miliary tuberculosis. In the second the eruption of tubercles is accompanied with extensive inflammatory changes and with effusion of liquid. In the third the inflammatory changes come to the front, the tubercles being everywhere as it were embedded in inflamed or new-formed inflammatory tissue. There are however no sharp lines to be drawn between the three forms, which often pass one into the other.

356. The eruption of gray tubercles in general miliary tuberculosis, unaccompanied by diffused inflammation, is most commonly observed in the pleura and peritoneum; it is rare in the pericardium. The gray nodules consist of aggregations of small leucocytes surrounding the small vessels (Art. 123). The epithelial cells may long remain unchanged, but they are ultimately shed and disappear.

Eruptions of miliary tubercles accompanied by moderate inflammatory action are met with chiefly in cases where the serous membrane is infected from a contiguous focus of disease, such as a tuberculous lymphatic gland, a carious vertebra, a phthisical lung, or a tuberculous ulcer of the intestine. Cases occur in which no such starting-point can be made out, and in these we are obliged to consider that the affection is primary in the serous membrane: the peritoneum is by far the commonest seat.

The tuberculous eruption is sometimes local, for instance it may be confined to the true pelvis, to the neighborhood of the spleen, or to a single spot of the pleura or pericardium; or it may extend over an entire membrane or over more than one, as for example over pleura and peritoneum simultaneously. In the latter case there is usually some fluid effusion, and sometimes it is stained with blood. The number of tuber-

cles may be quite small, or so great that the surface of the membrane feels finely granular. The tissue around the tubercles is injected and often beset with minute hæmorrhagic patches. *Post mortem* these latter may have a slaty gray look from the formation in them of ferrous sulphide (Art. 68), or they may be brown or black from other alterations in the blood-pigment. If the affection lasts any time the membrane is usually thickened, and the mesentery and omentum become contracted and deformed. Surrounding the tubercles zones of highly-vascular delicate semi-translucent fibrous tissue are often developed.

Corresponding to the obvious appearances just described we always find on examination that the neighboring tissue is more or less exten-

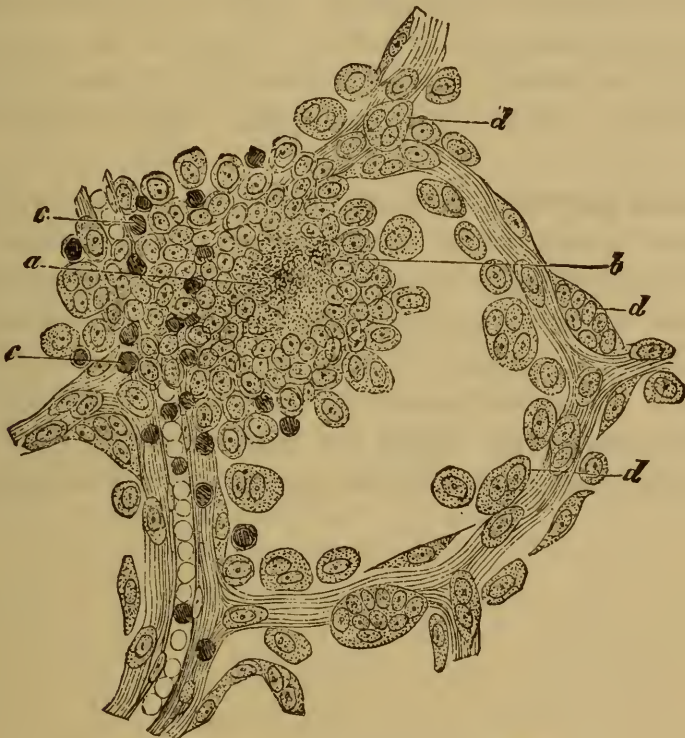

FIG. 142. TUBERCULOSIS OF THE OMENTUM.

(Carminic staining: $\times 200$.)

a, centre of the tubercle.
b, epithelioid cells.
c, lymphoid cells.

d, proliferous epithelial cells in the neighboring tissue.

sively infiltrated with cells. The epithelium is generally in process of proliferation and catarrhal desquamation (Fig. 142 *d*). The tubercles consist of close-set masses of cells (*a*), amid which it is seldom easy to distinguish the ordinary tubercle-elements from the products of epithelial proliferation.

357. In the third form of tuberculosis, referred to for distinction's sake as **adhesive tuberculous inflammation**, the extensive inflammatory changes form the chief character. As in other adhesive or plastic inflammations, abundance of young translucent cellular connective tissue is developed and forms false membranes and adhesions between the dif-

ferent parts. Gray or yellow nodules are scattered through the new-formed tissue, and very often there are also yellowish cheesy foci embedded in it or involving the sero-fibrinous films covering the organs.

Tuberculous pericarditis commonly results in complete adhesion of the layers of the pericardium, though cases also occur in which a certain amount of liquid, cellular, or fibrinous exudation persists in the cavity of the sac. The new-formed tissue of the adhesions consists of delicate grayish-red granulations interspersed with dense fibrous bands, and contains gray or yellowish discrete tubercles as well as larger continuous caseous masses.

Tuberculous pleurisy is most frequently met with in connection with tuberculous disease of the lungs. Here too the tubercles are seated either in the young vascular connective tissue or in the dense fibrous cicatrices which are formed. A certain amount of sero-fibrinous effusion is usually present; while the larger diffuse caseous masses are rarely seen.

Tuberculous peritonitis is characterized by an abundant development of fibrous tissue, which forms adhesions and false membranes around and between the abdominal viscera. The omentum and mesentery are always more or less thickened; the former is often transformed into a thick hard nodulated mass, or a mere distorted rope crossing the cavity of the abdomen. The new-formed fibrous tissue, and the thickened and infiltrated serous membrane itself, are beset with tubercles and caseous patches in varying numbers. There may or may not be a liquid effusion.

CHAPTER XXXIV.

TUMORS AND PARASITES OF SEROUS MEMBRANES.

358. **Primary neoplasms** are not often met with in the serous membranes. Some of them belong to the epithelial, and some to the connective-tissue class. Of the former the most interesting are the tumors hitherto described as **endothelial cancers** (WAGNER, SCHULZ, BIRCH-HIRSCHFELD, NEELSEN). They affect the pleura and less often the peritoneum, and generally take the form of multiple flattened nodular growths, white in color, and either isolated or connected by neoplastic bands, the intervening serous membrane being more or less thickened. A certain amount of serous or sero-fibrinous effusion is usually present. The growths give rise to metastasis; and in the case of the pleura these secondary growths chiefly affect the peribronchial fibrous tissue, the bronchial glands, and the muscles of the thorax.

The tumor is characterized by the presence in it of nests and clusters of epithelial cells (WAGNER, SCHULZ, NEELSEN) which at the periphery of the growth have often a columnar appearance. The nests and clusters lie in a dense fibrous stroma, and follow exactly the course of the lymphatic vessels. They are usually said to arise from the multiplication of the endothelial cells of the lymphatics, but this appears to be very doubtful. As it can be shown that the surface epithelium of the serous membrane is in a state of active proliferation (NEELSEN), and gives rise at least to some of the columnar elements of the growth, it is more natural to refer the development of the neoplasm generally to the proliferation of the epithelium of the primitive body-cavity (Art. 348), and thus to reckon it as a genuine carcinoma.

Fibroma and myxoma are the commonest of the connective-tissue tumors, but even they are rare; sarcoma is very rare. WALDEYER has described a single case of plexiform angiosarcoma of the peritoneum.

Tumors of the subserous tissue are more common, especially fibroma, lipoma, and sarcoma. Tumors of the mediastinal tissue are comparatively common, and may reach a very great size.

Secondary growths are much more frequent than primary ones. Cancers of the peritoneum follow from primary growths in the abdominal viscera; cancers of the pleura from growths in the mamma or thyroid gland. Cancer of the œsophagus and stomach may affect the pericardium by direct extension, or by giving rise to metastatic nodules.

Metastases generally take the form of definite nodes or nodules. In the pleura they lie chiefly along the course of the pleural and subpleural lymphatics. According to the texture of the parent growth, they are soft and white or medullary, hard and scirrhous, or occasionally brown or black, that is to say melanotic. The surrounding tissue may be but slightly affected, or it may be thickened, hyperplastic, indurated, and full of new vessels. When the nodes lie thick together the affected region (such as the omentum) may be changed into a thick dense tuberculous mass.

Less frequently the growth is indefinite or diffuse. This is the case however with colloid cancer of the intestine or ovary, which may attack the peritoneum by direct extension and fill the entire abdominal cavity with gelatinous masses.

Dermoid and teratoid tumors (foetal inclusions) are comparatively rare in the peritoneal region. The former are chiefly met with in women, and are seated in the ovary or its neighborhood. Foetal inclusions (Art. 13) may occur in various sites, and take the form of cysts adhering to the surrounding organs and containing foetal rudiments.

Serous **cysts** are generally found in connection with the female generative organs. Occasionally cysts of various sizes occur in other parts of the abdomen, but their mode of origin is not yet sufficiently known. They contain a highly albuminous liquid, which is sometimes viscid and mucous in consistence.

Of the **animal parasites** the echinococcus is of some importance. It may form hydatid cysts of considerable size in the serous cavities, and the cysts are often adherent to the surrounding parts. Cysticerci are occasionally met with, but they seldom give rise to any notable disturbance. Sometimes intestinal parasites, such as round-worms, escape into the peritoneal cavity either through some pre-existing wound of the intestine or by direct penetration. The consequence is usually a purulent or putrid peritonitis.

Embryos of *Trichina* pass from the intestine into the peritoneal cavity; they do not however remain there, but pass on into the muscles.

References on cancer of the serous cavities:—WAGNER, *Arch. d. Heilk.* XI.; R. SCHULZ, *ibid.* XVII. BIRCH-HIRSCHFELD, *Path. Anat.*; CHURCH, *Trans. Path. Soc.* 1870; BOSTROEM, *Deutsch. Arch. f. klin. Med.* XXIX.; BÖHME, *Virch. Arch.* vol. 81; NEELSEN, *Deutsch. Arch. f. klin. Med.* XXXI.; G. DE MASSY, *Gaz. d. Hôpitaux* 1867; GROSS, *Philadelphia Med. Times* 1878; HUBL, *Wien. med. Woch.* 52, 1879; THIERFELDER, *Atlas d. path. Histologie* Plate XXII.

SECTION V.

THE SKIN.

CHAPTER XXXV.

INTRODUCTORY.

359. **The skin** is a somewhat complex structure, which fulfils not merely the passive office of covering and protecting the organism, but also certain active functions of an important kind. It serves as an organ of touch, as a regulator of the body-temperature, as a secretory organ with a definite secretion, and as an excreting and absorbing organ subserving among other purposes the adjustment of the gaseous constituents of the tissues. In accordance with the nature of its physiological functions it is in close relation both with the tissues and with the outer world. No other organ in the body has so many different tasks to perform, and none is so constantly exposed to extraneous influences.

Its close relations with the rest of the body and with the outer world account sufficiently for the fact that it is especially liable to disease and injury. The mechanical, thermal, and chemical influences to which it is perpetually exposed often induce in it morbid changes, chiefly of the inflammatory kind; while vegetable and animal parasites settle in it and affect it injuriously in various ways. The disorders which are induced by the direct action of injurious agents are classed as **idiopathic skin-diseases**.

In like manner the skin may be affected by morbid influences from within, arising from changes in the blood or the juices, or indirectly from disorders of the heart, liver, kidneys, genital organs, nervous system, etc. Disorders which appear as the manifestation or the result of a primary disorder having its chief seat elsewhere are classed as **symptomatic skin-diseases**.

In view of the endless variety of injurious agencies by which the skin may be affected, it is plain that no good end can be served by treating the pathology of the skin on purely ætiological lines. Moreover, the fact that the same injury may give rise in different individuals to very different affections, and that conversely different injuries may produce the same ultimate effect, affords another reason against the classification of skin-diseases according to their causes alone.

In the following chapters we shall classify the diseases of the skin in the main according to the histological changes which they involve. Ætiology will be appealed to as a subsidiary principle of classification in affections where (as in parasitic disease) the exciting cause either is itself

amenable to microscopical investigation, or always induces the same specific textural change. The histological mode of classification cannot of course be always carried out with perfect strictness. The above-mentioned fact—that the same morbid change may be produced in various ways and may thus appear as a stage in various distinct morbid processes—obliges us now and then to have regard to the general clinical course of a disease as well as to its histology. And as in the case of the skin we can follow without difficulty the evolution and progress of the morbid processes, and so ascertain that the same phase of textural change is not always associated with the same disease (as indicated by its clinical course), we are constrained to modify somewhat the subdivision of the subject which mere pathological anatomy would suggest.

References to the most recent works on the subject:—KAPOSI, *Path. und Therapie d. Hautkrankheiten* Vienna and Leipzig 1880; HEBRA and KAPOSI, *On Diseases of the skin* (New Syd. Soc.) London 1866–1880; NEUMANN, *Text-book of skin diseases* (trans. by PULLAR) London 1871 and *Lehrbuch d. Hautkrankheiten* Vienna 1880; BEHREND, *Lehrb. d. Hautkrankheiten* Berlin 1883; DUHRING, *Diseases of the skin* Philadelphia 1882; *Vierteljahrsschrift f. Derm. u. Syphilis* I.–VIII.

CHAPTER XXXVI.

DISORDERS OF CIRCULATION.

361. The activity of the circulation in the skin varies greatly even under physiological conditions, and its pathological variations are equally remarkable. **Hyperæmia** of the skin may be diffuse or circumscribed, and gives rise to a redness that disappears under the pressure of the finger. The tint varies from pale rosy-red to dark blood-red or the livid purple of cyanosis. The congestion or engorgement of the vessels is limited almost entirely to the upper layers of the corium and especially the papillary layer. The hyperæmia may be active or passive. Active hyperæmia depends upon local injury (and is therefore idiopathic), or upon vaso-motor influences (and therefore symptomatic). Spots of hyperæmia when small constitute **roseola**, when large and diffuse **erythema**. Sometimes the hyperæmic parts are also notably swollen and the tissues saturated with transuded liquid; this is the case in inflammatory œdema (Art. 24). When the hyperæmia persists for a time the epidermis is loosened and shed, and we have desquamation. And after the hyperæmia has disappeared, especially if it has lasted any time or has frequently recurred, a certain amount of pigmentary discoloration remains, due to the transformation of the extravasated red corpuscles into pigment. After death simple hyperæmia usually leaves no trace on the skin. Engorgement or passive hyperæmia generally gives rise to ill-defined bluish-red blotches. A small spot is called a **livor** or **livedo**, a more diffuse lividity constitutes **cyanosis**.

Anæmia of the skin is manifested by its abnormal paleness, and may be local or general. It may be due either to direct external influences, or to stimulation of the vaso-constrictor nerves.

Œdema of the skin, that is to say saturation of it with serous liquid, is due either to engorgement of the veins or lymphatics, or to increased permeability of the walls of the vessels. Œdematous skin is thick and puffy, and liquid runs from it when it is cut; in extreme cases the epidermis rises in blisters or blebs (Art. 370) from the papillary layer.

Active hyperæmia is not always easy to distinguish from inflammation, into which it often passes as a second stage. The erythematous affections (such as those due to mechanical injury, to heat, etc., and those occurring symptomatically in connection with dentition, dyspepsia, etc.) are usually accompanied by a certain amount of inflammatory exudation.

Acne rosacea is characterized by bright-red spots, nodules, and tuberosities containing dilated blood-vessels, which develop slowly over the surface of the nose and cheeks. Its growth is due to long-continued distention of the cutaneous vessels, sometimes associated with enlargement of the sebaceous glands.

361. Recent **hæmorrhages** in the skin give rise to red stains which do not disappear when pressed with the finger. When they form small irregular specks they are called **petechiæ**, larger elongated or ramified streaks are called **vibices**, and still larger irregularly shaped stains are called **ecchymoses**. When the hæmorrhage gives rise to a nodular or papular irregularity of the skin, it is called **lichen hæmorrhagica** or **purpura papulosa**; when the extravasated blood is collected into a tumor or raised patch it is described as an **ecchymoma** or **hæmatoma**; when it raises the epidermis into a large vesicle or bleb it is a **hæmorrhagic bulla** or blood-blisters.

The seat of hæmorrhage varies; usually it is in the corium and papillary layer, and thence the extravasated blood passes up under the epidermis and either raises it from the underlying layers or penetrates among its cells. If the blood gains entrance to the sweat-glands and escapes through their ducts, we have **hæmatidrosis** or bloody sweat.

The changes passed through by the coloring matter of extravasated blood (Art. 68) may be followed with the naked eye in the case of cutaneous hæmorrhages. The bright red of recent blood passes through bluish-red and yellowish-green into brown. After a time the discoloration disappears as the pigment is absorbed, and the altered blood which has penetrated between the epidermal cells comes to the surface and is shed with them.

Cutaneous hæmorrhages are distinguished into idiopathic and symptomatic. Spontaneous hæmorrhages are grouped together under the general name of **purpura**.

The spontaneous or purpuric hæmorrhages are symptoms or consequences of certain affections, some of which are at present ill-understood. The hæmorrhages which accompany some forms of small-pox (*variola hæmorrhagica* or **purpura variolosa**) may become very serious indeed. They begin as small irregular specks, which in a few hours expand and coalesce into great blood-stained patches. Plague, bites of serpents, septicæmia, scarlatina, endocarditis, and other infective and toxæmic conditions are often accompanied by cutaneous hæmorrhages in the form of petechial or livid spots, due to changes in the blood or in the vessel-wall, or occasionally to embolic lodgments of bacteria in the arterioles of the skin.

Purpura (*peliosis*) **rheumatica** is a peculiar affection which sets in with pains in the knees and ankles, generally accompanied by slight fever; presently large and small ecchymoses appear in the neighborhood of the knees; the exciting cause is unknown. We know as little of the cause of **purpura simplex** and of **purpura hæmorrhagica** (*morbis maculosus Werlhofii*), diseases in which, along with fever and loss of strength, hæmorrhages of the skin appear in various parts of the body. In the latter affection, which is occasionally fatal, the ecchymoses may be as large as the hand or larger, and copious bleeding from the mouth, nose, pharynx, and mucous membranes generally, may ensue.

The hæmorrhages in scurvy or **purpura scorbutica** are usually very grave, and take place not merely into the skin but into the subcutaneous tissues and gums. The affection is nearly always attributable to insufficient or improper food.

The lower limbs of aged patients are sometimes covered with circumscribed pétéchiæ (**purpura senilis**) depending on atheroma of the arteries and the disturbances of circulation to which it gives rise.

S. MACKENZIE, in a paper *On the nature of purpura* in the *Brit. Med. Journ.* 2, 1883, discusses the present state of our knowledge regarding it, and gives full references to previous works. In a case of purpura hæmorrhagica observed by RUSSELL, WATSON CHEYNE (*ibid.*) found the ruptured capillaries crammed with colonies of bacilli.

CHAPTER XXXVII.

DISCOLORATION AND ATROPHY OF THE SKIN.

362. **Discolorations** of the skin may be diffuse or circumscribed. They are due either to an increase of the natural pigment of the rete and corium (pigmentation proper), or to the deposit of abnormal pigment derived either from without or from some intrinsic source such as extravasated blood (dyschromatosis or staining).

Certain abnormal **pigmentations** are congenital and take the form of brown or black spots of various size. They are called **nævi pigmentosi** or moles: *nævus spilus* is soft and smooth; *nævus verrucosus* is rough and warty; *nævus pilosus* is hairy (Art. 398).

Acquired pigmentations are described generally as **chloasmata** and are either idiopathic or symptomatic. Freckles and sun-spots (**lentiginines** and **ephelides**) are examples of the former; they are brownish or yellowish irregular specks from the size of a pin's head to that of a pea. Sun-spots occur chiefly on the face in young people and disappear with advancing years. True or 'cold' freckles have no favorite seat and persist during life (Art. 398).

Pigmentation is often a result of frequently recurring hyperæmia and inflammation, such for instance as are produced by excessive scratching (traumatic chloasma), or long-continued exposure to the sun (sun-burn).

Disorders of the viscera, and especially of the uterine system in women (**uterine chloasma**), may be followed by discoloration of the skin; and the skin of marasmic patients is often remarkably pigmented.

Addison's disease is an obscure affection in which the skin assumes a brown or bronze-like hue (*cutis ænea*), and the patient falls into grave cachexia. The bronzing of the skin is said to be connected with the changes in the suprarenal bodies often observed in the disease; but it may be present when the suprarenals are healthy (see BURGER, *Die Nebennieren* Berlin 1883).

In these affections the pigment is met with partly in the deepest layers of the rete mucosum, and partly in the corium. It takes the form of brown or yellow granules, but sometimes the cells are uniformly stained.

The **dyschromatoses** are to be distinguished from true pigmentations; they are due to staining of the corium with various coloring-matters derived from the body itself or from without. Icterus or jaundice

is one example, the skin being stained with bile; argyria or silver-staining due to the long-continued medicinal use of salts of silver, and tattooing, are others. In **jaundice** the skin may be of any shade from lemon-yellow to dusky yellow or green; in **argyria** it may vary from slate-color to brown, the dark granules of reduced silver lying chiefly in the cutis. In **tattooing** the skin is pricked with needles till it bleeds, and coloring-matter, such as charcoal, gunpowder, cinnabar, Prussian blue, or indigo, is then rubbed in; a certain amount of the granular insoluble pigment is retained and remains in the cutis.

363. **Simple atrophy** implies a loss of substance in the several constituents of the skin, generally associated with some change of their structure. It may be localized or general, secondary or primary.

In the physiological retrogression of old age or senile atrophy, certain textural changes take place in the skin which may occasionally become very highly marked. The skin becomes thinner, owing to the alteration of the papillary layer; in some spots where they are normally small the papillæ may disappear entirely. The fibrous bundles of the corium become scanty, and often look turbid or granular in texture, the granules not disappearing in preparations put up in Canada balsam. The structure of the fibrous bundles may be visible or obscured; the latter effect being due to a kind of hyaline degeneration by which the bundles take on a swollen glassy look, not unlike that of solidified jelly (NEUMANN). The vessels of the skin are here and there obliterated, so that in injected preparations the meshes of the capillary network appear abnormally wide. Deposits of pigment in the form of yellowish-brown or dark-brown granules are often observed, and these lie either in the cells of the rete or around the vessels of the cutis.

364. The changes in the cutis are accompanied by corresponding changes in the epidermis. The softer strata become thinned out, so that the horny layer is separated from the papillæ only by a few layers of cells. The horny layer is dry and brittle, and often scaly or branny (**pityriasis tabescentium**). Here and there aggregations of the epidermic scales take place, forming whitish patches of various sizes.

The hairs fall out and are not renewed, the hair-follicles being either empty or producing only a kind of down. Several downy hairs may spring out of one follicle, being developed from a single papilla successively, or from several papillæ seated in secondary saccules within the chief follicle. The follicles may be shrunken and atrophied (Fig. 143 *b*) or distended with accumulations of epidermal cells mixed with small hairs (*c*); in many of them the papilla disappears altogether. The shrunken follicles are cylindrical or conical, or distorted and sacculated. It often seems as if the root-sheath were attempting to bulge here and there into new follicles. When the follicle is much shortened it simply looks like the duct of a sebaceous gland. The follicles are hardly ever entirely destroyed (NEUMANN); even when the root-sheath disappears

the pit or sacculation remains, and is often crammed with cornified epidermal cells.

A certain number of the sebaceous glands disappear from the denuded atrophic patches; others are stunted and shrunken; and others again are distended with retained secretion into cysts (Fig. 143 *d*) which may grow to some size (**milium** or **grutum**); they occur chiefly in places which have been covered with hair, such as the scalp.

The sweat-glands are not perceptibly altered.

Localized atrophies of the skin in the form of whitish streaks and patches are frequently observed in persons of mature age over the buttocks, the trochanters, the anterior margin of the pelvis, the knees, etc. Women who have been pregnant usually have shining white streaks (**lineæ albicantes**) on the surface of the abdomen, and sometimes on the thighs and buttocks. According to LANGER (*Anzeiger d. Gesell. d. Aerzte in Wien* May 1879, *Lond. Med. Record* 1880) in such streaks the fibrous bundles of the cutis are stretched but not ruptured and the

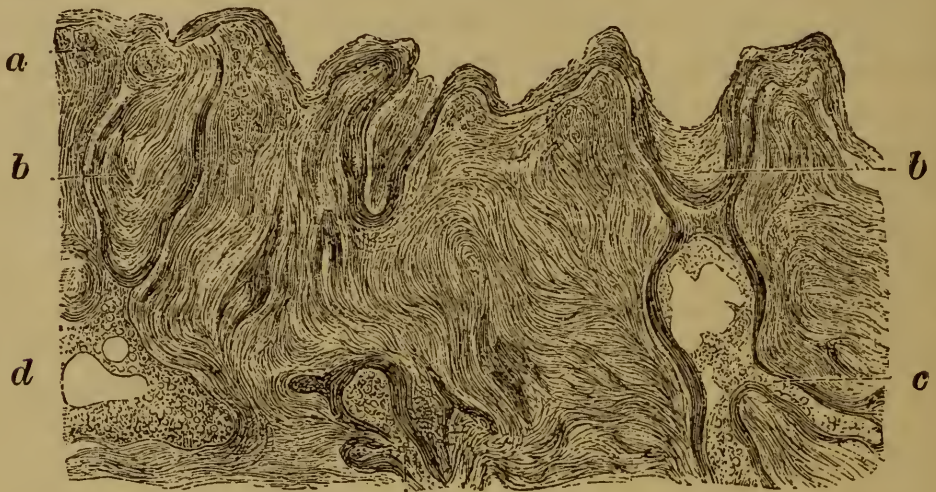

FIG. 143. SENILE ATROPHY OF THE SKIN.

(Section from a highly degenerate part of the skin of the forehead; the hair-follicles are shrunken and contain epidermal cells and retained sebum; after NEUMANN.)

a, cutis with turbid granular spots in it.

c, cornified cells filling the hair-follicle.

b, shrunken hair-follicle with the outer root-sheath.

d, distended sebaceous gland

papillæ are more or less obliterated. The white color is due not so much to the thinning of the skin as to the parallel arrangement of the fibrous bundles. The white patches which follow upon anasarca are of a like nature.

Cutaneous atrophies may be produced by pressure, either from within as when tumors force their way through, or from without as when callous parts press or rub upon other parts. Chronic inflammations and certain neuroses also lead to cutaneous atrophy, which has the same general characters as that described in the text.

Xeroderma or parchment-skin is a peculiar affection described by HEBRA and KAPOSI (*Diseases of the skin* III.) which occurs in two main forms. In one the skin is dotted over with smooth spots of yellowish-brown, red, and white; the epidermis is thin dry and parchment-like, being either smooth or furrowed and wrinkled; the cutis is thin and tightly stretched, shrunken, and devoid of fat: the affection is met with chiefly in children, and is progressive. In the other

form, which is stationary, the skin is white and tense ; and the epidermis is thin and shiny and comes off in glistening scales.

365. Atrophy of the cutaneous pigment (**achroma** or **leukopathia**) may be a congenital or an acquired affection. When congenital it is described as albinism ; when acquired as vitiligo or *leukoderma acquisitum*. General or universal **albinism** consists in congenital absence of all the normal pigment of the body. Albinoes have a milk-white or pinkish skin ; their hair is yellowish-white and silky, the iris and choroid are uncolored, and therefore show the red tint of the blood they contain. Albinism is not very common among Europeans, but it is common enough among negroes. Partial albinism also is often seen in negroes ; they have one or more patches of white on the body, but the eyes are not devoid of pigment.

Vitiligo sometimes appears without any discoverable cause. Some cases seem to be connected with certain changes in the cutaneous nerves (LELOIR, *Arch. de physiol.* 1881). It takes the form of white or pinkish patches surrounded by a zone of increased pigmentation. Occasionally by the growth and coalescence of new patches the affection may extend over a considerable extent of the skin.

White spots may follow upon inflammatory affections of the skin, such as boils, lupus, syphilitic eruptions, leprous growths, etc.

Atrophy of the pigment of the hair (**canities** or poliosis) is a physiological phenomenon when it occurs in advanced age. The pigment-granules in the cortical substance of the hair diminish in number ; but this is because the formation of pigment in the bulb is arrested (КАПОСИ), not because the pigment already existing in the hair is destroyed.

In premature grayness the process is the same.

CHAPTER XXXVIII.

INFLAMMATIONS OF THE SKIN.

c. *Transitory eruptions with slight exudation: erythema, papulæ, urticæ.*

366. In speaking of **erythema** as a form of simple cutaneous hyperæmia (Art. 360) we pointed out that any intensification of the process might lead to exudation, and so transfer the affection from the category of hyperæmia to that of inflammation or **dermatitis**. There is no very obvious difference in appearance between erythematous hyperæmia and erythematous inflammation, except it be that in the latter the affected part is somewhat swollen. If the exudation is confined to the region of a few papillæ, or is at least more intense at some spots than at others around them, the swelling takes the form of small circumscribed solid elevations known as **papules** or *papulæ*. If the group of swollen papillæ is larger, the flattened elevations then formed are called **wheals** or *urticæ*. When the exudation is still more abundant the irregular prominences are called **tubercules** or *tubercula*. Wheals and tubercules often become pale at the centre while the margin is still hyperæmic.

Microscopic examination shows that these swellings are mainly due to serous exudation, which distends the meshes of the corium and papillary layer and causes the cells of the rete mucosum to swell up. More intense and more enduring inflammation is accompanied by greater extravasation of cells, so that the fibrous tissues appear infiltrated with leucocytes.

The swelling of the individual cells of the rete sometimes results in the liquefaction and destruction of some of them, in which case the papules and wheals are transformed into **vesicles** (Art. 370). The exuded liquid often contains red corpuscles; in this case the redness of the spot does not wholly disappear when pressed with the finger, but a certain amount of reddish or brownish staining remains.

The effect of such inflammations on the skin is generally very slight. The exudation being mainly liquid is readily and speedily re-absorbed, and there is often nothing left to indicate the existence of the affection. In some cases the surface layers desquamate in the form of thin scales and shreds, or if hæmorrhage has occurred some slight pigmentation remains, though this also disappears after a short time.

367. The **causes** of these slight inflammations are exceedingly various. They occur after external injuries of many kinds, as accessory symptoms in certain infective diseases, and in affections of the internal organs. Frequently no cause at all can be assigned; now and then they seem to be due to a neurosis of the vaso-motor mechanism.

Special mention must be made of the following forms, among the many which occur; they are distinguished by their special course and symptoms.

(1) The eruption of **measles** (*morbilli, rubeola*) appears first on the face, forehead, and temples, and thence extends over the back of the neck, the shoulders, and the trunk. It forms dull red or raspberry-colored patches of the size of the finger-nail or larger, with a tendency to crescentic grouping; the patches are either level with the skin, or slightly raised into papules corresponding to the openings of the hair-follicles. The skin and subcutaneous tissue, especially in the face, are somewhat swollen and œdematous. The patches may run together here and there but they never become quite confluent. In a few hours after its appearance the eruption becomes pale, leaving the skin faintly yellow; and presently a slight branny desquamation follows.

(2) The eruption of **scarlatina** appears first on the neck and clavicular region, and thence extends over the back and breast to the limbs. At first it takes the form of minute red dots closely crowded together and giving the skin a diffuse or uniform tint. The tint is at first pink, afterwards deep red, livid, or scarlet. The skin is swollen and infiltrated. The eruption lasts one to three days, and occasionally as long as six or seven; it then fades and leaves the skin stained of a yellowish-brown. Afterwards the epidermis desquamates in flakes and scales of various sizes; if the flakes are large the desquamation is called membranaceous, if small and thin it is furfuraceous. Occasionally the eruption is papular, tubercular or vesicular (*scarlatina papulosa, vesicularis, pemphigoides*), and not infrequently it is hæmorrhagic (*scarlatina hæmorrhagica*). The exudation poured out into the connective tissue is somewhat rich in cells.

(3) **Erythema exudativum multiforme**. According to KAPOSÍ this affection begins as an eruption of flat slightly-prominent circumscribed and scattered spots (*erythema læve*) on the back of the hands and feet and the neighboring parts of the arm and leg. The spots are at first the size of a pin-head but presently grow to that of a pea; they are vermilion in color and turn pale when pressed. They grow at the margins while the centre becomes depressed and cyanotic; the larger spots may become confluent. Hæmorrhages not infrequently occur. As the red margin extends and the centre fades we have *erythema annulare*; if several rings encroach on each other we have *erythema gyratum*; a red spot surrounded by a pale zone and that by a red zone constitutes *erythema iris*; if the eruption becomes papular it is *erythema papulatum*; if there are wheals it is *erythema urticatum* or *lichen urticatus*; if vesicles are formed *erythema vesiculosum*. If the formation of vesicles goes on at the margin while the centre recovers we have *herpes circinatus*, characterized therefore by its ring of vesicles; if a vesicle persists in the centre it is *herpes iris*. Erythema with large blebs or bullæ is *erythema bullosum*. A brown pigmentation usually remains behind after the eruption declines. When vesicles have formed scales and scabs are left. The affection lasts from two to four weeks; its cause is unknown.

(4) **Erythema nodosum** (*dermatitis contusiformis, urticaria tuberosa*) is characterized by the formation of large blotches or rounded nodes usually on the lower limbs. It is sometimes ushered in by slight fever. The blotches are slightly elevated or not at all, and are bright red at the margins and purple at

the centre. In two or three days they begin to fade, passing through tints of blue, yellow, and green. The exudation being chiefly serous absorption is rapid, and the affection leaves nothing behind it but a slight staining of the skin.

(5) **Traumatic erythema** is produced by irritation of the skin, mechanical, thermal, or chemical. Mechanical irritation is exemplified by the friction of clothes or of two parts of the body in contact; the effects of thermal irritation by burns or frost-bites of the first degree; chemical irritants are such as turpentine, mercurial ointment, dilute acids, and the poison of insect-stings. The cutaneous inflammations or swellings induced by frost are called **chilblains** or *perniones*. Erythema is an occasional result of the use of certain medicaments such as quinine, copaiba, or belladonna (VAN HARLINGEN, *Arch. of Dermatology*, 1880; DURING, *Diseases of the skin* Philadelphia, 1882; LEWIN, *Untoward effects of drugs* Detroit, 1883).

(6) **Roseola**, or the rash of circumscribed red spots which occurs in connection with certain general disorders of the system, is allied to the exudative erythema. It is described, from the condition with which it is associated, as *roseola rheumatica, choleraica, typhosa, æstiva, infantilis, etc.*

(7) **Pellagra** (*mal rosso, mal del sole, risipola lombarda*, Lombardian leprosy) is a peculiar disorder met with in the north of Italy, Southern France, Spain, and Roumania. It appears as an erythematous rash on the exposed parts of the body in spring and summer, and disappears in autumn with desquamation of the epidermis. Marked disturbance of the health may occur; the patient becomes debilitated, and nervous symptoms often follow. The disease is apt to recur in succeeding years (MAYR, *Hebra's Diseases of the skin* (New Syd. Soc.) I.; KAPOSÍ, *Path. u. Therap. d. Hautkr.* Vienna and Leipzig 1880; SCHEIBER, *Viertelj. f. Derm. u. Syph.* II.; WINTERNITZ, *ibid.* III).

(8) **Urticaria** or nettle-rash is an eruption of wheals which rise and disappear very suddenly. The wheal is white or yellowish, and is bordered by a zone of red. Sometimes small vesicles or papules are formed. The rash is either caused by external irritation (such as the stings of nettles, of jelly-fish, or of insects), or it is a symptom of some irritation elsewhere, especially in the alimentary canal.

b. *Eruptions with considerable exudation: tubercula, squamæ, vesiculæ, pustulæ, crustæ.*

368. The affections we have next to consider are described collectively as **phlyctænoses**, and are distinguished from the erythematous eruptions by the more intense character of the inflammatory changes involved. In many of them moreover the duration of the affection is greater, and recovery is less easy or less complete.

The inflammatory infiltration may be diffuse or circumscribed. In recent eruptions the cellular exudation lies chiefly in the neighborhood of the veins. Degenerative changes in the epidermal cells and fibrous tissue may precede, accompany, or succeed the exudation. In later stages proliferation of the cells and fibrous tissue is set up, and brings about repair or hyperplasia as the case may be. The **efflorescence** or mode of appearance of these inflammations of the skin is very various.

The infiltration may be local and circumscribed, forming papules; or it may be extensive and diffuse, giving rise to remarkable swellings. The epidermal layers may be beset with vesicles, pustules, scales, crusts, or

scabs; or there may be loss of part of their substance, and the exudation may be poured out on the free surface.

The varieties of cutaneous inflammation or dermatitis such as we are considering differ widely in their general clinical course. Some are acute, others are chronic and occasionally last for years. Their exciting causes are likewise exceedingly various, so that it is difficult to lay down any general proposition with regard to their ætiology.

369. The **exudation**, whether localized or diffuse, consists of liquid, of coagulated fibrin, and of cells. The latter are the most easily recognizable constituent, and in hardened sections are often the only one which the microscope can detect. In slight cases the exudation may be limited

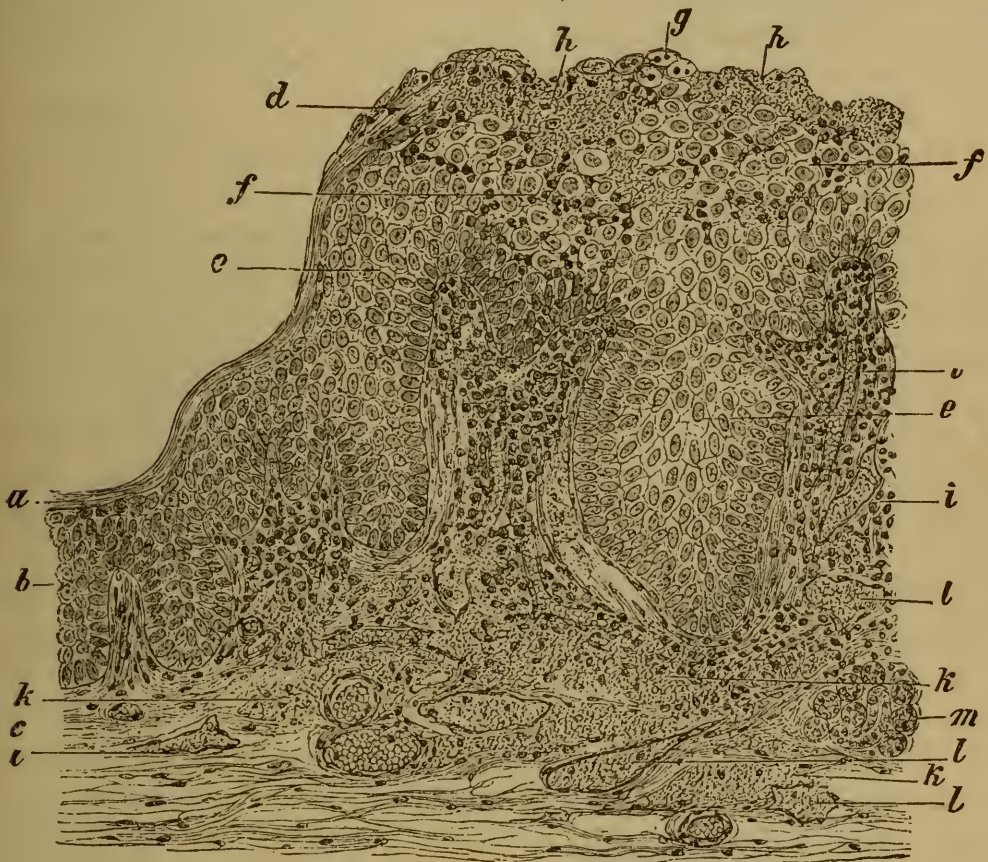

FIG. 144. SECTION THROUGH A SYPHILITIC MUCOUS PATCH.

(Aniline-brown staining: $\times 100$.)

- | | |
|--|--|
| a, horny layer of the epidermis. | g, degenerate epidermal cells into which leucocytes have penetrated. |
| b, rete Malphigii. | h, granular coagula. |
| c, corium. | i, swollen and infiltrated papilla. |
| d, horny layer swollen up and infiltrated with leucocytes. | k, corium infiltrated with cells and fibrin. |
| e, swollen cells of the rete Malphigii. | l, lymphatic vessel. |
| f, swollen epidermal cells infiltrated with cells. | m, sweat-gland. |

to the neighborhood of the papillæ (Fig. 144 *i*); in other cases the cutis (Fig. 144 *k* and Fig. 146 *m*) and even the subcutaneous tissues are thickly infiltrated; and the epidermis may also (Fig. 144 *f g h*) be saturated with exuded liquid.

The proportion of extravasated cells in the exudation may be small or large. Recent and copious exudations (Fig. 145) are usually poor in cells, older and slowly accumulating exudations are richer (Figs. 144 and 146). When the exudation coagulates (Fig. 144 *k*) granular and fibrous masses are formed. The liquid effused into the connective tissue lies partly in the lymph-spaces and meshes, partly in the lymphatic vessels (Fig. 144 *l*).

The liquid poured out from the papillæ passes also into the epidermal layers; and the accompanying cells insinuate themselves between the epidermal cells (Fig. 144 *f*), and afterwards actually penetrate them. The epidermal cells become in this way distended (*f g*) or vacuolated (Fig. 146 *e f*), and the protoplasm and nucleus are displaced. The nucleus may persist for a time, but it ultimately either swells up or crumbles into fragments and so perishes. The cell-membrane withstands destruction longest, but it too may at length dissolve (Art. 371).

370. In many cutaneous affections the changes in the epidermal or epithelial cells do not cease with the simple swelling just described, but go on to the destruction and disintegration of a certain number of the cells, and in this way **vesicles** and **blebs or blisters** are produced. The terms vesicle and blister, used in connection with cutaneous inflammations, imply an excavation under the epidermis due to destruction and solution of some of the cells. Blisters are never produced by the mere collection of fluid between the epidermal layers, say between the horny and the mucous layers. But blisters may be formed by transudation under the epidermis by which the whole membrane is raised without change over a definite area. Such blisters or blebs are not inflammatory in their origin; they are due to vascular engorgement, and are met with in cases of extreme œdema of the integument. The transuded liquid simply raises the epidermal from the fibrous stratum. Similar blisters are formed in putrefactive and gangrenous affections of the skin (Art. 42).

Inflammatory vesiculation is always then the result of excavation due to destruction of epidermal cells in the softer layers of the epidermis, the excavations being always more or less fully occupied by exuded liquid. The epidermal cells may perish in various ways. The time and mode in which the cells die, and the consistence and amount of the exudation determine the character of the vesicular eruption. Thus if the cells are directly injured and killed outright (as by high temperature), while the papillary vessels are simultaneously damaged and pour out abundant exudation, the dead cells are very rapidly dissolved and disappear. On the other hand, if the injury primarily affects the vessels of the cutis and papillæ and so induces exudative inflammation, the cells perish slowly and pass through a comparatively prolonged stage of mere swelling.

When a small portion of the skin is exposed for a short time to a high temperature, the first effect is a marked reddening of the surface.

Then the horny layer is raised by the formation beneath it of a cavity distended with fluid, and a blister is produced.

By the heat the epidermal cells are partially destroyed, and the vessels of the cutis are more or less disorganized. The vessels pour out an exudation, which passes from the tips of the papillæ into the epidermal layers. The cells already killed or injured by the heat are thereby swollen up (Fig. 145 *d*), and soon dissolve completely (*f*). This takes place at first immediately over the papillæ (*d f*). The inter-papillary cells (*e*) may hold out for a time; but they are apt to be stretched and distorted by the exudation, and as soon as this becomes sufficiently abundant they too swell up and then dissolve (*g*). Coagulation sets in as the cells dissolve and the place is taken by granular and fibrous masses whose forms correspond in general to the cell-areas, and so maintain for a time the configuration of the rete Malpighii (Fig. 149).

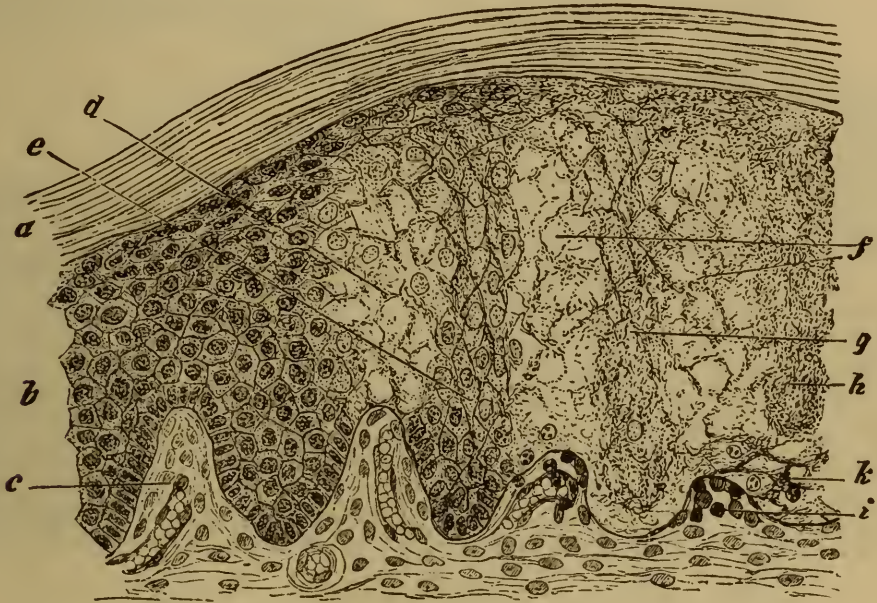


FIG. 145. SECTION THROUGH THE MARGIN OF A BLISTER DUE TO A BURN.

(Carminic staining: $\times 150$.)

- | | |
|--|--|
| <p><i>a</i>, horny layer.
 <i>b</i>, rete Malpighii.
 <i>c</i>, normal papilla.
 <i>d</i>, swollen epidermal cells, in some of which the nucleus is still visible, in others not.
 <i>e</i>, inter-papillary cells, those below being uninjured, those above are swollen and stretched and have lost their nuclei.</p> | <p><i>f</i>, fibrinous mesh-work (composed of cells and exudation; cell-structure altogether lost over the papillæ).
 <i>g</i>, swollen denucleated cells.
 <i>h</i>, inter-papillary cells separated from the cutis and dissolving.
 <i>i</i>, depressed papilla, infiltrated with cells.
 <i>k</i>, subepidermal coagulated exudation.</p> |
|--|--|

The free and abundant exudation which by its pressure raises the horny layer of the epidermis depresses and flattens the papillæ (*i*). If the exudation continues after the solution and coagulation of the epidermal layers, the entire fibrinous mass may itself be lifted by a new accumulation (*k*) taking place beneath it.

371. The above mode of vesiculation occurs only in cases where the

exudation is sudden and abundant. When the inflammation is less acute and the injury to the epidermis less extensive than it is in burns, the vesicles or blebs are formed more gradually. Thus the erysipelatous inflammation of the skin, which follows upon the lodgment in its lymphatics of certain micrococci (Fig. 146 *h i k*), is characterized by primary cellular infiltration (*m*) of the corium and papillæ. When the exudation reaches the epidermal layers the cells (*f*) begin to swell up; they then become vacuolated, that is to say drops of liquid (*e*) distend them and displace their protoplasm and nucleus. If several vacuoles are formed simultaneously within the same cell, the protoplasm is reduced to a kind of mesh-work (*g*), in which however the nucleus can generally be detected. At length the protoplasm dissolves completely and the nucleus is

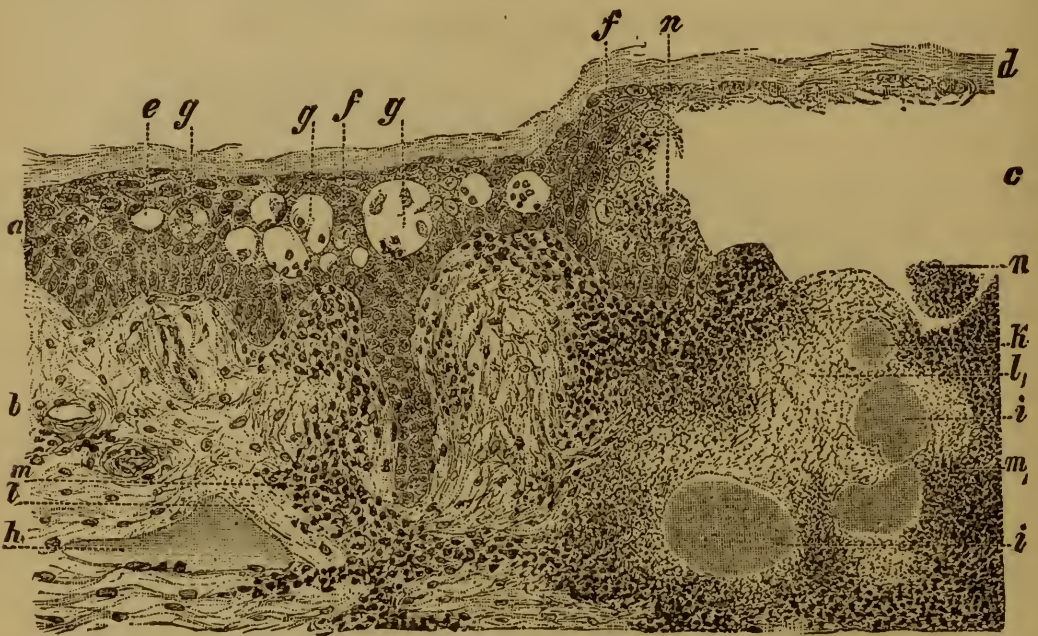

FIG. 146. SECTION OF THE SKIN IN ERYSIPELAS BULLOSUM.

(Alum-carminé staining, mounted in Canada balsam: $\times 60$.)

- | | |
|--|--|
| <i>a</i> , epidermis. | <i>h i</i> , lymphatics filled with micrococci. |
| <i>b</i> , corium. | <i>k</i> , micrococci in the substance of the tissue. |
| <i>c</i> , bleb or bulla. | <i>l l₁</i> , necrosed tissue. |
| <i>d</i> , roof of the bleb. | <i>m</i> , cellular infiltration. |
| <i>e</i> , vacuolated epidermal cell. | <i>m₁</i> , fibrino-cellular infiltration. |
| <i>f</i> , swollen cell and nucleus. | <i>n</i> , fibrino-cellular exudation within the bleb. |
| <i>g g₁</i> , cavities produced by solution of epidermal cells, containing fragments of cells and pus-corpuscles. | |

broken up and disappears. The cell is thus replaced by a cavity (*g*) containing liquid. Several such cavities next coalesce by the solution of the cell-membranes, and so larger and larger cavities (vesicles or blebs) are produced. As the several vesicles become more and more distended the cells lying between them, whether healthy or degenerate, become compressed and stretched or otherwise distorted (Fig. 147).

The vesicles of small-pox, herpes, eczema, and many other eruptions are formed according to the same general plan, but with manifold differences in details. The epidermal changes especially are apt to vary; thus in some cases the cells are speedily transformed into homogeneous glassy flakes or into granular coagula, in others the nuclei break up into fragments at an early stage, and so on.

The above account of the process of vesiculation differs in many points from those given in most text-books and in many dermatological memoirs. It lays much more stress than is usual on the disintegration and solution of the epidermal cells as factors in the process

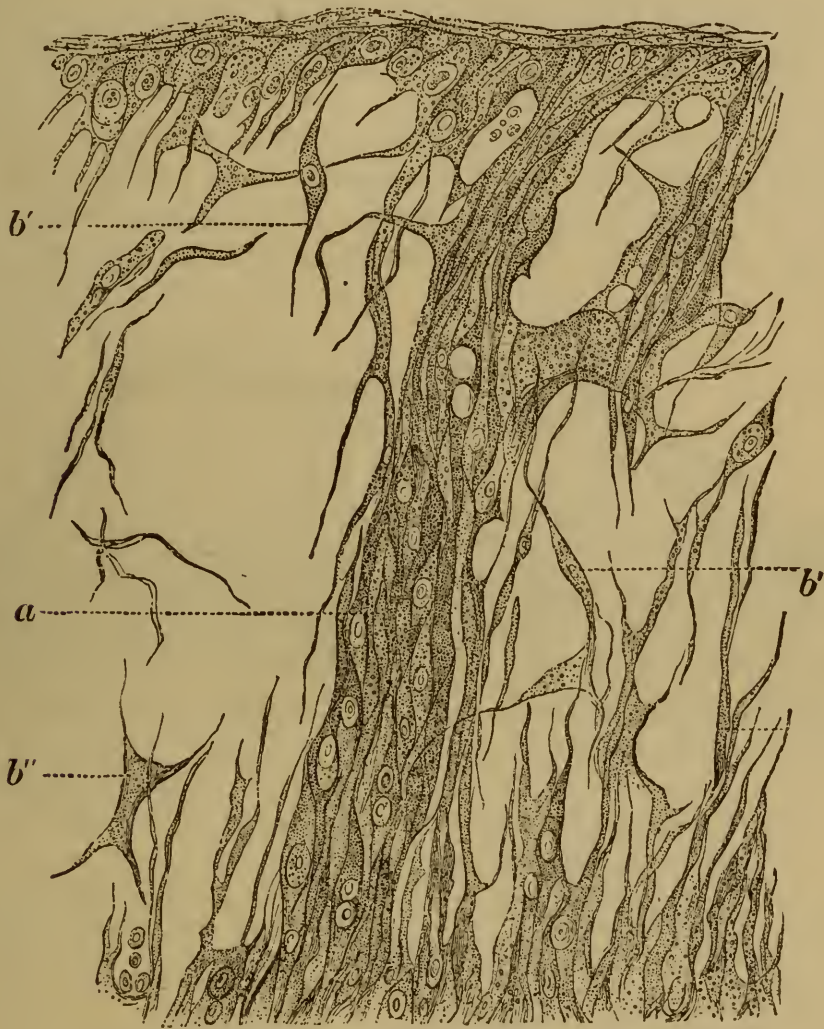


FIG. 147. SECTION THROUGH A VESICLE OF HERPES ZOSTER.

(From HAIGHT, *Sitzungsber. d. k. Akad. in Wien* 1868: $\times 450$.)

a, band traversing the cavity of the vesicle composed of stretched and spindle-shaped epidermal cells.

b, loose mesh-work, composed of spindle shaped cells (*b'*) and stellate cells (*b''*).

The author claims, however, that the account is the outcome of his own researches and those of TOUTON, who worked under the author's direction. Figs. 145 and 149 are taken from TOUTON'S preparations, and are discussed in his paper entitled *Vergleichende Untersuchungen über die Entstehung der Hautblasen* Tübingen 1882. The student may also refer to the papers of WEIGERT (*Anatomi-*

sche Beiträge zur Lehre von den Pocken Breslau 1874) and UNNA (*Virch. Arch.* vol. 69, and *Vierteljahrsschrift f. Derm. u. Syph.* v.).

372. The vesicles just described are always loculated, owing to their mode of origin. As they arise from a number of contiguous foci of degeneration and solution, fragments of cell-walls and compressed or distorted cells are left stretching across the cavity, and so form partial septa. As the vesicle develops, these septa give way or dissolve one after the other, and the loculi run together (Fig. 148) into a single cavity traversed by mere shreds and fibres.

Meanwhile the contents of the vesicle usually undergo certain changes. The first portions of the exudation into the epidermal layers are generally poor in cells. The cavities contain only a few fragments (Fig. 146 *g g*₁) of disintegrated epidermal cells and a few migrated blood-corpuscles. But as the vesicle grows older the latter increase in number, and when it reaches a certain stage its liquid contents become turbid and at length purulent; the vesicle becomes a **pustule**. The stage at which this occurs is a late one in many vesicular eruptions (*variola*, *burns*); in others

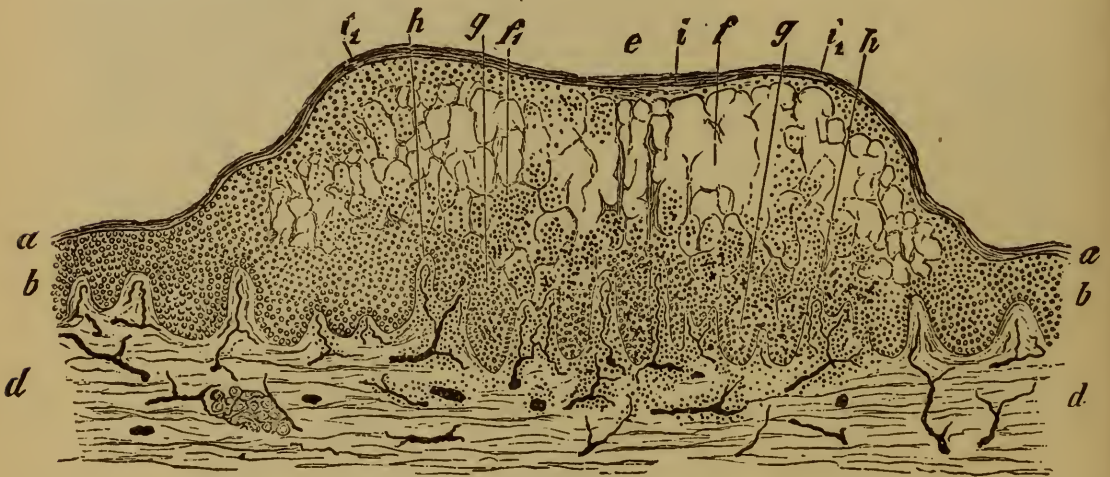

FIG. 148. A SMALL-POX VESICLE PASSING INTO THE PUSTULAR STAGE.

(Injected preparation stained with hæmatoxylin: $\times 25$.)

- | | | |
|---|----------------------------------|--|
| a, horny layer. | b, mucous layer. | h, papilla infiltrated with cells. |
| d, cutis. | e, the vesicle. | i, umbilication over the thin part of the cap of the vesicle. |
| f, cavity of the vesicle. | f ₁ , pus corpuscles. | i ₁ , margin of the vesicle where the cap is thicker. |
| g, epidermal detritus and pus-corpuscles lying between the papillæ. | | |

as in *eczema*, it is early. Sometimes, however, the exudation is purulent from the beginning, and sometimes it contains red corpuscles, so that the contents of the vesicle are blood-stained.

373. When a dermatitis results in infiltration of the epidermis with vesiculation and pustulation, certain other changes usually ensue which lead to the formation of scales, and crusts or scabs.

Scales (*squamæ*) are small bran-like flakes, or larger thin white or

dirty gray glistening lamellæ or plates, or continuous membranaceous shreds, which are shed from the surface of the epidermis. The desquamation is called **furfuraceous** when the scales are branny; it is **membranaceous** when they are larger; and **siliquose** when the scales are chiefly composed of the horny shells of dried-up blebs. The scales occasionally cohere into irregular masses or thick cakes.

The formation of scales depends in part on excessive production and in part on morbid alteration of the corneous cells. The pathological element of the process is this: that the cells forced up from the lower layers of the epidermis to the surface do not pass through the regular stages of cornification, but in consequence of the nutritional disturbance simply become as it were dried up. Scales may likewise be formed in consequence of some morbid change in the secretion of the sebaceous glands (Art. 403).

Crusts or **scabs** (*crustæ*) are formed by the drying of epidermic exudations. They usually result from vesicles and pustules whose contents have ceased to be liquid, but sometimes the primary exudation bursts through the swollen epidermal layers and is effused on the surface of the skin, where it dries. Scabs are often formed from exudations poured out on the denuded surface left after some loss of substance or excoriation of the epidermis, such as is caused by a scratch or graze; and fissures or *rhagades* in the skin usually become covered over with crusts.

If the exuded liquid is serous the crusts or scabs are gum-like; if it contains blood they are brown or black; purulent exudations dry into dirty brownish-yellow scabs. The form and size of the scabs vary with their mode of origin. The skin around them is always somewhat reddened, and their base is swollen.

374. The **issue** of the processes we are considering is generally in recovery and repair, but permanent alteration of the skin is not an uncommon result.

When recovery is about to begin the signs of inflammation gradually disappear, and the exudation ceases. Part of the exuded liquid, namely that within the fibrous tissues, is absorbed; that which lies on the surface, together with the dead and disintegrated epidermal cells, is thrown off, and the defect is made good by regenerative multiplication of the cells around.

The multiplication takes place chiefly along the line where the rete Malpighii borders on the cavity of the vesicle (Fig. 149 *d*); but some share in the process is also taken by the uninjured interpapillary cells, and by the epithelium of the sweat-glands (*h*) and hair-follicles. The process of repair begins soon after the vesicle is formed, in burns it begins on the second day; masses of cells are produced which advance gradually over the denuded and depressed papillæ (*d*). When the multiplication has reached a certain point, differentiation into layers begins to be perceptible (*d*₁); and often at the margin of the vesicle the layers are complete

even to the horny surface layer, before the central parts are covered over (d_2).

The result of this multiplication and growth is that the vesicle with its contents continues to be thrust upwards, and when the new horny layer is complete it lies as it were between two horny shells, and is generally by this time dried up into a mere crust.

The process is different when part of the cutaneous fibrous tissue, and especially the papillary layer, has become necrosed under the stress of the initial inflammation (Fig. 146 l_1). The gap thus produced is never completely repaired, and a depressed cicatrix remains; the 'pits' that follow the eruptions of unmodified small-pox afford the best example.

Permanent alterations in the texture of the skin are very common after long-enduring or often-repeated inflammations. They are of the nature of hyperplasia, or of atrophy, of the epidermal and fibrous struc-

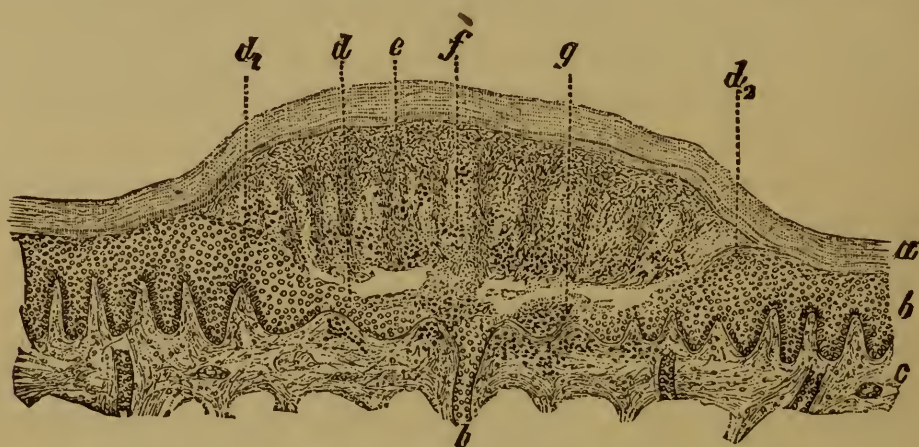


FIG. 149. BLISTER FROM A BURN IN PROCESS OF HEALING.

(Section through the skin of a cat's paw forty-eight hours after a burn: alum-carmine staining, mounted in Canada balsam: $\times 25$.)

- | | |
|--|---------------------------------|
| a, horny layer. | d_2 , new-formed horny layer |
| b, rete Malpighii. | e, the old degenerate epidermis |
| c, corium. | f, pus-corpuscles. |
| d, new-formed epidermal cells, undergoing differentiation into layers at d_1 . | g, secondary exudation. |
| | h, sweat-gland. |

tures. In the latter case the epidermis and corium may be notably thinned, and the papillæ depressed and stunted. Hyperplastic changes leave the epidermis, and especially its horny layer, thickened and condensed, while the papillæ and corium grow larger and stouter. *Pityriasis rubra* (Art. 377) is a good example of a cutaneous inflammation ending in atrophy; the thickening that follows chronic eczema (Arts. 385, 413) illustrates the hyperplastic condition.

More or less permanent pigmentation is another common result of moderately intense inflammation of the skin.

375. **Erysipelas** is an acute inflammation of the integument depending upon traumatic infection; it takes the form of gradually extending redness and swelling accompanied by a certain degree of fever. In the

early stages the skin appears tense and shining and of a bright red tint. Presently it becomes more or less livid or brown, the swelling goes down, and the epidermis is thrown off in scales or flakes.

Sometimes the exudation is more copious and tends towards the surface, in which case vesicles and blebs are formed, and the eruption is described as *erysipelas vesiculosum* or *bullosum* (Fig. 150). When the contents of the vesicles become purulent we have *erysipelas pustulosum*, which, as the pustules dry up into a scab, passes into *erysipelas crustosum*; or, if portions of skin become necrotic or gangrenous, into *erysipelas gangrenosum*.

When examined microscopically the erysipelatous exudation is seen to be abundant, serous or fibrinous (Fig. 150 *m m*₁) and highly cellular, and it infiltrates the entire thickness of the skin and the subcutaneous

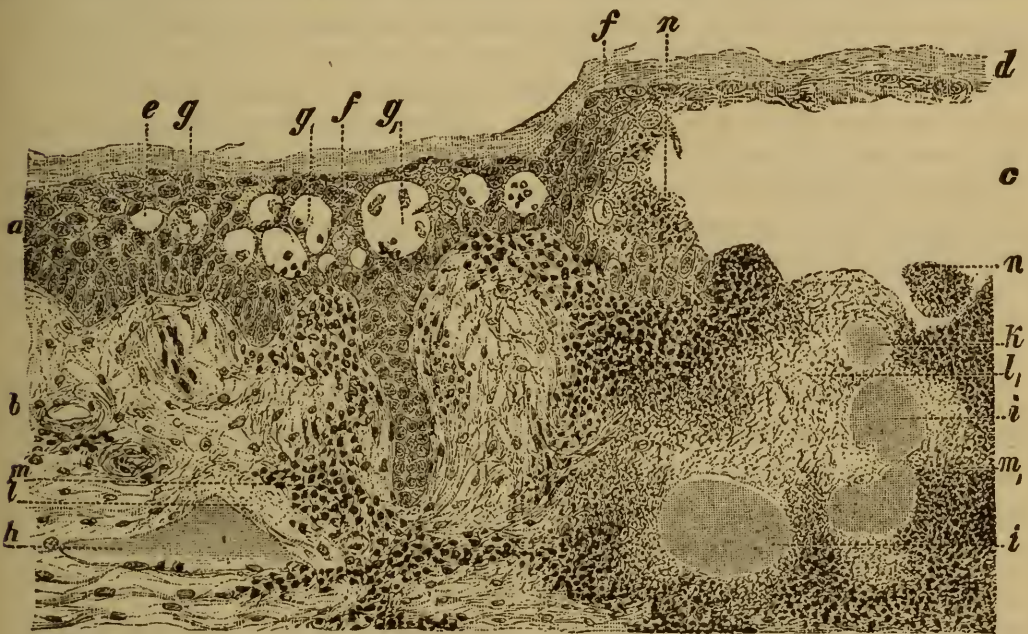

FIG. 150. SECTION OF THE SKIN IN ERYSIPLAS BULLOSUM.

(Alum-carminé staining, mounted in Canada balsam: $\times 60$.)

- | | |
|---|---|
| a, epidermis. | hi, lymphatics filled with micrococci. |
| b, corium. | k, micrococci in the substance of the tissue. |
| c, bleb or bulla. | ll ₁ , necrosed tissue. |
| d, roof of the bleb. | m, cellular infiltration. |
| e, vacuolated epidermal cell. | m ₁ , fibrino-cellular infiltration. |
| f, swollen cell and nucleus. | n, fibrino-cellular exudation within the bleb |
| g, g ₁ , cavities produced by solution of epidermal cells, containing fragments of cells and pus-corpuscles. | |

connective tissue. The vesicles and blebs are formed (Art. 371) by the liquefaction and disintegration of the cells of the rete Malpighii (*e f g*). The liquefaction commences in isolated spots, and thus the first cavities formed are separated by cells which are more or less stretched and distorted; but as the cavities coalesce these septa break down and disappear (*c*).

The originating **cause of erysipelas** is to be sought in an invasion of micrococci (*h i k*), which gain entrance at some wounded part of the skin (Art. 204). They proceed to multiply within the lymphatics (*h*) and at length completely fill them (*i*). From the lymphatics they pass into the connective tissue, where they form coherent masses (*k*) or chaplets. The tissue around these colonies becomes necrotic (*l₁*), and presently inflammatory reaction is set up. The extravasated cells may be scattered irregularly through the tissues, or be arranged in elongated clusters.

The extent of the necrosis is often slight, but at times it reaches a considerable magnitude and leads to serious loss of substance, as in gangrenous erysipelas.

FEHLEISEN published quite recently the results of his experiments on the cultivation and inoculation of the micrococci which constitute the virus of erysipelas (*Sitzungsberichte d. Würzburg. phys.-med. Gesell.* 1882). ZIEGLER (*Naturforscherversammlung in Salzburg* 1881) made inoculative experiments (Art. 204) on rabbits, but they all led to a fatal result. FEHLEISEN while confirming ZIEGLER'S work was able to preserve the animals alive, and to watch the process of repair to its issue in complete recovery. He cultivated the micrococci 'purely' on gelatine impregnated with peptonized meat-infusion, and effected a successful inoculation on the human subject with micrococci of the fourth artificially-cultivated generation; perfectly typical erysipelas was induced. After these experiments the specific significance of the micrococci can hardly be doubted.

376. **Psoriasis** is a chronic disease of the skin characterized by the formation of dry glistening white scales. They are piled upon each other in small heaps, or over large discoid patches, which have a definite red slightly raised base that is easily made to bleed (KAPOSI). The eruption begins in minute brownish-red nodules which in a day or two become covered over with epidermal scales. If the scales are removed a bleeding point appears on the reddened base. When the nodules are numerous and discrete the disease is distinguished as *psoriasis punctata*; where the patches and scales are larger we have *psoriasis guttata* and *psoriasis nummularis*.

As the disease passes away the base becomes pale and the scales are shed; the skin may at once assume its normal appearance or remain pigmented for a time. Often the patches heal in the centre while the margins are still advancing; in this case the affection is named *psoriasis annularis* or *gyrata*. The disease may occur at any spot, but it chiefly affects the region of the knee and elbow, the scalp, and the sacral region. Both the hair and the nails may be destroyed in the course of it.

The histological changes induced by psoriasis relate essentially to the epidermal cells, the papillæ, and the upper strata of the corium. The two latter are more or less densely infiltrated with leucocytes; and when the disease has lasted for some time hyperplasia of the superficial fibrous tissue and the papillæ is usually set up. The morbid process may occa-

sionally extend to the deeper layers of the corium and the subcutaneous connective tissue.

As regards the epidermis, the mucous layer and especially the inter-papillary parts of it appear overgrown. The cornification of the surface layers of the epidermis is interfered with; the cells as they come to the surface appearing simply to shrivel and dry up, while the mutual cohesion of the layers is loosened.

E. LANG (*Viertelj. f. Derm. u. Syph.* 1879, and *Sammlung klin. Vorträge* 208) announced that a fungous growth was always present in the patches of psoriasis; he named it *Epidermidophyton* and regarded it as the exciting cause of the disease. It formed filaments and spores and was found in the deeper layers of the heaps of scales. ZIEGLER has not been able to verify the discovery, having found nothing in the diseased patches but occasional micrococci, and these can hardly be regarded as the specific virus.

On the histology of psoriasis see NEUMANN (*Med. Jahrb.* 1879), R. ROBINSON (*New York Med. Journ.* 1879), JAMIESON (*The histology of psoriasis* Edinburgh 1879), THIN (*Brit. Med. Journ.* 1, 1881).

377. **Pityriasis rubra**, or general exfoliative dermatitis, is a peculiar affection of the entire skin, the only symptoms of which are marked redness and desquamation; neither papules nor vesicles nor pustules are ever formed (KAPOSI). The scales are sometimes small, but they are often of considerable size. After a time the skin becomes smooth, shining, thin, and tense; the hair falls off; and when the disease has lasted for a year or more, general marasmus and death ensue. The only textural change which has yet been made out is a moderate amount of cellular infiltration in the cutis and papillary layer. No special changes occur in the epidermis, apart from those associated with desquamation; though in late stages some small-celled infiltration may be observed in isolated patches. The skin is generally much atrophied, the rete Malpighii being greatly thinned, while the papillæ are dwarfed, and the corium and its fibrous bundles have much the same look as in senile atrophy (Art. 363). The sebaceous glands and hair-follicles are obliterated.

See HEBRA (*Viertelj. f. Derm. u. Syph.* III.), GEBER (*ibid.* III.), FLEISCHMANN (*ibid.* IV.). For cases see DUHRING (*Diseases of the skin* Philadelphia 1882).

378. **Prurigo** is a disease beginning in infancy and generally persisting throughout life. It consists of often-recurring eruptions of miliary nodules or papules, which are pale or pinkish in color, hard and rough to the touch, and accompanied by severe itching. They may be scattered irregularly over the body, but they are often confined to the extensor surfaces of the limbs, the flexor aspects being quite free (KAPOSI). Around the papules there is a certain amount of cellular infiltration derived from the papillary vessels. When the affection has existed for some time the changes in the skin are more marked, and the inevitable scratching sets up eczematous inflammation.

379. **Papular syphilides** are of two chief kinds, distinguished as

the small papular (or miliary) and the large papular (or lenticular) syphilide.

The **small papular syphilide** or syphilitic lichen consists of small nodules of about the size of a pin-head arranged in clusters or rings; as the eruption fades desquamation takes place, and shallow pits remain in the skin.

The **large papular syphilide** consists of sharply-defined hard nodules as large as a hemp-seed or larger, which increases in size by marginal growth. As they fade and desquamate they leave behind pits, which at first are pigmented but afterwards assume a glistening white appearance. Papules are sometimes formed on the palms and soles, and result in membranaceous desquamation: this constitutes what is called palmar or plantar (syphilitic) psoriasis. The separate papules are recognizable in the earlier stages of the affection, but after a time they coalesce, and diffuse infiltration, with callous thickening of the epidermis, is all that appears.

Mucous patches or *condylomata lata* are also classed with the papular syphilides. They are flattened discoid elevations covered with a moist grayish exudation. They develop from originally discrete papules in parts where folds of skin are in contact and keep each other moist, such as the labia, perineum, anus, scrotum, penis, and axilla, and occasionally the mouth.

A section through such a patch shows that the elevation of the skin is due to an infiltration extending (Art. 369) to the epidermis (Fig. 151 *f g h*), as well as into the papillary layer (*i*) and corium (*k*). The exudation consists of leucocytes and fibrin (*h k*), and its presence causes the papillæ to be greatly enlarged and the epidermal layers to be greatly thickened. The latter effect is increased by an increase in the productive activity of the epidermal cells. The patch may disappear by the absorption of the cellular and liquid exudations, and the incrustation and shedding of the diseased epidermis. The swelling first goes down in the middle of the patch, while the margins still remain infiltrated. The affected tissue disintegrates and suppurates, giving rise to an ulcer with infiltrated margins; and as this dries up a crust is formed which is ultimately shed. With reference to the primary syphilitic affection see Art. 391.

The various skin eruptions of syphilis differ remarkably in appearance. A small papular syphilide seems to have little in common with a mucous patch, or a pemphigoid syphilide (Art. 386) with a papular eruption or a hard sore (Art. 391). Yet in all these cases the fundamental processes are closely related, and differ simply in degree and extent. In all of them the essential part of the process is the induction of circumscribed inflammations accompanied by a comparatively abundant cellular exudation. The exudation usually shows no sign of commencing organization, but is either re-absorbed, or cast off with the necrosed and disintegrated tissue in which it lies. Even when the seat of inflammation

attains the form and texture of a patch of granulation-tissue (Art. 391) suppuration and disintegration usually supervene.

The essential element of the syphilitic eruptions is the papule; the consecutive appearance of scales or vesicles or pustules is of secondary importance, as are also the mere size or extent of the affected area.

380. **Lupus erythematosus** is a disease which begins with an eruption of raised red specks or spots (KAPOSI). They are depressed in the centre, or glistening and scar-like, or capped with a thin adherent scale. The reddened margin advances gradually while the centre becomes scarred over, and thus in the course of some months a red-bordered disc

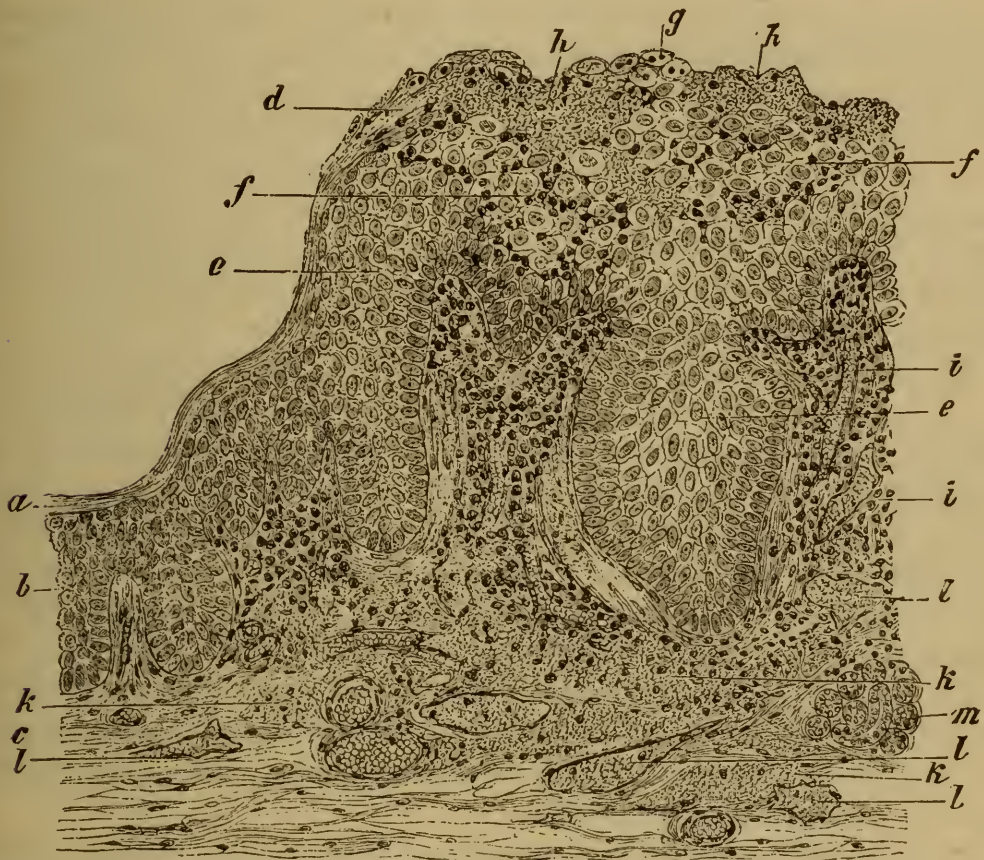

FIG. 151. SECTION THROUGH A SYPHILITIC MUCOUS PATCH.

(Aniline-brown staining: $\times 100$.)

- | | |
|--|---|
| a, horny layer of the epidermis. | g, degenerate epidermal cells, into which leucocytes have penetrated. |
| b, rete Malpighii. | h, granular coagula. |
| c, corium. | i, swollen papilla infiltrated with cells. |
| d, horny layer swollen up and infiltrated with leucocytes. | k, corium infiltrated with cells and fibrin. |
| e, swollen cells of the rete Malpighii. | l, lymphatic vessel. |
| f, swollen epidermis infiltrated with cells. | m, sweat-gland. |

is formed (*lupus erythematosus discoides*). In other cases the disease advances not by the growth of old spots but by the continual development of the new ones (*lupus erythematosus disseminatus*).

The morbid process consists in an inflammation of the cutis, especially in the neighborhood of the sebaceous and sudoriparous glands

(KAPOSI and THIN). The epithelium of the glands multiplies, the epidermis is swollen, and scales and sometimes vesicles are formed on its surface. In the later stages both the epidermal and fibrous constituents of the skin become atrophied.

See HEBRA and KAPOSI (*Diseases of the skin* IV.), GEBER (*Viertelj. f. Derm. u. Syph.* III.), THIN (*Med. chir. Trans.* 1875), STROGANOW (*Cent. f. d. med. Wiss.* 48, 1877).

381. Burns and blisters. When the skin is exposed to the action of **heat** in such a way that the epidermis is killed, while the underlying cutis and its vessels are injured but not killed outright, blisters are formed on the surface; in other words, the skin reddened by congestive hyperæmia is raised into vesicles or blebs containing clear liquid. The changes through which such a blister may pass are various. Usually the lost epidermis is quickly replaced by regenerative growth under cover of the horny shell of the blister (Art. 374, Fig. 149). The exuded liquid disappears by evaporation, and if after a day or two the dry shell of epidermis be removed the denuded surface will be found completely covered with new epidermis, and the injury is indicated only by the bright red tint of the spot.

When irritant matters gain access to the denuded papillary surface, as may happen if the skin of the blister is prematurely removed, the healing process is notably delayed. The exudation of liquid and cells continues for some time longer, the deep-red surface secreting a more or less turbid liquid (catarrhal exudations). But presently this ceases and the epidermis is reproduced. This more protracted process of repair is to be looked for when the injury caused by the burn extends to the papillæ and deeper layers of the cutis.

The blisters caused by **cantharides** are of much the same character, but the swelling and solution of epidermis is usually less sudden and less extensive. Denucleated continuous masses are sometimes formed from the necrosed epidermal cells.

We may perhaps remind the student that burns may be of very different degrees of severity. It is sufficient for most purposes to distinguish three degrees. In the first there is merely erythematous reddening of the skin; in the second blisters are formed; in the third some portions of the fibrous structures are destroyed (Art. 389). Many transitional grades exist between these: for example, in burns of the second degree it often happens that not all of the epidermal layers become necrotic, but only the surface layers. Accordingly the general course of the process and the accompanying series of textural changes will vary in different cases. The solution of the epidermal cells in the exuded liquid is in fact seldom so complete or so general as might be inferred from the text, and the surviving cells may be strangely distorted and displaced (Art. 371). When the injury is very severe, so that inflammation of the denuded structures persists for some time, pus-corpuscles may be found not only in the surface strata, but also in the fibrous structures beneath.

382. Miliaria crystallina or **sudamina** are small watery vesicles

covered by a delicate film of epidermis, which sometimes appear in the course of puerperal fevers, typhoid, acute rheumatism, etc., and last for a few days. They occur chiefly on the trunk. In this as in other vesicular eruptions, the epidermal cells are partly dissolved, the solution being preceded by serous infiltration of the papillæ as well as of the epidermis. After a short time the epidermis is reproduced beneath the vesicle, whose contents are at first mainly liquid but afterwards contain cells. When a new horny layer is formed the contents are enclosed as it were between two shells. The cellular infiltration of the corium persists for some time, the lymphatics especially continuing to retain the extravasated cells with which they are filled.

383. **Herpes** is an acute affection running a typical course (KAPOSI) characterized by the formation of clusters of watery vesicles on certain parts or regions of the body, and passing through a definite cycle of stages within a short period of time.

The eruption first appears as a group of minute papular elevations of the skin, which rapidly become infiltrated with watery serum and become vesicles. This is the climax of the process: the vesicles last one to four days and then dry up into crusts. Beneath the crusts regenerative proliferation of the epidermis takes place, the lost tissue is thus made good, and the crusts are gradually loosened and cast off.

The vesicles of herpes take their rise in the deeper layers of the rete Malpighii; its cells swell up and become vacuolated (Art. 371), or become compressed and distorted as the exudation accumulates.

The contents of the vesicles consist of serum, fibrinous coagula, and pus-corpuscles, the latter especially in the later stages. The papillæ are infiltrated more or less intensely with serous liquid and leucocytes, and occasionally hemorrhage takes place. Sometimes this may lead to the destruction a few of the papillæ, and then a scar is left after the eruption passes away.

Five forms of herpes are distinguished according to their seat and mode of origin.

(1) **Herpes zoster** (*zona* or shingles) is an eruption of vesicles clustered over the area supplied by a cutaneous nerve; it is almost always unilateral. The contents of the vesicles remain clear for three or four days, then they become turbid and purulent. Yellowish-brown crusts are formed as the vesicles dry up. Sometimes hemorrhage takes place into the vesicles.

BRIGHT (*Medical Cases* II. London 1831) suggested the connection of the eruption with disorder of a sentient nerve, and BÄRENSPRUNG (*Charité Annalen* IX., XI., *Brit. For. Med. Chir. Rev.* 1862) demonstrated the fact, and showed that simultaneous changes sometimes occur in the spinal ganglia and Gasserian ganglion. RAYER, WEIDNER, E. WAGNER, CHARCOT, KAPOSI, BOHN, E. LESSER, NEUMANN, and others have verified the observation, and have shown that affections of the cord and of the peripheral nerves may give rise to vesicular eruptions. The nerve-affections referred to are partly primary, partly secondary to some affection in their neighborhood or to some mechanical injury. The morbid

change is generally of the nature of inflammation or hæmorrhage, in consequence of which nerve-fibres and ganglion cells are injured or destroyed.

References: KAPOSI, *Wien. med. Woch.* 1874, 1875, 1877, *Lond. Med. Record* 1876; BOHN, *Jahrb. f. Kinderheilk.* II. (1869); CHARCOT *Diseases of the Nervous System* vol. I. (New Syd. Soc.) 1877; HAIGHT, *Sitzungsber. d. k. Wien. Akad.* 1868; WEIDNER, *Berl. klin. Woch.* 7, 1870; WAGNER, *Arch. d. Heilk.* XI.; WYSS; *ibid.* XII.; E. LESSER, *Virch. Arch.* vol. 86; NEUMANN, *Lehrb. d. Hautkrank.* Vienna 1880; ROSS, *Diseases of the Nervous System* I. London 1883.

(2) **Herpes labialis** (*facialis*) is an acute eruption of vesicles on the lips or around the mouth and nostrils. The vesicles last two or three days and dry up under a crust, without scarring. Its cause is unknown, but it is very often observed in connection with pneumonia and intermittent fever, and more rarely in typhoid.

(3) **Herpes progenitalis** (*præputialis*) affects the penis, clitoris, or labia; its course is similar to that of herpes labialis.

(4) **Herpes iris** and **herpes circinatus** are according to KAPOSI the same as erythema iris and circinatus (Art. 367). The vesicles occur on the back of the hands or feet and form separate or concentric circles; they fade after eight or ten days.

(5) **Herpes tonsurans vesiculosis** is a special form of tinea (*herpes*) tonsurans (Art. 411), an affection caused by a vegetable parasite. Circles of vesicles of various sizes are formed by successive marginal crops starting from a centre; the older vesicles dry up as new ones develop.

384. **Pemphigus** is an eruption characterized by the formation of vesicles and blebs varying in size from that of a small pea to that of a goose's egg. The vesicles are usually preceded by red spots and wheals, but they may rise on what seems unaltered skin. The contents are at first clear and watery, or it may be slightly blood-stained; but afterwards they become turbid and purulent. The exudation at length dries up and crusts are formed, under which the lost epidermis is reproduced (*pemphigus vulgaris*). In other cases the regeneration of the epidermis does not at once take place, and the separation of the epidermal layer covering the bleb extends, so that at length a large area of the corium may be denuded (*pemphigus foliaceus*). When the skin of the bleb is removed the exposed surface is red and moist until a crust is formed from the superficial exudations. In such cases the corium is always more or less infiltrated, and sometimes it may in part become necrotic and break down (*pemphigus malignus* and *diphtheriticus*). Granulations are then produced, but they too are very liable to necrosis (KAPOSI).

The smaller vesicles are usually loculated, the large blebs are single. The under-surface of the epidermal shell of the bleb is often beset with epithelial projections, which have been pulled out of the tubes of the hair-follicles.

Four chief forms of pemphigus are distinguished according to their clinical characters (KAPOSI).

(1) **Pemphigus acutus** is an acute affection manifested by an eruption of scattered blebs, with or without fever. The blebs last a few hours and then dry up into crusts. When these fall off the corium is covered with new epidermis, and the attack is at an end.

(2) **Pemphigus chronicus vulgaris** is characterized by the formation of large tense blebs, accompanied by a certain amount of fever. The eruption take place by successive crops. According to the mode in which the blebs are grouped, we have *pemphigus disseminatus* (scattered irregularly), *pemphigus confertus* (closely aggregated), *pemphigus circinatus* (in circles), and *pemphigus gyratus* or *serpiginosus* (in convoluted or undulating lines). The disease lasts from two to six months, and sometimes ends fatally. GIBLER (*Gaz. de Paris* 1881) asserts that febrile pemphigus is a bacterial affection.

(3) **Pemphigus foliaceus** is the severest form of the disease. It is distinguished by its progressive character and the imperfect way in which the lost epidermis is reproduced. After months or years the entire surface of the body may be affected. The skin is then in places brown and parchment-like, in others red and weeping; the spots are covered with crusts and fissured in various ways.

(4) **Pemphigus syphiliticus** is considered in Art. 386.

385. **Eczema** is a skin-disease which may be acute or chronic; the eruption consists of papules, vesicles, or pustules; the skin is more or less reddened and swollen, and desquamates, or "weeps," or is covered with large continuous scabs. Eczema is set up by external irritation. When the irritation is slight the eruption consists of small papules, and thus *eczema papulosum* is the mildest variety. Somewhat more intense irritation causes small vesicles to arise, and we have *eczema vesiculosum*; when the vesicles dry up they are cast off as scales. If the irritation is still more intense or the skin highly susceptible, a considerable area becomes painfully red and swollen (*eczema erythematosum*). On this vesicles arise, which are at first clear but soon become purulent (*eczema pustulosum*). When the upper shell of the vesicles is removed (as by scratching) the exposed surface pours out liquid and is said to 'weep' (*eczema madidans*). The epidermic surface deprived of its horny layer by desquamation or otherwise has often a deep-red tint (*eczema rubrum*). Crusts are formed by the evaporation of the sero-purulent exudation poured out on the surface (*eczema crustosum*), and pus sometimes gathers beneath the crusts (*eczema impetiginosum*). In other instances new epidermis is formed beneath the crusts; when the crusts are cast off the surface then looks red and brawny and scales are freely shed (*eczema squamosum*). As the disease disappears the skin gradually recovers its normal appearance, though some slight pigmentation often remains (KAPOSI). An eczematous eruption consisting of pustules of the size of a small pea, and drying into scabs without rupturing, is often described as **impetigo**. Much larger pustules, seated on an inflamed and reddened base and drying into brown scabs, constitute **ecthyma**. **Impetigo contagiosa** is a contagious eczematous eruption (TILBURY FOX, *Brit. Med. Journ.* 1864; UNNA, *Viertelj. f. Derm. u. Syph.* VII.). It chiefly attacks ill-fed or weakly children, and affects the head and limbs: vesicles as big as a cherry-stone arise on a reddened base, and presently dry up into yellow crusts.

The inflammatory process in eczema is often chronic, and the skin is

then beset with vesicles, pustules, scales, and scabs, all at the same time.

The textural changes in the cutis consist of serous and cellular infiltrations of the fibrous tissue. The cellular infiltration is especially dense in the pustular and impetiginous varieties, and the subcutaneous tissues are often infiltrated in the same way.

As regards the epidermis, some of the cells of its mucous layer perish in the vesicular stage, and some are compressed and stretched into fusiform or other shapes. The liquid exudation contains numbers of leucocytes, which are found not only in the vesicles but also scattered among the unaltered epidermal cells, and even in their interior. In many cases the epidermis perishes outright, and even the papillæ may be destroyed when the inflammation becomes suppurative (*eczema impetiginosum*).

The after-effects of eczema are various. Slighter forms leave no trace behind, the skin being restored *ad integrum*. If the papillæ have been injured or destroyed they are not replaced, and a cicatrix is produced. Chronic eczema gives rise to pigmentation, and to hypertrophy of both epidermis and corium: when the hypertrophy is great the skin appears thick and dense as in elephantiasis; when the papillæ are likewise enlarged the surface becomes warty and tuberculated. Hypertrophy of the epidermis being generally accompanied by the formation of plates, scales, and flakes, an appearance recalling that of elephantiasis combined with ichthyosis is produced (Arts. 394, 396 and 413). So long as the inflammation persists the hypertrophied fibrous tissue is thickly beset with clusters of young leucocytes. They are occasionally aggregated into nodules containing giant-cells.

386. The **pustular syphilide** follows upon the papular form (Art. 379) by the development of pustules above the papules. Small pustular and large pustular varieties may be distinguished. The latter are often described as syphilitic variola, acne, or impetigo. The pustules are surrounded by a red infiltrated raised border. When the papules and pustules grow to any considerable size the eruption is described as *pemphigus syphiliticus*, and when these harden into crusts they form *rupia syphilitica*.

The **syphilitic pemphigus of infants** (Fig. 152) calls for special mention. It occurs chiefly on the limbs of infants suffering from congenital syphilis, and may appear at birth or in the first few weeks of life. The vesicles arise in the same way as other inflammatory vesicles, by the destruction and solution of the cells of the mucous layer. But the affection is distinguished by the fact that the floor of the vesicles and blebs is occupied by large-celled vascular granulation-tissue (*i*) developed from the cutis and papillæ.

Infantile syphilitic pemphigus is not strictly one of the group of affections we are now discussing. It differs from them inasmuch as it includes the formation not only of an inflammatory exudation, but also of new-formed vascular granu-

lation-tissue. It has been mentioned in this place because its appearance to the naked eye so closely resembles that of the other phlyctænoses.

387. **Small-pox** or *variola* is a general febrile disease characterized by the eruption of papules, vesicles, and pustules, and caused by the the infection of the system with variolous poison. After a certain inter- from the time of infection the skin becomes suddenly beset with hard red papules of the size of a pin-head, surrounded by a red areola. Some of the papules enlarge and change into clear vesicles most of which are umbilicated, *i. e.* depressed in the centre. In two or three days the contents of the vesicles become turbid, and the vesicle becomes a pustule. At the same time the umbilication usually disappears, and a zone of intense hyperæmia is formed around the pustule. In three or four days it dries to a brownish scab, and this in a few days more falls off, leaving

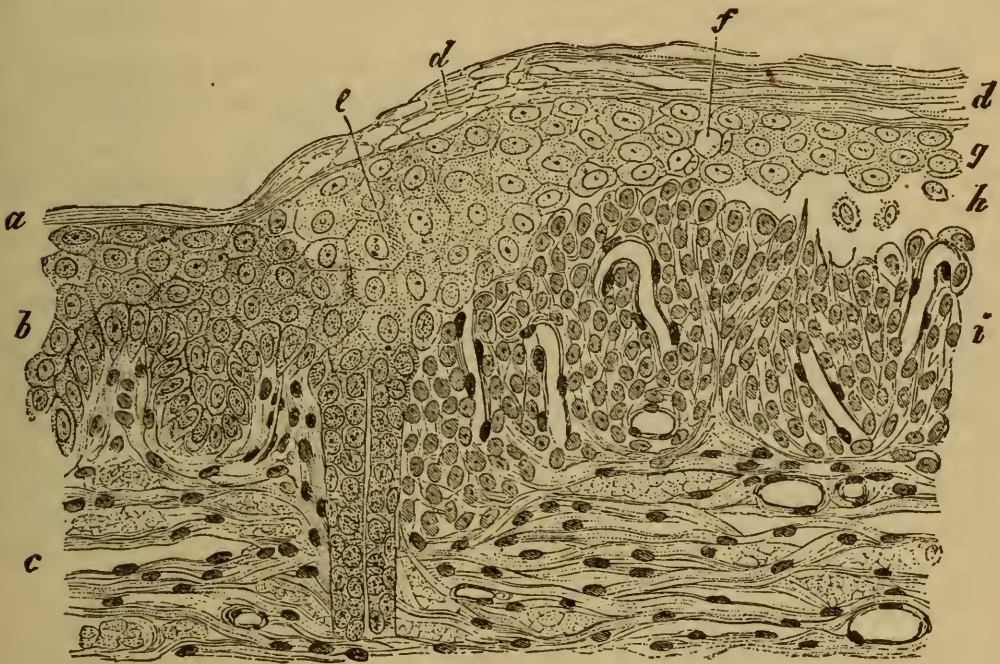


FIG. 152. INFANTILE SYPHILITIC PEMPHIGUS.

(Section through the margin of a vesicle: hæmatoxylin staining: $\times 200$.)

- | | |
|--|---|
| <p><i>a</i>, normal horny layer of the epidermis.
 <i>b</i>, normal rete Malpighii.
 <i>c</i>, corium.
 <i>d</i>, swollen and desquamating horny layer.
 <i>e</i>, swollen cells of the rete.
 <i>f</i>, vacuolated epidermal cells.</p> | <p><i>g</i>, remnants of the rete compressed by the contents of the vesicle.
 <i>h</i>, vesicle produced by the destruction of the deeper layers of the rete.
 <i>i</i>, granulations arising from the cutis and papillæ.</p> |
|--|---|

behind a slightly pitted spot, which may be red or brown or white in color; in a short time the spot also disappears.

Frequently however the course of the disease is much less favorable. Some of the pustules do not heal up without cicatrization, so that scar-like pits are left which at first are dark-red, but afterwards are white and permanent. This is especially the case when hæmorrhage takes place into the pustule, or when the eruption is so copious that the pustules run

together (confluent small-pox). The skin appears rough and tuberculated and is much swollen. When the cap of the pustule is forced off by the accumulating pus within, the suppurating corium is laid bare, and parts of it may become necrosed or gangrenous. The affected spots have a dirty gray or black tinge.

The variety distinguished as hæmorrhagic or black small-pox (*variola hæmorrhagica* or *purpura variolosa*, Art. 361) is remarkable for the dark-red color which overspreads the entire surface of the body as the fever sets in. Patches of hæmorrhage appear, and soon enlarge in an astonishing way. Death ensues in a few days, and on post-mortem examination hæmorrhages are found in various internal organs. In other cases a multitude of small hard papules appear on the skin, which is intensely swollen but not necessarily discolored; hæmorrhagic patches follow in one or two days, and speedily coalesce into larger ones. This form also is apt to end fatally.

388. The histological changes observed during the evolution of the variolous pustule have already been partially treated in Arts. 371 and 372. The first change is the swelling up of the cells of the mucous layer of the epidermis immediately over the tips of the papillæ. WEIGERT has shown that the swollen cells are transformed into pale denucleated masses resembling coagula. This is followed by complete necrosis and solution of the affected cells in the exudation which at this stage is poured out from the papillary vessels, while the degenerative swelling and change extend on all sides. Only small portions of the epidermal tissue withstand solution, and these are chiefly cell-membranes, or degenerate denucleated or sometimes nucleated masses representing coagulated cells; these are stretched and compressed by the accumulating exudation into bands and threads and partial septa crossing the excavations in the epidermis.

Thus at the climax of the process the pock or vesicle consists of a cavity traversed by shreds of membrane and fibres and distorted cells (Fig. 153 *f*) covered at its highest part by the horny layer only (*i*), but towards its margins by some of the surface layers of the epidermis as well. The floor of the cavity is formed of remnants of the inter-papillary portion of the rete Malpighii (*g*), and in part of denuded papillæ (*h*). The papillæ and the upper layers of the cutis are swollen and beset with leucocytes; and the liquid contents of the vesicle already contain numerous free cells and pus-corpuscles (*f*₁).

As the pock becomes a pustule the number of pus-corpuscles which pass into the cavity from the papillary vessels increases, and the shreds and septa break down. The pustule dries into a crust, the infiltrated cells are re-absorbed, and repair begins under the crust starting from the margins where the epidermal cells are uninjured.

A pock like that in Fig. 153 leaves no scar behind it, as nothing is destroyed which is not completely replaced. When the inflammation is

more intense the process of healing is different, inasmuch as the papillæ themselves break down or suppurate. Complete repair is no longer possible, and the site of the pock is marked by a cicatricial depression (**pock-mark** or **pit**). A pock in which the papillary layer suppurates is sometimes called a diphtheritic pock.

Recent researches have made it probable that small-pox is due to the invasion of a specific bacterium (Art. 204). WEIGERT (*Anat. Beiträge zur Lehre von den Pocken* Breslau 1874) thinks the first effect of the virus is to produce necrosis of the epidermal cells, and that all the other phenomena are due to the reaction set up in consequence of this necrosis. This view seems somewhat one-sided. Even if we grant that the virus has a destructive action on the epidermis, there appears no reason to doubt that it has also an injurious effect upon the vessels, producing in their walls the alterations which lead to the phenomena of inflammation. The early appearance of the exudation is in favor of such an inference, and the epidermal changes above described follow naturally upon the exudation.

UNNA'S statement (*Virch. Arch.* vol. 69)--that the pock is seated on the deep-

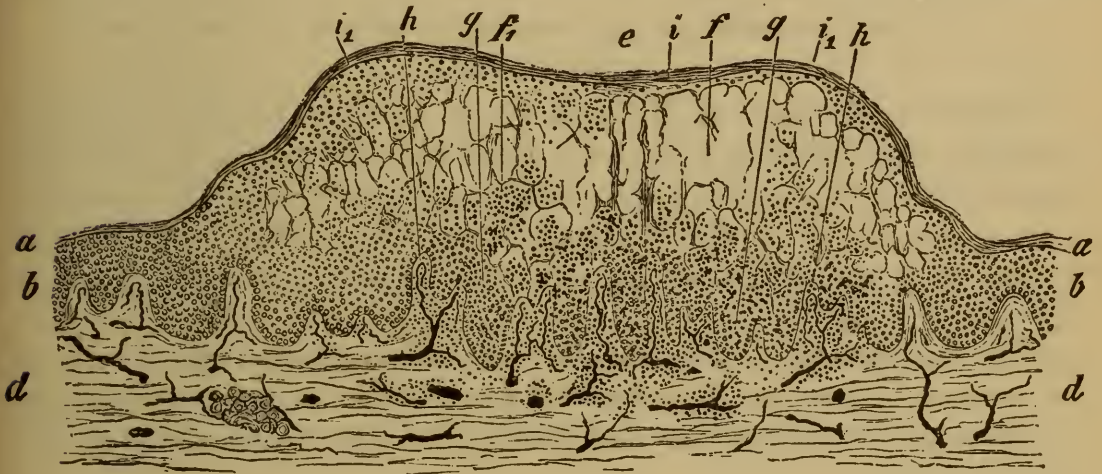

FIG. 153. SECTION OF A VARIOLOUS VESICLE BECOMING PUSTULAR.

(Injected preparation, stained with hæmatoxylin: $\times 25$.)

- | | |
|---|---|
| a, horny layer. | h papilla infiltrated with leucocytes. |
| b, mucous layer. | i, umbilication over the thinnest part of the cap of the vesicle. |
| d, cutis. | i ₁ , margins of the vesicle, where the cap consists of several layers of epidermis. |
| e, vesicle. | |
| f, cavity of the vesicle. | |
| f ₁ , pus corpuscles. | |
| g, fragments of epidermal cells interspersed with pus-corpuscles. | |

est or basal stratum (*stratum lucidum*) of the horny layer—ZIEGLER has not been able to confirm: but their researches were not carried out on the same part of the body. ZIEGLER found that the vesicles were seated above the rete Malpighii only in cases where a certain amount of regenerative epidermal proliferation had taken place on the floor of the cavity. The mode in which this would tend to raise the pock towards the surface has been pointed out in Art. 374 (Fig. 149). Fig. 153 shows how the regenerative growth of the epidermis near the papilla *b* on the left margin tends to thrust the vesicle upwards.

The umbilication of the vesicle has given rise to some controversy. RIND-
FLEISCH (*Pathological Histology* vol. I. London 1872) and HEBRA (*Diseases of the*

skin 1.) think the roof of the cavity is held down by the persistence of the tubes of the hair-follicles and sweat-glands. AUSPITZ and BASCH (*Virch. Arch.* vol. 28) maintain that the distention of the middle parts by the exudation does not keep pace with the elevation of the margins by infiltrative swelling. WEIGERT states that the shreds and partial septa which cross the cavity suffice to hold down the cap in its centre. Probably both the factors emphasized by the latter authors come into play.

The vesicles of *vaccinia*, produced by vaccination, have the same structure and pass through the same stages as the variolous vesicle. The eruption does not tend to become general.

Chicken-pox or *varicella* is a febrile disease characterized by eruptions of vesicles in successive crops, and caused by a specific contagion. The vesicles start in rosy slightly raised spots, which speedily become infiltrated and distended with a clear liquid; they are usually surrounded by a reddened areola. They may be as large as a split pea, and are sometimes umbilicated. In a day or two their contents become turbid, and then they rupture or dry up into dark adherent scabs. As the scab separates a reddish stain is left, which usually disappears in a few days.

c. Eruptions ending in necrosis, suppuration, ulceration, or granulation.

389. The affections of the skin which we have hitherto discussed have been inflammations either of a transient kind ending in complete recovery, or such as produce sensible changes of structure but not complete destruction of the skin. Only as a rare exception do they give rise to loss of substance calling for repair by granulations and cicatricial tissue.

The processes now to be described are inflammations which issue in suppuration or necrosis of portions of the integument, and to which the development of granulations and cicatricial tissue is the ordinary and typical sequel.

The injurious agencies which induce the skin-affections of this group are in part the same as those concerned in the less grave affections; but much more frequently they belong to a special and peculiar class, namely the class of specific contagia or infective poisons. The differences in the intensity of the inflammatory processes set up are in part due to differences of predisposition in the patient, and in part to differences in the intensity of the injury or the virulence of the poison. A typical example of the first is afforded by small-pox, which in 'protected' patients, that is in patients with but slight predisposition to the disease, runs a mild course without any marked after-effects: in unprotected or predisposed patients the inflammation set up leads to extensive and permanent destruction of the skin. An obvious example of the increase of the effect with increase in the intensity of the injurious agency is afforded by burns of the third degree (Art. 381). In such burns the epidermis, the cutis, and perhaps the subcutaneous tissue are destroyed or killed: intense inflammation then ensues, by which the dead tissue is gradually separated from the living. Granulations are developed in the

form of fleshy upgrowths from the floor of the wound, and from them scar-tissue is elaborated, which may become more or less completely covered over with new epidermis growing from its margins. The scar is smooth and devoid of any regular papillæ; and it soon becomes vascular and therefore red in tint. After a time however many of the vessels shrivel up, the tissue becomes pale, contracts, and forms a white tense puckered cicatrix. When the loss of substance caused by the original burn is extensive, the contraction of the scar may be so great that the function of the part (a limb, for example) may be seriously interfered with.

The general effects of high temperatures are also produced by much lower temperatures, the difference being rather one of extent and degree than of kind. The inflammation induced may be slight and transient, and may lead to necrosis of small portions of the integument. The necrosis is followed by a definite inflammation by which the dead tissue is separated, and then granulations and cicatricial tissue are formed.

Many corrosive chemicals act like high temperatures, and the effects of mechanical injury are often graduated in much the same fashion according to the intensity of the injury. Thus cuts and wounds which heal up without loss of substance may be distinguished from those in which deficiency or destruction of tissue requires to be made good by the development of a bulky cicatrix (Arts. 106-111).

It need hardly be said that the above account by no means exhausts the ways in which external injury may affect the skin. In speaking of temperatures we have had in mind only the direct effects of short exposure to somewhat high and somewhat low temperatures. But it is well known that exposure to temperatures differing little from the normal may produce notable effects on the skin if it is long continued or frequently repeated. Repeated cooling of the feet and hands gives rise in susceptible patients to what are called **chilblains** (*pernioles*), that is to livid swellings of the skin due to inflammatory exudation and often passing into suppuration. Similar remarks apply to many other varieties of injurious agency.

390. Of the cutaneous inflammations leading to suppuration and necrosis which have received special names (on account of their peculiar course or mode of origin) we must in the first place mention two—namely phlegmon or phlegmonous inflammation, and malignant pustule.

Phlegmonous inflammation or cellulitis is due to the invasion of a micrococcus (Art. 204) which enters the cutaneous tissues at some wounded spot. In the living patient or after death the affected skin is intensely reddened and swollen. The swelling is due to an abundant infiltration of sero-purulent, fibrino-purulent, or simply purulent liquid in the spaces of the cutaneous and especially the subcutaneous tissues. In recent cases the micrococci are also to be found in these tissue.

The violent inflammation set up and the consequent disturbance of the circulation lead to the death of the tissues over a greater or smaller

area, and extensive suppuration results. Collections of pus, or **phlegmonous abscesses**, are thus formed in the skin and subcutaneous tissue, and they contain shreds and fragments of necrosed tissue.

Phlegmonous inflammation chiefly occurs in the limbs. A special variety attacks the phalanges of the fingers and leads to an extremely painful swelling with partial suppuration: it is called **whitlow** (*panarium* or *paronychia tendinosa*).

Malignant pustule or **specific anthrax** is an affection caused by the invasion of the *Bacillus anthracis* (Arts. 186, 206). It almost always attacks parts that are habitually uncovered, and especially the face. In the skin it begins with redness and swelling which spread from the site of infection. This last soon becomes gangrenous and is often surrounded by a ring of dark or livid blebs; a small umbilicated bleb sometimes covers the site itself. Now and then large tumor-like swellings arise, whose general configuration is that of a magnified pock (КОЧ), the umbilicated summit being dark-colored and the margin formed by a yellowish circular elevation. When the blackened epidermal cap is cast off a clear liquid is poured out from the diseased tissue: no pus is ever formed. The swelling is due to sero-fibrinous and cellular exudation. The neighboring lymphatics and glands speedily become affected.

An affection of the skin resembling that due to anthrax may be caused by an invasion of micrococci, the infection starting as in anthrax from some small surface wound. Occasionally it may be caused by the sting of an infected insect. The intensity and extent of the swelling is usually greater than in anthrax, and gangrene sets in around the site of infection. After the necrosed tissue is cast off the wound may cicatrize; but occasionally fatal blood-poisoning is induced.

Another allied form, also due to bacteria, is the so-called **hospital gangrene**. It is a traumatic infective disease which may attack any wound, but is most apt to occur in connection with minor surface wounds like those due to cupping or leech-bites. The micrococcus which causes it is specific. The infected wound assumes a dirty yellow or gray tint and becomes gangrenous. When the wound contains granulations they become discolored and change into a yellowish creamy pulp which speedily breaks down and liquefies, and the wound secretes a putrid serous or sanious liquid.

Gangrenous bed-sores are not to be confounded with specific hospital gangrene. They occur in emaciated patients with feeble circulation. Very slight pressure is therefore enough to cause necrosis of the skin. The affected parts are livid or black, and under the influence of ordinary septic organisms become putrid and break down. The commonest sites of such bed-sores are over the sacrum, great trochanter, and heel. They often extend through the skin to the tissues lying beneath.

Cadaveric poison (so-called) is apt to induce grave inflammation leading to suppuration and necrosis. The affection normally continues as a

local one, painful redness and swelling are set up round the infected spot, and these are followed by suppuration. In other instances the inflammation becomes diffuse and phlegmonous, or lymphangitis is set up in connection with the local affection (Art. 314). When it becomes chronic, hyperplasia of the skin with enlargement of the papillæ and thickening of the epidermis is produced. The knotty and tuberculated projections thus formed are spoken of as necrogenic or 'dissecting-room' warts.

391. Ulcers of the skin. A cutaneous ulcer is an open wound extending to the cutis, the tissues of the floor and margins being infiltrated with inflammatory products and undergoing progressive molecular disintegration. Many ulcers have granulations covering their floors, which however show no great tendency to cicatrization.

Ulcers vary greatly in their outward appearance. Usually the floor is covered with a grayish film consisting of pus and necrotic tissue. The surface of the floor may be smooth, or nodulated, or irregularly excavated. The edges may be raised or undermined, or abrupt and sharply cut or sloping; they may be regularly rounded or sinuous or serrated. The surrounding parts may be intensely red and swollen or altogether unaltered, they may be hard and densely infiltrated or soft and œdematous. The liquid exuded from the surface may be scanty or abundant, limpid or thick and creamy. Crusts or gum-like pellicles are often formed as the exudation dries, or the ulcer may be covered over with a dirty-looking diphtheritic film.

An ulcer is generally the result of necrosis befalling a portion of skin which has previously been infiltrated with inflammatory products. The progressive disintegration of tissue, in consequence of which the ulcer grows in size, depends either on something in the nature of the tissue, or on the character of the injurious agent which sets up the inflammation; the latter being the more frequent factor.

The following varieties are distinguished by their special mode of origin.

(1) **The varicose ulcer.** This is primarily due to engorgement and dilatation of cutaneous veins and consequent œdematous infiltration of the tissues: comparatively slight injury is then enough to induce abundant cellular infiltration, and this passes into suppuration and necrosis. The ulcer granulates readily, but does not heal so long as the exciting cause persists. Not only does it fail to 'skin over,' but it often continues to extend over the surface and may reach an enormous size. The surrounding fibrous tissues become thickened in consequence of the long-standing œdema and the formation of new tissue. The granulations have no special characters, and may be scanty or exuberant ('proud flesh').

The epidermis bordering on the granulations often thrusts in prolongations and off-shoots into the midst of them, but does not advance

regularly over their surface. The tissues around and underlying the ulcer usually show signs of persistent engorgement, such as cyanotic discoloration, desquamation of the epidermis, dilated veins, œdematous infiltration, etc. The leg and foot are the commonest sites.

(2) **The soft chancre or chancroid.** This is a contagious localized venereal affection, beginning some twenty-four hours after infection as a vesicle or pustule, and rapidly becoming an ulcer with a yellowish base and reddened border. It grows by progressive molecular death of the border-tissue. The edges and base are at first thickly infiltrated with cells, and these as they near the surface pass through successive stages of degeneration and decay, and at length form a layer of structureless detritus. A soft chancre may give rise to lymphangitis and bubo, but not to syphilitic disease.

(3) **The hard chancre.** When a patient is infected simultaneously with the venereal poison which gives rise to soft chancre and with syphilis, the base of the soft chancre becomes indurated about the third or fourth week after infection. The soft chancre is thus converted into a hard chancre. If the soft chancre has healed quickly the characteristic induration appears in the cicatrix.

When syphilis is communicated without the simple venereal poison the first thing seen is a papule, which appears in the third or fourth week after infection. The papule extends laterally, and in eight or ten days becomes scaly or breaks down into an ulcer secreting a small quantity of serous or slightly puriform liquid, which presently dries up into a crust or scab. At the same time the base becomes indurated and forms a definite cartilaginous or parchment-like disc under the skin. This indurated sore is described as the initial sclerosis of syphilis, or the true **Hunterian chancre**. It is due to a dense cellular infiltration of the integument, without any very special histological features. CORNIL'S statement (*Leçons sur la Syphilis* Paris 1879, *Syphilis* London 1882) that the indurated tissue is infiltrated to an extreme degree is correct; but infiltrations quite as intense are met with in other forms of granulo-matous ulcer—notably in tuberculous affections. The reason why the infiltrated tissue is so hard seems to be—that the fibres of the connective tissue persist unchanged for a considerable time, while in the soft sore they very speedily break down.

The infiltrated cells are at first uniformly small, but in the later stages they are larger, epithelioid, and often multinuclear (Art. 128). The induration sooner or later disappears, the parchment-like form being the first to go. If no ulcer has been formed, a scar-like unpigmented spot is left behind; if an ulcer has been formed a regular scar takes its place.

(4) **The gummatous ulcer.** Gummata of the skin (the papular or tubercular syphilide) may give rise to a second variety of syphilitic ulceration. Nodes of various sizes are formed in the skin or subcutaneous tissue, and are either reabsorbed or break down and ulcerate, the ulcers

having indurated bases and edges, and often spreading over a wide extent. When the secretion as it dries forms a thick raised crust over the sore, the affection is described as syphilitic **rupia**. It is characterized by its infiltrated border. For the structure of gummata see Arts. 129 and 130.

(5) **The scrofulous ulcer.** This begins with the formation of cellular nodes or nodules which appear in the skin or subcutaneous tissue. They are simply foci of cellular infiltration, and greatly resemble gummata in the initial stage. They occur chiefly in children. As they break down they give rise to indefinite ulcers with soft œdematous borders, which bleed very readily and secrete a creamy pus. Similar ulcers are formed when subcutaneous lymphatic glands break down and suppurate.

(6) **The true tuberculous ulcer** of the skin is very rare. In diagnosing it we have to depend on the presence of undoubted tubercles in the base of the ulcer or in the surrounding tissue.

We mentioned in Art. 206 that KLEBS had discovered small bacilli in excised portions of hard chancres. AUFRECHT on the other hand found micrococci in syphilitic mucous patches (*Cent. f. d. med. Wiss.* 13, 1881). BEKMANN (*New York Med. Journ.* Dec. 1880) describes micrococci and bacteria in the lymphatics around the initial sclerosis. BIRCH-HIRSCHFELD has recently announced (*Cent. f. d. med. Wiss.* 44, 1882) that not only the primary sore but also the gummatus nodes contain small bacilli (1 microm. in length), some lying free in the tissues, others enclosed in cells. He considers these to be the vehicle of the syphilitic contagion.

Tuberculosis of the skin appears in the form of ulcers, and of nodes and nodular clusters of cells. It is very questionable whether all cellular nodes and ulcers containing tubercles are produced by the action of the tuberculous virus. In this connection it must be remembered that lupous granulations also contain tubercular aggregations of cells. On cutaneous tuberculosis see KÖSTER (*Cent. f. d. med. Wiss.* 1873); FRIEDLÄNDER (*Samm. klin. Voträge* 64, *Virch. Arch.* vol. 60); BIZZOZERO (*Giorn. d. acad. di med. e. chir.* 1874); BRODOWSKI (*Virch. Arch.* vol. 63); CHIARI (*Wiener med. Jahrb.* 1877, *Viertelj. f. Derm. u. Syph.* VI.); HALL (*Ueb. Tuberculose d. Haut* In. Diss. Bonn 1879).

392. Granulation-tissue may (as we have seen) be produced in many ways and as the result of very various processes. All inflammations which involve destruction of tissue may give rise to it in the process of healing and cicatrization. Sometimes however the granulations become as it were redundant, and do not pass into the stage of cicatrization. In this way they may take on a quasi-independent character and form tumor-like aggregations of considerable size, the so-called granulomata. Non-specific inflammations, such as eczema, may be followed by such granulomatous overgrowth; but it is in general associated with certain specific infections, and the growths are therefore referred to as the infective granulomata. We have already partially considered them in Arts. 128-135, and the tubercular syphilitic or gummatus ulcer of the skin has been mentioned in Art. 391. Here therefore there is little further to say about the group in general.

Lupus is a skin-affection characterized by the formation in the sub-

epidermal layers of nodular patches of granulation-tissue (Fig. 154 *d*). Sometimes these nodules have the structure of the tubercles of tuberculosis, sometimes they consist entirely of small leucocytes with occasional capillaries (*d*). The eruption of the nodules is accompanied by diffuse cellular infiltration of the cutis and papillæ (*c*), and by the formation of strings of cells (*f*) running with the lymphatics. Redundant multiplication of the epidermal cells is often induced (*h*), and epidermal growths penetrate the deeper layers of the skin; when they reach a certain size they remind one of the cellular ingrowths of carcinoma. The surface layers may moreover be here and there swollen, or vacuolated, or in process of desquamation.

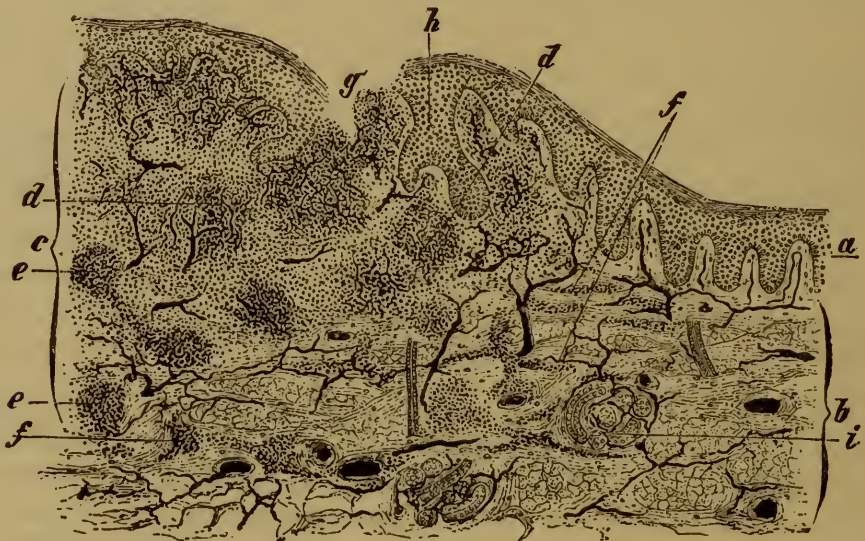

FIG. 154. PATCH OF LUPUS VULGARIS.

(Carminé staining: $\times 25$.)

- | | |
|---|-----------------------------------|
| <i>a</i> , normal epidermis. | <i>e</i> , non-vascular nodule. |
| <i>b</i> , normal cutis with sweat-gland (<i>i</i>). | <i>f</i> , strings of cells. |
| <i>c</i> , focus of lupus-tissue. | <i>g</i> , lupous ulcer. |
| <i>d</i> , vascular nodule surrounded by diffuse cellular infiltration. | <i>h</i> , proliferous epidermis. |
| | <i>i</i> , sweat-gland. • |

The hair-follicles and sebaceous glands are also affected, and the hair perishes in consequence. The glands cease to secrete sebum, and may become greatly distended and enlarged by the accumulation in their ducts of epithelial cells. Sometimes the cellular infiltration is most dense in the immediate neighborhood of the sebaceous glands.

The infiltrated tissue generally becomes necrotic, softens, and breaks through the epidermis (*g*); in this way lupous ulcers are formed which by gradual advance may involve a very large extent of the surface. In some cases however the nodules are re-absorbed without ulceration.

Some of the extravasated cells are utilized in forming new fibrous tissue, and the papillæ may in this way become notably enlarged, the skin as a whole may thicken, and at length the ulcerated tissue may be re-

placed by a cicatrix. After a time the new tissue contracts and a puckered scar is left.

Lupus first appears as a local eruption of small bright red or brownish spots (KAPOSI); after a time nodular prominences can be seen and felt under the skin, and the nodules coalesce so as to form larger nodes and tubercles (*lupus tumidus*). In a few weeks retrogressive changes set in: if the nodules are absorbed the epidermis becomes wrinkled and desquamates (*lupus exfoliatus*) leaving a scar-like patch behind; if they soften and break through the surface (*lupus exulcerans* or *exedens*) rounded ulcers are formed, with soft and reddened margins and red granulating floors, secreting pus and often becoming crusted over. The ulcers may heal by scarring and skinning, or warty growths may appear on the floor (*lupus verrucosus* or *papillaris*). If the nodules are at the outset irregularly scattered the affection is described as *lupus disseminatus*, if they are arranged in sinuous lines as *lupus serpiginosus*.

Lupus most commonly attacks the nose, but it very often occurs elsewhere on the face, in the neck, ears, mouth, nostrils, pharynx, larynx, and on the limbs, rarely on the trunk. The successive ulceration and cicatrization of the skin may in the course of years give rise to very remarkable deformity and disfigurement.

Leprosy has already been treated in Art. 131. The skin in this disease may be covered with flattened or nodular patches of cellular infiltration, which are red, brown, or white on the surface, and end either in desquamation or ulceration; the leprous patches and sores contain the specific *Bacillus lepræ* (Art. 206). According to VON RECKLINGHAUSEN the separate nodes and tuberosities develop chiefly around the cutaneous nerves. The ulcers formed by the disintegration of the nodes may become very deep and wide, and lead to the separation and loss of portions of the limbs (*lepra mutilans*). In *lepra maculosa* the skin is disfigured by diffuse pigmentations interspersed with streaks and patches of white.

References on leprosy:—Arts. 131, 206; BEHREND, *Schmidt's Jahrbücher* vol. 192 (a full summary of recent work); KAPOSI, *Hebra's Diseases of the skin* IV.; HILLIS, *Leprosy in British Guiana* London 1881; DUHRING, *Diseases of the skin* 1882; DAMSCH, *Virch. Arch.* vol. 92.

On lupus see HEBRA and KAPOSI, *Diseases of the skin* vol. IV.; VIRCHOW, *Die krankhaften Geschwülste*; AUSPITZ, *Wien. med. Jahrb.* 1864; LANG, *Vierteljahrs. f. Derm. u. Syph.* I., II.; KAPOSI, *ibid.* VI.; JARISCH, *ibid.* VII.; FRIEDLÄNDER, *Virch. Arch.* vol. 60; THOMA, *ibid.* vol. 65; THIN, *Med. chir. Trans.* LXII. (1879).

CHAPTER XXXIX.

INFLAMMATORY HYPERTROPHIES OF THE SKIN.

393. The inflammatory processes discussed in the last few Articles have this in common—that the formation of new tissue is inconsiderable, and in general little more than is necessary to make good the tissue which is lost. Even the granulomatous affections usually end in disintegration and ulceration, in the course of which the new granulation-tissue perishes. But we pointed out one or two exceptions to this rule, as for instance under eczema (Arts. 385, 392) and necrogenic pustule (Art. 390), in which chronic inflammation resulted in hyperplasia of the skin.

The **hyperplasia** may extend to the epidermal structures as well as to the fibrous elements. The excessive production of epidermal cells may be manifested simply by increased desquamation, or by thickening of one or more of the epidermal strata. Hyperplasia of the fibrous strata always involves an increase of their thickness over a more or less extensive area. When the papillæ are the structures most affected, they increase chiefly in length and often become subdivided as they grow, giving rise to unevennesses of the surface, which may be slight and wide-spread or aggregated into tumor-like masses.

The new tissue, while still recent, contains abundance of cells, and is in fact not far removed from granulation-tissue: in more advanced stages it contains fewer cells and is densely fibrous and scar-like. Both types may coexist in the same case.

394. When a part is continually exposed to slight mechanical irritation inducing often-repeated hyperæmia or slight inflammation, the epidermis may at length become hypertrophied. If the horny layer is chiefly involved, and callous or horny growths result, they are described as **callosities** (*tylomata*). They are commonest on the hands and feet.

When the callous thickening extends inwards and presses on the papillæ so as to lead to their atrophy, we have what is called a **corn** (*clavus*). The constant irritation of the papillary layer thus caused, especially when associated with external friction or pressure, induces more or less intense inflammation, and this occasionally passes into suppuration.

Sometimes the hypertrophy takes the form not of flattened or discoid thickening but of a horn-like protuberance (*cornu cutaneum*), which

may reach to a considerable size. The base usually includes a few enlarged and vascular papillæ.

Inflammatory warts are essentially of the same nature as the hypertrophies just described, though their appearance is very different. They are the result of long-continued irritation of a special kind. One of the commonest forms is that known as the **venereal wart** or cauliflower excrescence (*condyloma acuminatum*). This is usually seated on some part of the external genitals or around the anus; the special irritation which induces it is that caused by urethral discharges, chancreous pus, decomposed preputial or vaginal secretions, etc. The papillæ and the upper strata of the rete Malpighii become hypertrophied; the former (Fig. 155 *a*) become elongated and branched, and their blood-vessels are enlarged. The fibrous tissue on which they stand often becomes tumid at the same time, while the epidermal layers become thickened and hypertrophied, and so may cover over some of the irregularities caused

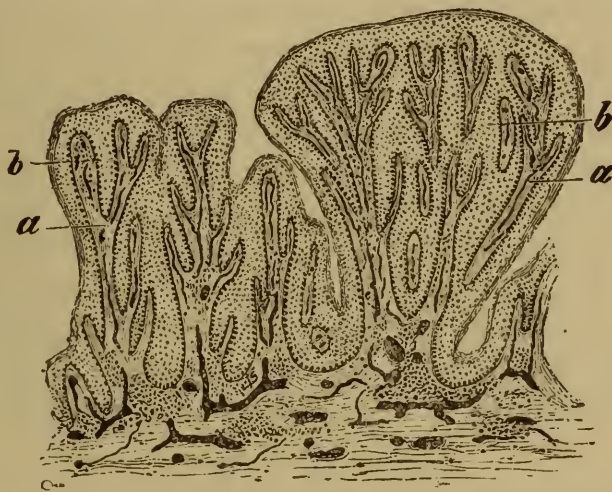


FIG. 155. VENEREAL WART.

(Injected preparation, stained with hæmatoxylin: $\times 20$.)

a, enlarged and branched papilla.

b, thickened epidermis.

by the branching of the papillæ. But many of these remain and are markedly exaggerated, so that the entire growth takes on a typically papillomatous appearance.

These warts are often very numerous and crowded together at one spot. Though small and inconspicuous at first they may grow to a remarkable size, and look like heads of cauliflowers. The papillæ as they grow tend more and more to subdivide; they are composed essentially of vascular fibrous tissue, but they always contain a number of leucocytes, and the base on which they stand is always more or less infiltrated. The lymphatics in the neighborhood may be extensively inflamed, as appears by the accumulation of cells within and around them.

Inflammatory papillomata may in like manner grow from the floor of an ulcer, especially such as occurs in connection with chronic impetiginous eczema (Art. 385). They may cover a wide area and give rise to diffuse

warty thickening of the skin (Art. 395). They usually possess an abundant cellular stroma, and might almost be described as consisting of granulation-tissue. The epidermal strata are occasionally absent, but they may be present and notably hypertrophied. Scales and crusts of epidermal cells are frequently formed.

395. **Acquired elephantiasis** (*elephantiasis arabum, pachydermia*) is a chronic and extensive hyperplasia of the skin and subcutaneous tissue. The various affections which have been described as elephantiasis (*arabum*) are certainly not all of the same nature; but if we except what is sometimes called elephantiasis mollis or fibroma molluscum (Art. 399), an affection depending on some congenital condition, they are all associated with some cause which gives rise to long-continued or often-repeated inflammation of the integument.

We said in Art. 394 that eczema was sometimes to be regarded as an inflammatory process leading to hypertrophy of the papillæ. This hypertrophy may extend to the cutis and subcutaneous tissues and lead to notable thickening of the entire skin, especially in the legs. Other chronic inflammations may like eczema lead to a pachydermatous condition of the skin: such are, for instance, chronic varicose ulcers, and chronic inflammation of bones lying immediately underneath the skin. Many of the forms of elephantiasis, and especially those to which the name is more properly restricted, take their rise in frequently-recurring erysipelalous inflammation. Tropical elephantiasis is now generally recognized to be ultimately due to the presence of the *Filaria sanguinis hominis* (Art. 235), a parasite which infests the lymphatics of the scrotum and lower limbs, and gives rise to inflammation and obstruction of the lymph-current.

Acquired elephantiasis may affect very various parts of the body, but is chiefly met with in the genitals and lower limbs. The enormous thickening and overgrowth of the integuments lead to great deformity, which is especially noticeable in the case of the lower limbs. As the leg becomes more and more thickened the distinction between foot and leg is gradually lost, and the limb at length looks like an elephant's. The scrotum may grow till it forms an enormous tumor reaching to the knees or lower, and may weigh upwards of a hundred pounds.

396. The affected parts of the skin in elephantiasis may be dense, hard, rough, and white (*elephantiasis dura*), or soft and grayish (*elephantiasis mollis*). When the tissue is cut into, a more or less abundant escape of lymph takes place: where the lymphatics are much dilated (*elephantiasis lymphangiectatica*) the lymph may flow away in considerable quantity.

The blood-vessels may be dilated and hypertrophied, or altogether unaltered. The subcutaneous and even the deeper-lying connective tissue may be involved in the general hypertrophy. The surface is either smooth (*elephantiasis glabra*), the horny layer being unaffected, or rough and warty (*elephantiasis verrucosa*), or tuberculated (*elephantiasis tube-*

rosa), or covered with papillomatous excrescences (*elephantiasis papillomatosa*). The horny layer is frequently thickened and altered, forming a covering of coherent scales or plates: the condition is sometimes described as acquired ichthyosis (Art. 397) or keratosis.

The structure of these elephantoid thickenings varies greatly. When they follow upon eczematous or ulcerative affections they are usually cellular and akin to granulation-tissue: sometimes they contain nodular aggregations of cells exactly resembling tubercles, and the lymphatics and the tissue around them are crammed full of lymphoid cells. On the other hand the tissue is in many cases poor in cells and coarsely fibrous in texture, giving one the impression that the normal fibrillæ are not so much increased in number as in individual thickness. Between these extremes there are numerous transitional forms, varying in the proportion of cells they contain and in the coarseness and abundance of the fibre.

The hyperplasia is in general uniform, but cases occur in which the thickened tissue is beset with irregular nodules, or in which the new tissue is more abundant round the sweat-glands and hair follicles. The papillæ are more or less enlarged.

The hyperplasia is probably to be regarded as resulting from an over-nutrition of the parts, which again depends on some inflammatory alteration of the vessels. Cell-multiplication is further favored by the partial occlusion of the lymphatics. This obstruction is well marked within the lymphatic glands, which are often hyperplastic in consequence of chronic inflammation. The production of lymph being increased and its outflow impeded, the tissues become saturated and the lymphatic vessels notably enlarged.

Scleroderma is a rare and very peculiar affection of unknown origin, which attacks adults. It takes the form of local or general stiffening and hardening of the skin without any apparent external cause: it is somewhat rapid in its onset, and then remains stationary or passes away, to be succeeded by a fresh attack or by a condition of cutaneous atrophy. It affects the face, limbs, and trunk; the patient often being literally 'hide-bound.' The skin feels as hard as a board, or like that of a frozen corpse (KAPOST). It is said that the fibrous tissues of the skin are hyperplastic and here and there infiltrated with small cells (CHIARI, *Viertelj. f. Derm. u. Syph.* v.; for cases see DUHRING, *Diseases of the skin* 1882). In one case of the disease Heller (*Arch. f. klin. Med.* x.) found that the thoracic duct was obliterated.

Sclerema neonatorum is a hardening of the subcutaneous connective tissue met with in infants, and chiefly affecting the legs and feet. According to LANGER (*Wiener Sitzungsber.* 1881), it is due to the solidification of the *panniculus adiposus* by cold when the infant becomes collapsed. The fat of children contain more palmitin and stearin and less olein than that of adults: it solidifies at 45° C. Adult fat at ordinary temperatures separates into two layers: the upper or liquid layer solidifies at 0° C., the lower or semi-solid layer liquefies at 36° C.

CHAPTER XL.

NON-INFLAMMATORY HYPERTROPHIES AND TUMORS.

397. **Ichthyosis** is a general affection or deformity of the skin, characterized by the formation of epidermal scales and plates, and of warty growths. It consists in an excessive proliferation of the cutis and epidermis; and is hereditary and congenital, though it does not usually manifest itself till the first or second year of life. LÉLOIR has in two cases found the cutaneous nerves in a degenerate condition, and regards the disease as of nervous origin.

The horny layer is enormously thickened, laminated, and fissured (Fig. 156 *a*); the rete Malpighii on the other hand is slightly developed in comparison, and passes without transition into the horny layer. In *ichthyosis simplex* the papillæ are not enlarged. In very slight cases the skin is simply beset with small nodules (KAPOSI) covered with a thin scale and containing a coiled-up hair (*lichen pilaris*). This condition is met with chiefly on the exterior surfaces of the limbs. In more marked cases contiguous scales or plates of various sizes up to that of a sixpence are formed, giving the surface the look of crocodile-skin (*ichthyosis nitida*). These may subsequently become rough and dirty or discolored (*ichthyosis nigricans*). When the papillæ are hypertrophied as well as the epidermis, the surface becomes extraordinarily rough and irregular; sometimes the elevations stand up like quills upon a hedgehog (*ichthyosis hystrix*, Fig. 156).

EULENBURG, AMOZAN, and GEBER state that ichthyosis may occur as an acquired affection in the adult, in consequence of neuritis or injury to cutaneous nerves.

The peculiar affection which has been called **neuropathic papilloma** of the skin by GERHARDT, and neuropathic nævus by SIMON, seems to be closely akin to if not identical with ichthyosis. It consists of papillary elevations of the skin covered with fissured and loosened epidermis: the elevations may be pigmented. It is accompanied by certain neurotic symptoms; it often corresponds in distribution with the course of particular cutaneous nerves, and when unilateral ceases at the middle line of the body. For these reasons it has been regarded as of nervous origin (BEIGEL, GERHARDT, HARDY, VON RECKLINGHAUSEN). So far as we know it is congenital, or developed only in the first years of life.

True ichthyosis must be distinguished from the pseudo-ichthyotic condition which is a common result of cutaneous inflammation, and from the affection known as *ichthyosis sebacea* (Art. 403).

References on ichthyosis:—HEBRA, *Diseases of the skin* III.; NEUMANN, *Lehrb. d. Hautkr.*; ESOFF, *Virch. Arch.* vol. 69; LEOIR, *Arch. d. physiol.* 1881; KYBER, *Wiener med. Jahrb.* 1880 (the case of an infant is described who was born with universal rigid mail-like thickening of the horny layer, an instance of so-called diffuse keratoma).

References on neuropathic papilloma:—BEIGEL, *Virch. Arch.* vol. 47; GERHARDT, *Jahrb. f. Kinderheilk.* 1871; VON RECKLINGHAUSEN, *Die multiplen Fibrome d. Haut* Berlin 1882 (the papillomata are thought to be due to congenital neuritis, the proximate cause being disturbance of the vaso-motor mechanism).

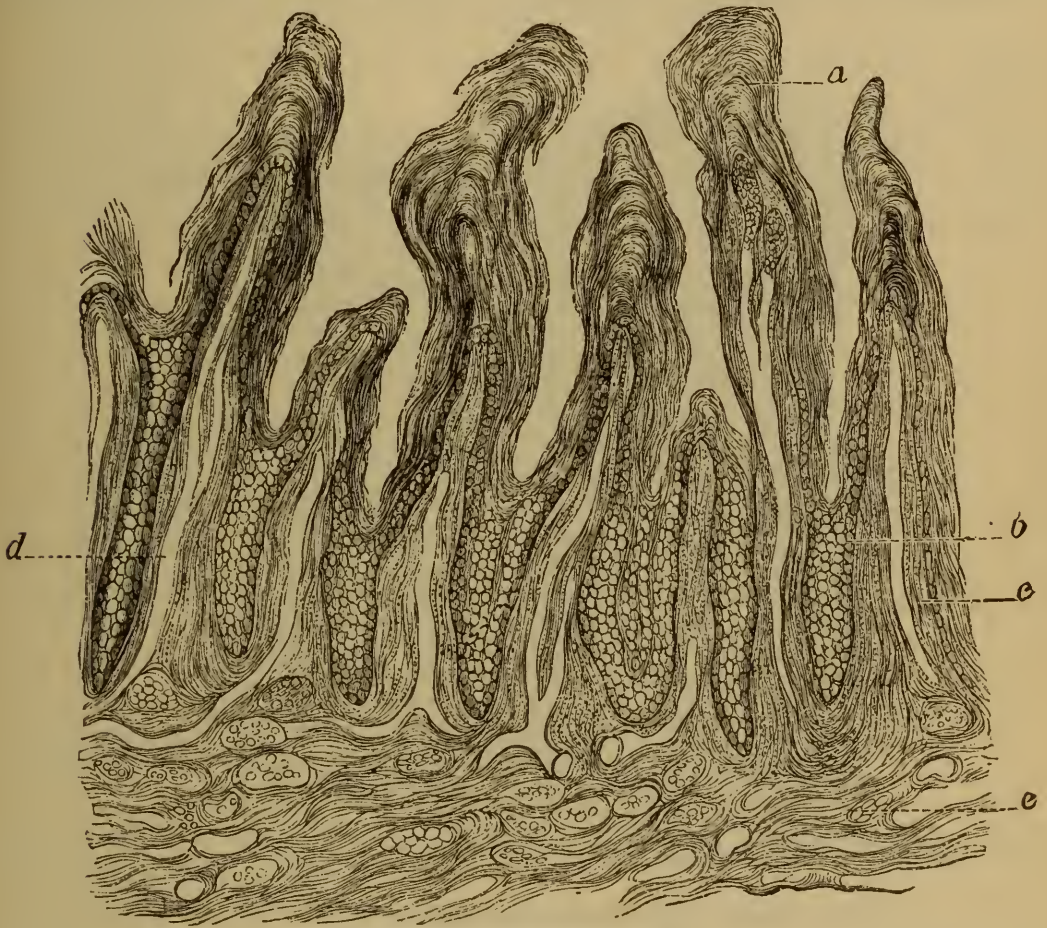

FIG. 156. ICHTHYOSIS HYSTRIX.

(After KAPOSI : low magnification.)

- a, horny layer. b, rete Malpighii.
 c, enlarged papillæ, infiltrated with cells and containing dilated blood-vessels d.
 e, corium with coarse fibrous bundles and numerous vessels.

BOSTRÖM some time ago (*Situngsber. d. phys.-med. Gesell. zu Erlangen* 1880) described a case in which every three or four months the horny epidermis of the hand was shed in the form of a glove. This was preceded by intense redness of the skin, and coincided in time with a menstrual period. The affection was therefore not improbably due to vaso-motor disturbance.

398. **Warts and moles.** The skin is the seat of certain peculiar formations, which are characterized by the presence of nests and clusters of

epithelioid cells. They affect the cutis chiefly, and appear at birth or in the first ten or twenty years of life.

The nests and clusters (Fig 157 *d*) consist of epithelioid cells with large oval vesicular nuclei. They lie in the lower reticular layers of the cutis or in the papillæ, and are separated by vascular connective tissue: but there are neither vessels nor fibrous tissue in the cell-clusters themselves. When the clusters are few in number they give rise to no visible change on the surface of the skin, but when they are more abundant they cause the surface layers to project into small flattened or tuberosous prominences.

The groups of cells are in general distinct from each other, and occa-

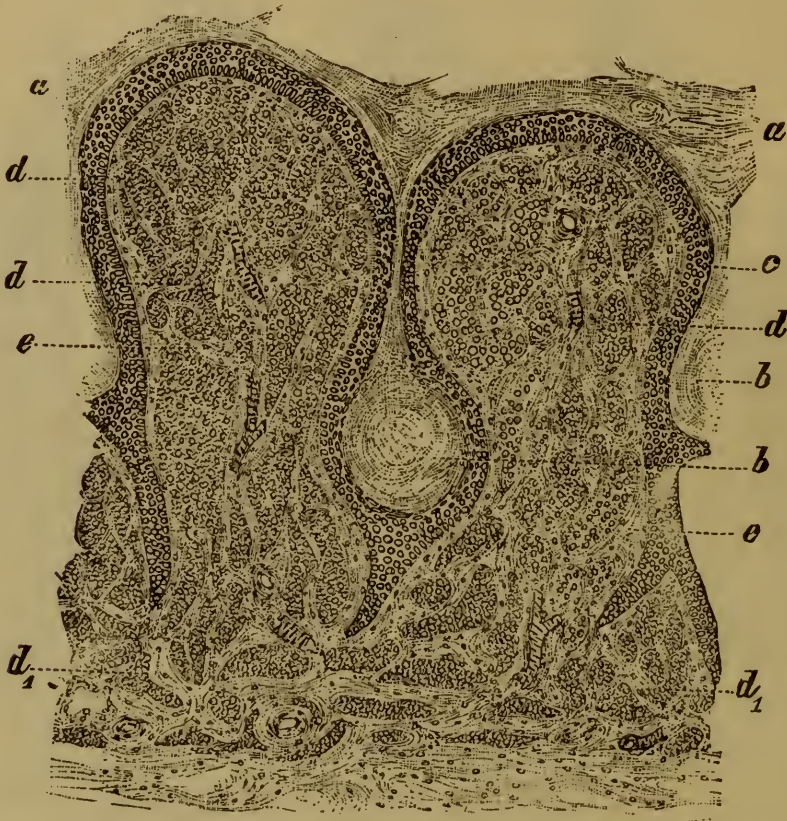

FIG. 157. SECTION THROUGH TWO PAPILLÆ FROM A CUTANEOUS WART.

(Carminé staining: $\times 50$.)

- | | |
|--|--|
| <p><i>a</i>, thickened horny layer of the epidermis.
 <i>b</i>, 'pearl' of epidermal cells.
 <i>c</i>, rete Malpighii.</p> | <p><i>d</i>, cell-nests and clusters in the papillæ, and
 <i>d</i>₁, in the reticular tissue of the cutis.
 <i>e</i>, vascular connective tissue.</p> |
|--|--|

sionally exhibit a certain regularity of arrangement into columns disposed at right angles to the surface of the skin. When they are very abundant and the intervening fibrous tissue scanty, the regularity is lost and the affected part seems made up of cells scattered uniformly through the tissue and separated partly by blood-vessels.

The overlying epidermis and the interposed fibrous tissue frequently contain yellow or brown pigment, but the cells themselves rarely contain

any. Such pigmented spots form the basis of freckles, sun-spots, mother's marks, warts, moles, and pigmentary nævi.

Freckles (*ephelides*) are small irregular brownish spots seen, usually on the face, in young people, and generally disappearing with advancing years. They sometimes however persist throughout life. Mother's marks (*lentigines*) are larger and more definite in size and dark-brown in color; they are either congenital or appear in infancy, and then remain unchanged throughout life. Moles and pigmentary nævi are congenital patches of various sizes, either level with the skin or slightly raised, and varying from yellow to brownish-black in color. They are often beset with hairs which are stronger and stouter than those in the neighboring skin; they are then called hairy moles (*nævi pilosi*).

Warts (*verruçæ*) vary in diameter from 1 to 20 millimetres. When the characteristic clusters of cells lie chiefly in the cutis and only to a small extent in the papillæ, the surface of the wart is smooth. When the papillæ are more extensively invaded (Fig. 158 *e*) the surface becomes somewhat rough and tuberos. When they constitute the chief seat of

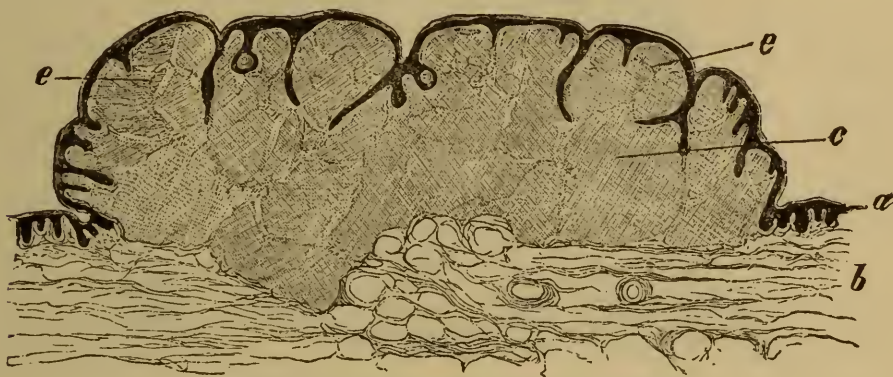


FIG. 158. SECTION THROUGH A SOFT WART.

(Aniline-brown staining: $\times 10$.)

a, epidermis
b, cutis.

c, cellular growth in the cutis,
e, cellular growth in the papillæ.

the cellular growth, they become enlarged and elongated, and the wart becomes papillomatous.

The epidermis covering a smooth wart is not usually thickened, and the wart is therefore soft (*verruca mollis* or *carnea*). In the case of rough warts the epidermis is generally hypertrophied (Fig. 157 *a*), and between the elongated papillæ are formed dense concentric clusters or 'pearls' of horny cells (Fig. 157 *b*); the wart is therefore hard (*verruca dura*).

The significance of these cutaneous growths in relation to the ætiology of tumors has already been discussed (Art. 179). Inasmuch as they are usually congenital or appear in the first few years of life, it is not unnatural to regard them as untransformed remnants of embryonal tissue, which on occasion proceed to grow and to develop after birth. DEMIÉVILLE has recently (*Virch. Arch.* vol. 81) investigated the nature of pigmentary moles and nævi, and thinks the cellular

nests and clusters are derived from the adventitia of the blood-vessels. VON RECKLINGHAUSEN (*Die multiplen Fibrome der Haut* Berlin 1882), who deals mainly with soft warts, thinks the cell-groups are developed in the lymphatics and lymph-spaces, and regards the growth as a lymphangio-fibroma. The name cannot be regarded as very apt, for the term fibroma is inapplicable to a structure almost wholly made up of cells. VON RECKLINGHAUSEN makes out that the cells first appear in the papillary layer of the cutis, and penetrate from this into the substance of the papillæ themselves; but this is true only in certain cases. In papillomatous warts and in the smaller pigmented moles the characteristic cells often lie altogether or nearly so in the papillæ. When the cell-groups are few in number they are seen to lie around the vessels, but when they are more numerous no such relation can be made out.

399. **Fibromata** of the skin are of two kinds, the hard and the soft. The soft variety is the more common, and is referred to as **fibroma molluscum**.

The tumors so called vary in size from that of a millet-seed to that of a man's head. The smallest of them lie embedded and hidden in the

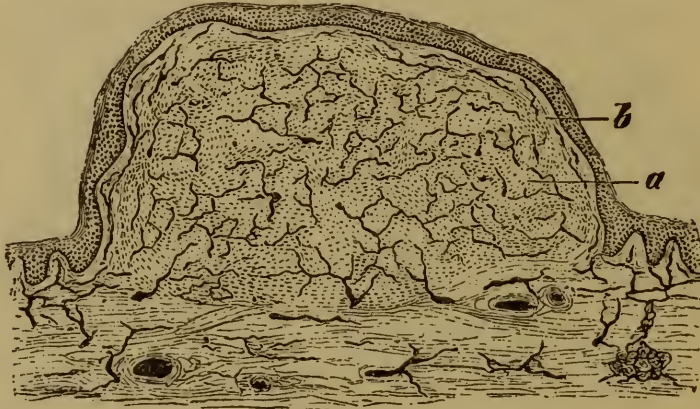


FIG. 159. FIBROMA (NEUROFIBROMA) MOLLUSCUM.

(Injected preparation, stained with hæmatoxylin: $\times 25$.)

a, vascular fibrous tissue.

b, papilla thinned and flattened out by distention.

skin, but the larger ones (often spoken of as 'wens,' Art. 404) are generally protuberant and often stalked (*fibroma pendulum*). They are always soft and flaccid, and the surface is usually wrinkled. As a rule they are multiple and sometimes appear in enormous numbers, so that the skin is thickly beset with smooth or wrinkled or pendulous growths of all sizes. The skin of the trunk is the favorite seat. There are usually a few large tuberous growths among the multitude of smaller ones.

The tumors consist of grayish semi-translucent moist-looking tissue, composed of thin flattened spindle-cells and delicate fibrillæ.

Some forms are firmer than others; the less firm varieties are rich in small cells and the fibrillation of the intercellular tissue is indistinct; the firmer varieties have fewer cells and are markedly fibrous, but in no case is the tissue so coarsely fibrous as that of the normal cutis. The growths are developed in the reticular layer of the cutis (Fig. 159), and

when they project above the surface of the skin the papillæ are thinned and flattened out. The new-formed tissue may invade the papillæ directly, or may advance into the subcutaneous tissues.

VON RECKLINGHAUSEN by his careful and exhaustive researches has established the fact that the multiple fibromata of the skin are in reality neurofibromata or neuromatous fibromata (Art. 154). They are developed from the fibrous sheaths of the smaller cutaneous nerves, and thence invade the fibrous structures of the vessels, the sweat-glands and their ducts, and the hair-follicles. The softer varieties still contain nerve-fibres, which run axially through the tumors, or subdivide and lose themselves in their substance. In the firmer tumors the nerve-fibres cannot be traced. The fibrous change (hyperplasia) extends some little way up the nerve-fibre from the point where it enters the tumor.

When a fibroma is carefully dissected it is seen to be made up of strands of dense fibrous tissue lying parallel to each other and united by loose cross-fibres. The structure of the whole growth is in fact plexiform, and so resembles that of the small neurofibromata which are found seated directly on the nerves.

Multiple cutaneous neurofibroma is either congenital or begins to appear in infancy: it is never truly an acquired affection. Many cases have been shown to be hereditary. Where a predisposition is known to exist, frequently recurring irritation sometimes leads to the development of the affection. Very frequently it is accompanied by the growth of fibromatous tumors on the deeper nerve-trunks, which accords with the view of its nature already expressed.

As the tumors grow they invade the fibrous sheaths of the various tubular structures seated in the skin, and occasionally reach an enormous size. In this case they give rise to the appearance of elephantiasis, the affection having on this ground being described as pachydermatocele (VALENTINE MOTT), elephantoid molluscum (NELATON), and elephantiasis mollis (VIRCHOW); to distinguish it from acquired elephantiasis (Art. 395) we may perhaps designate it congenital elephantiasis. The affection does not always take the form of circumscribed tumors, but sometimes gives rise to extensive and general thickening and overgrowth of the skin (dermatolysis), which lies in loose overlapping bulges and folds like that of a hippopotamus or elephant.

Fibromata of various sizes are met with which are not neuromatous. They form hard or soft nodes seated in the skin or subcutaneous tissues.

Keloid is a very rare variety of fibroma. It takes the form of tuberculous or discoid or band-like growths seated in the corium beneath the papillary layer. The papillæ and epidermis are intact. When fully developed the growth consists almost exclusively of bundles of coarse fibres. In its earlier stages it contains numerous spindle-cells.

Cicatricial keloid must be distinguished from true or spontaneous keloid. It grows in the substance of a scar, and is therefore not covered

with papillæ. In other respects it may resemble the true keloid. The disease called 'Addison's keloid,' and now known as morphœa, is in no way related to these affections: it is a hypertrophic condition, somewhat resembling scleroderma (Art. 396).

The genesis and significance of the multiple cutaneous fibromata have been worked out by VON RECKLINGHAUSEN (*Die multiplen Fibrome der Haut und ihre Beziehung zu den multiplen Neuromen* Berlin 1882). He investigated with the utmost care their relations to the various constituents of the skin and their developments from the fibrous sheaths of the nerves, and thus made clear many facts that were before unexplained. He also examined their connection with the fibromata (false neuromata) of the nerve-trunks, and with several allied affections of the skin such as elephantiasis mollis. BRUNS (*Virch. Arch.* vol. 50) and CZERNY (*Langenbeck's Arch.* XVII.) had already pointed out the close connection of the latter affection with multiple neurofibroma. VON RECKLINGHAUSEN gives in his tract a summary of the hitherto published cases and memoirs. He regards the elephantoid hypertrophic folds of the skin, referred to in the text as dermatolysis, not as due to the extension of a neurofibromatous growth, but as a primary neuropathic affection similar to neuropathic papilloma.

LABBÉ and LEGROS (*Journ. de l'anat. et de la physiologie* 1881) describe a circumscribed hypertrophy of the papillæ associated with hyperplasia of the touch-corpuscles. They call it papillary neuroma.

On keloid see LANGHANS (*Virch. Arch.* vol. 40); BABESI (*Viertelj. f. Derm. u. Syph.* VII.); WARREN (*Sitzungsber d. Wiener Akad.* 1868); FAGGE (*Guy's Hosp. Rep.* 1868); KAPOSÍ (*Hebra's Diseases of the skin* III., with further references); DUHRING (*Diseases of the skin* 1882).

400. In addition to the inflammatory and tumor-like cutaneous growths there are others (mostly in the form of warty thickenings of the skin) in which all the constituent elements of the skin take part without any notable change of structure. They are most frequently met with in the face and form gland-like often hairy prominences. On the nose they appear as large irregularly lobulated swellings known as **rhinophymata** (HEBRA). They consist essentially of a thickening of the fibrous tissue of the skin with hyperplasia and cystic dilatation of the sebaceous glands: occasionally adipose tissue is developed in the thickened cutis. The result is the elevation of the papillary layer with the overlying epidermis (thickened or not) into circumscribed projections.

Molluscum contagiosum (*epithelioma molluscum, molluscum epitheliale*, sebaceous wart, endocystic condyloma) is the term commonly used to designate a peculiar tumor-like growth in the skin, the variety of other names proposed indicating that authors are not yet agreed on the exact pathological significance of the affection.

Some English and French authors, with HEBRA and KAPOSÍ, regard *molluscum contagiosum* as due to a distention of the sebaceous glands with accumulated cells, in which some of the cells undergo a peculiar metamorphosis. Others like VIRCHOW, BIZZOZERO, MANFREDI, PERLS, and THIN, consider it to be a purely epidermal growth not starting in the sebaceous glands. According to them it is a simple hyperplastic

growth of epidermal cells, starting in the hair-follicles (VIRCHOW) or in the interpapillary portion of the rete Malpighii (BIZZOZERO, MANFREDI). Nodes as large as a pea or larger are thus formed, and may be grouped in clusters. On section their structure appears to be racemose or gland-like, the nodes being made up of nests of epidermal cells separated by fibrous septa. The cells on the outside of the clusters are columnar. In the centre of the nests lie peculiar bodies like swollen starch-grains, either free or enclosed in cells. These bodies are characteristic of the affection, and are by some regarded as degenerate epithelial or epidermal cells, by others (KLEBS, BOLLINGER) as parasitic organisms. As the affection occasionally appears simultaneously in persons who live together it is often regarded as contagious (VIRCHOW); but this is denied by other observers, and apparently with good reason.

The name *molluscum contagiosum* is due to BATEMAN (*Delineations of cutaneous diseases* (Plate LXI.) London 1817). VIRCHOW regards the contagiousness of the disease as established *Virch. Arch.* vol. 33, and names it *epithelioma*. O. SIMON (*Deutsch. med. Woch.* 1876), C. BÖCK (*Viertelj. f. Derm. u. Syph.* II.), BIZZOZERO and MANFREDI (*Arch. p. l. scienze med.* I.) hold that the disease originates in a redundant multiplication of the cells of the rete Malpighii. The latter authors also describe how the characteristic 'molluscum bodies' are derived from epidermal cells. According to THIN (*Journ. of Anat. and Physiol.* 1881) groups of small granules make their appearance in the cells of the hair-follicles, and then in those of the surface layers of the skin; these granules are afterwards transformed into homogeneous masses. The epidermal cells begin then to grow downwards into the fibrous layers of the cutis, and in the growing cells similar homogeneous bodies appear.

For cases see FAGGE (*Guy's Hosp. Rep.* 1870), DYCE DUCKWORTH (*St. Barth. Hosp. Rep.* 1868, 1870), HUTCHINSON (*Clinical Surgery* vol. I. London 1878), MORISON, THIN, etc. (*Path. Soc. Trans.* 1881).

As against the contagious nature of the affection it may be mentioned that inoculation with the matter taken from the tumors does not tend to reproduce it.

401. Among the connective-tissue growths starting in the cutis angioma, lymphangioma, and sarcoma are somewhat common forms.

Angiomata appear as bright or dark red often slightly-raised patches in the skin. They have already been discussed in Arts. 148-151; and the lymphangiomata, which when extensive give rise to soft tuberous swellings without discoloration, have been referred to in Art. 152.

Sarcoma takes the form of nodular tumors, more or less raised above the surrounding surface; sometimes they are even pedunculated or mushroom-shaped. They are usually solitary, but now and then instances occur in which a number of sarcomatous growths appear in the skin simultaneously or in quick succession. Cutaneous sarcoma may be round-celled, spindle-celled, or mixed. The commonest form is the **round-celled**, of which both large-celled (Fig. 50, Art. 159) and small-celled varieties occur. Melanotic and alveolar sarcomata are also not uncommon. The latter (Fig. 54, Art. 161) start in cellular warts and pigment-spots, and correspond closely with these in their general struc-

ture. When they start in pigment-spots or pigmentary moles the substance of the tumor is pigmented. Like other round-celled sarcomata these are malignant. Spindle-celled forms may also start in warts or cutaneous fibromata. But all the forms may arise in portions of skin that previously appear altogether normal.

Lipomata of the skin and subcutaneous tissue are very frequently met with, and sometimes reach a great size. The region of the shoulder is a favorite seat.

Myxoma and enchondroma are less common than lipoma, and osteoma is rarer still. Myxoma and myxofibroma are generally connected with the external genitals in women.

Xanthelasma or xanthoma is a peculiar growth, taking the form of pale or brownish yellow circumscribed patches (*xanthelasma planum*) or nodules (*xanthelasma tuberosum*), which may be isolated or aggregated into groups. It occurs chiefly in the neighborhood of the eyelids and on the cheeks, and consists of a hyperplasia or new-formation of fibrous tissue, in which fat is subsequently deposited. Similar spots and nodules, often described as xanthoma, are produced on the eyelids by the enlargement of the meibomian glands and the deposit in the overlying skin of a pale yellow pigment. Occasionally the affection becomes multiple, or even universal (*xanthelasma multiplex*). In many cases of this kind jaundice has preceded the skin affection, and some authors have regarded the latter as connected with the circulation of bile-pigment in the blood. This is certainly not true of all cases.

402. **Epithelioma** (cutaneous cancer or cancroïd) is by far the most important of the epithelial neoplasms of the skin. Its mode of growth has already been described in Art. 170 (see Fig. 62). The epithelial proliferation may start not only in the epidermis, but in the epithelium of the sebaceous glands of the hair-follicles. Three varieties might thus be distinguished, but a more useful distinction is that based on the general characters and appearance of the growth, inasmuch as it is difficult or impossible to say in all cases whence it first started. THIERSCHE distinguishes a flat or superficial and a deep or infiltrating form. The former is met with chiefly in the lip, forehead, and nose; and is characterized by the fact that the epithelial ingrowths and processes are short and shallow. It generally appears as a slightly raised ulcer with hardened or infiltrated borders, due to the breaking-down of a primary cancerous node. Its growth is usually very slow, and it may cicatrize at the centre while the marginal ulceration continues to advance. In other cases the process of disintegration is more rapid, and the ulcer steadily increases in depth and extent. This form is clinically described as **rodent ulcer**, and chiefly affects the upper part of the face. The stroma of an ulcerating cancer is always more or less infiltrated with cells, and these may be so abundant in some places as to give it the look of granulation-

tissue. The superficial form seldom produces metastatic growths in the lymphatic glands or elsewhere.

The deep or infiltrating form gives rise to irregularly-shaped ulcerations, due as in the former case to the breaking-down of nodular epithelial growths. From the floor and edges of the ulcer often rise large protuberant warty structures, giving the affection the appearance of a papillomatous tumor. This form produces metastases oftener than the other.

Intermediate forms are not uncommon which it would be difficult to class definitely with one or other of the above; and other varieties having no resemblance to either of them also occur. In fact the processes of cancerous infiltration, proliferation of the fibrous tissue, disintegration, and ulceration, may be combined in numerous ways, and give rise to great diversity of appearance in the several stages of the disease.

Epithelioma most frequently attacks parts where epidermis passes into mucous membrane—such as the lower lip, nose, eyelids, prepuce, anus, external female genitals, etc. Occasionally it seems to start in warts or callosities or in scars.

Some English pathologists insist on the distinctions between ordinary epithelioma and what is clinically called rodent ulcer by English surgeons. One distinction drawn is that in the former the neoplastic cells are recognizably of an epidermal type, in rodent ulcer they are epithelial but not epidermal, having small nuclei and but little stability, as if derived from glandular cells: they have been supposed to be derived from the cells of the sweat-glands (THIN) or of the outer-root sheath of the hairs (FOX). See THIERSCH (*Der Epithelialkrebs* Leipzig 1865), MOORE (*Rodent Cancer* London 1867), WARREN (*Rodent Ulcer* Boston, 1872, *Med. Times and Gaz.* 1, 1880), HUTCHINSON (*Clinical Surgery* vol. I. London, 1875), THIN, FOX, BUTLIN, and others (*Path. Soc. Trans.* 1878-79, in which references to earlier literature will be found), KAPOSÍ (*Hebra's Diseases of the skin* IV., *Path. u. Therap. d. Hautkrankheiten* Vienna 1880).

Adenoma of the sweat-glands is a somewhat rare affection. It gives rise to nodules, which break down and ulcerate (VERNEUIL, *Arch. générales* 1854; THIERSCH, *Der Epithelialkrebs* 1865).

Secondary neoplasms of the skin are not very common, though they do occur in connection with both connective-tissue and epithelial tumors. Malignant growths of the skin itself are especially apt to infect healthy parts of it, and give rise to daughter-tumors. Of growths in other organs mammary cancer is the most apt to produce cutaneous metastases.

CHAPTER XLI.

AFFECTIONS OF THE SEBACEOUS GLANDS, HAIR, AND NAILS.

403. **Disorders of the sebaceous secretion.** In normal conditions the epithelium of the sebaceous glands secretes a small quantity of oily liquid, which becomes condensed in the gland or in its duct to a semi-fluid grease-like substance containing disintegrated cells. If the secretion becomes over-abundant we have what is called **seborrhœa** or **steatorrhœa**, with its consequences which go by the various names of *tinea furfuracea*, *acne sebacea*, *ichthyosis sebacea*, etc. According as the secretion dries into scales and crusts or remains liquid and oily we have *seborrhœa sicca*, *squamosa*, *furfuracea*, or *seborrhœa oleosa*.

The scales and crusts are often dirty and discolored, and occasionally form broad greasy scabs or lamellæ, from the under side of which processes pass into the openings of the sebaceous ducts.

Seborrhœa may be local or general. The local variety chiefly affects the scalp and the external genitals. General seborrhœa is rare, and is usually met with only in new-born infants; the abundant secretion of *vernix caseosa* which is normal in the intra-uterine period is in fact continued after birth. The abundant sebaceous secretion from the glands of the scalp which is normal during the first year of life sometimes gives rise, in neglected infants, to large fissured dirty cheesy-looking crusts or cakes, consisting of fatty matter, dirt, epidermal scales, and hairs.

Seborrhœa often affects enfeebled or anæmic patients. The skin of the trunk and limbs becomes covered with dry glistening scales, whence the affection is sometimes referred to as *pityriasis tabescentium*. When the scalp only is affected, the dried secretion taking the form of abundant branny scales, the affection is called **dandriff** or *pityriasis furfuracea capillitii*; when the scales are large and thick it is sometimes called *ichthyosis sebacea*.

Asteatosis, in which the sebaceous secretion is diminished, is rare as an idiopathic affection. It is usually secondary to other affections like ichthyosis, prurigo, psoriasis, pityriasis rubra, leprosy, etc. The skin becomes dry and fissured, and is shed in scales or flakes.

404. Various disorders of the skin are due to the accumulation of sebum in the glands or ducts in consequence of some obstruction of the outlet. The obstruction is usually due to the drying of sebum or the deposit of dirt at the mouth of the duct.

Comedones are small elevations of the skin due to plugging of the sebaceous ducts, or of the common opening of duct and hair-follicle. When the plug is squeezed out it appears as a whitish and somewhat firm pear-shaped or cylindrical mass of the size of a pin-head, the superficial end being stained black or brown. It consists of sebum and horny epidermal cells, and often contains minute hairs, and the mite called *Demodex folliculorum* (Art. 225). According to UNNA (*Virch. Arch.* vol. 82), the staining of the 'head' of the comedo is due to the presence of pigment either free or contained in the horny epidermal cells. Comedones usually occur on the forehead, cheeks, and chin, and occasionally the chest.

Milium (*grutum* or *acne albidula*) consists of small roundish white or yellowish elevations of the skin, due to the accumulation of sebum and epidermal cells in sebaceous glands whose outlet has become obliterated. Occasionally the accumulation may distend the tubes of the associated hair-follicles into cysts of considerable size. The skin of the eyelids is a favorite seat. When the nodule is incised and the contents evacuated, they are often found to be concreted into a firm and sometimes even stony core.

Wens or sebaceous cysts (*atheroma* or *steatoma*) are due to the collection of more or less fluid secretion distending the lumen of the sebaceous gland, its duct, and the neighboring hair-follicle into a cyst, which may be as large as a walnut or even considerably larger. The contents of a wen may be soft and pulpy or firm and friable. They consist of fatty detritus, sebum, epidermal cells, and sometimes tablets of cholesterin and hairs, all enclosed in a capsule made up of layers of epithelial cells and fibrous tissue. They are usually seated on the scalp, more rarely on the back of the neck or on the face, trunk, and limbs.

Sometimes papillary outgrowths covered with epidermoid cells arise from the inner surface of the wall of a sebaceous cyst, and may increase in size so as to fill up the cavity. FÖRSTER (*Würzburger Verhandlungen* x.) has described this as dry cancrioid; it may in time become calcified. CHIARI (*Naturforscherversamm. in Salzburg* 1881) has met with a case in which the internal layers of cells became dry and horny, the fibrous capsule becoming at the same time contracted. Atheromatous cysts are sometimes formed at the site of persistent branchial clefts (Art. 8).

405. **Inflammatory affections of the sebaceous glands and hair-follicles.** **Acne** is the general name given to localized inflammations surrounding the hair-follicles and associated sebaceous glands (Fig. 160). It gives rise to small red nodules or pimples, in which may be noticed the dark head of a comedo, or a minute collection of pus.

The tissue around the hair-follicle and gland may be simply hyperæmic and infiltrated with cells (Fig. 160 *b*), or suppurating; and according to the intensity of the inflammation are distinguished the varieties *acne indurata*, *acne punctata*, and *acne pustulosa*. The extent of the

inflammation also varies greatly. Ultimately however the sebaceous gland, and often the hair-follicle also, are destroyed.

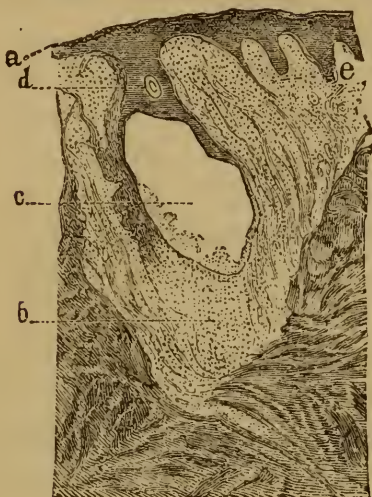


FIG. 160.

VERTICAL SECTION THROUGH AN ACNE-PUSTULE.

(After KAPOSI: slightly magnified.)

a, epidermis.

b, inflammatory infiltration of the corium surrounding the gland and hair-follicle and of the neighboring papillæ e.

c, sebaceous gland the contents of which have been mostly evacuated; the remainder consists of pus and fatty epithelial detritus.

d, the hair-follicle connected with the gland (in oblique section).

e, altered papillæ.

containing in the centre a 'core' or slough of necrosed tissue: as the tissue around suppurates the core is loosened, and ultimately cast off when the boil 'breaks.'

Carbuncle or *anthrax simplex* resembles a boil in many points, being a firm more or less circumscribed deep-seated inflammation of the skin; but it extends over a greater area, and gives rise to a firm livid swelling which may reach the size of the palm of the hand or more. The swollen and infiltrated skin usually necroses, and is transformed into a dark grayish pulp or a continuous slough. The subcutaneous tissue becomes necrotic and suppurates beneath the slough, the pus usually breaking through at several points. The slough is ultimately cast off, leaving an open granulating wound.

406. **Lichen** (according to HEBRA and KAPOSI) is an eruption of papules, which remain as such throughout, and do not pass into any other form of efflorescence.

Lichen scrofulosus is a chronic affection, in which pink or brownish flattened papules are formed, each capped with a small scale. It is met with chiefly in scrofulous patients, and usually affects the trunk.

The cause of the inflammation is probably to be found in some anomaly of the glandular secretion. It is easy to understand that if the secretion stagnates and becomes in some way contaminated, it may act as an irritant on the surrounding tissues.

Acne mentagra (*sycosis non-parasitaria* or *folliculitis barbæ*) is a suppurative peri-follicular inflammation. It gives rise to papules and pustules, which are usually perforated by hairs. The parts affected are the beard, and sometimes the scalp.

Parasitic sycosis resembles the non-parasitic affection; it is due to the invasion of a fungus (see under *tinea tonsurans*, Art. 411).

Boils or *furunculi* are due to inflammation of the tissue surrounding a hair-follicle or sebaceous gland, being distinguished from the pimples or pustules of acne by the much greater extent and intensity of the inflammation. A hard dark-red swelling is produced,

According to KAPOSI it is due to inflammatory infiltration and exudation in and around the hair-follicles and sebaceous glands, and in the neighboring papillæ. The scales are composed of epithelial cells which accumulate round the openings of the follicles.

Lichen ruber acuminatus is characterized by the appearance of scattered hard red nodules, each capped with a little knot of epidermal scales, and tending to coalesce into irregular desquamating patches. In the course of years the affection may extend over the entire surface of the body. The process starts in and around the hair-follicles (HEBRA, KAPOSI, NEUMANN), beginning with hyperplasia of the cells of the outer root-sheath; cellular outgrowths from the follicles penetrate the surrounding structures, and the papillæ and rete Malpighii become infiltrated with cells or themselves undergo proliferation. In *lichen ruber planus* the papules are flattened and umbilicated, they are red or dull pink, and the continuous patches into which they coalesce have a shining waxy look and do not desquamate.

407. **Affections of the hair and nails.** Each hair according to its size has a definite period of existence. When this is at an end, the hair is shed and its place is taken by a new one. The replacement is effected by the cells at the tip of the papilla ceasing to grow and multiply, in consequence of which the old hair with its inner root-sheath is separated from the papilla. The young hair is then produced by the renewed growth of the cells of the papilla left behind on the separation of the old hair. Long thick hairs live longer than short and fine ones.

To maintain the uniform growth of the hair as a whole a constant relation must be kept up between the loss of old hairs and the production of new. When this relation is disturbed by hindrances to production, the result is **alopecia** or baldness. KAPOSI distinguishes the following forms.

Alopecia adnata, or congenital absence of hair, is seldom an enduring condition.

Alopecia (calvities) acquisita is natural in old age (*alopecia senilis*), but it may appear at any period of life (*alopecia prematura*). In the baldness of age the skin exhibits the changes described in Art. 364; but it is to be noted that they do not appear till after the hair has disappeared; they cannot therefore be the cause of the baldness.

Alopecia prematura may be idiopathic or symptomatic. In the former case the hair falls off without visible disease of the skin. When the denudation takes the form of isolated patches the affection is described as *alopecia areata* (*area Celsi* or *porrigo decalvans*). In some instances it extends to every spot on which hair occurs. As to its cause, some authors regard it as a micro-parasitic affection (EICHHORST, *Virch. Arch.* vol. 78; LASSAR, *Deutsch. Med. Woch.* 1881; THIN, *Prog. Roy. Soc.* 1881, *Brit. Med. Journ.* 2, 1882, the associated fungus being named by him *Bacterium decalvans*), while others with much less reason speak of

it as a trophoneurosis. In senile alopecia obliteration of the capillaries supplying the hair papillæ has been noticed. In the premature form the follicles sometimes appear stunted and atrophied.

The causes of symptomatic alopecia are better understood. Any inflammatory process which seriously disorders the nutrition of the skin, such as eczema, erysipelas, acne, lupus, syphilitic eruptions, etc., may give rise to baldness. The continuous development of the hair from its bulb is interfered with, and the hair thus ceases to grow and is shed. If the papillæ are not destroyed the hair may afterwards be reproduced.

Alopecia due to chronic exudative affections of the skin, such as psoriasis, lichen ruber, or eczema, is described as *alopecia furfuracea* or *pityroides*. Seborrhœa is a common cause of baldness. The hairs are imperfectly formed, and they therefore fall off sooner than they should do, they are replaced only by thin downy hairs, and after a time no new hair is produced at all.

The **nails** are frequently misformed or defective, and abnormally thin or brittle, especially as a result of inflammations or of direct injury.

408. Overgrowth of hair (*hypertrichosis, hirsuties, polytrichia*) may be congenital or acquired. The whole body or isolated parts of it may be abnormally hairy. Congenital hairiness seems to be hereditary in some families. Cases are known in which not only the trunk and limbs, but also the greater part of the face and even the nose, have been covered with hair. Hair on the chin and upper lip in women is not uncommon. Moles and pigment spots are often abnormally beset with hair (Art. 398).

Overgrowth of the nails in length and thickness is frequently met with, and they are often at the same time distorted, rough, or tuberculated. Excessively long nails become curved into claws (*onychogryphosis*). When they become excessively broad they are apt to cut into the soft parts, giving rise to hæmorrhage and inflammation (*paronychia*). Vegetable parasites sometimes attack the nail and its bed, which they penetrate in all directions, causing it to increase in size and ultimately to soften and break down (*onychomycosis*, Art. 411).

On hairy men (*homines pilosi* or *hirsuti*) see WILSON (*Diseases of the skin* London 1867, *Lectures on Dermatology* London 1878) and ECKER (*Ueb. abnorme Behaarung des Menschen* Brunswick 1878).

CHAPTER XLII.

PARASITIC AFFECTIONS.

409. **Vegetable parasites.** The hyphomycetes or moulds (Arts. 213, 222), which infest the human skin form jointed mycelial filaments (hyphæ) and spores (conidia) (Fig. 161). Various names are given to the groups of filaments and spores according to the form of the affection or **dermatomycosis** which they produce. The filaments and spores are found chiefly in the epidermoid structures of the skin, and especially in the hairs and hair-follicles. The filaments penetrate between the cells, loosen them from each other, and ultimately separate them from their nutrient base; the disintegrated cells then serve for a soil to the growing fungus. Hyperæmia and inflammation are set up, and in consequence scales, vesicles, pustules, and scabs, are developed. The fungi have no perceptible effect on the system as a whole. They do not attack all skins, but only those which exhibit a certain predisposition, though it is hard to say wherein this lies.

The mycoses of the skin are divisible into three main forms, known as Favus, *Tinea tonsurans*, and Pityriasis vesicolor.

In addition to these familiar dermatomycoses there are others which are also ascribed to the invasion of fungi, such as alopecia areata, psoriasis, and contagious impetigo. They have been already described. The bacterial affections of the skin have likewise been treated of; they are variola (Art. 388), erysipelas (Art. 375), phlegmon and malignant pustule (Art. 390), leprosy (Art. 133 and 392).

410. **Favus** (*tinea favosa* or crusted ringworm) chiefly attacks the scalp, though it is also met with in other parts, such as the nails. It is characterized by the formation of pale-yellow cup-shaped friable crusts usually perforated by hairs, the so-called favus-cups (*scutula*). The crusts vary from the size of a pin-head to that of a sixpence.

According to KAPOSI the favus-cup begins as a minute yellow punctiform spot perforated by a hair and lying beneath the epidermis. In a few weeks it grows to the size of a pin-head, and then appears as a pale-yellow cup-shaped disc showing through the skin. On section the disc (Fig. 162) is seen to consist of mycelial filaments and spores lying beneath the horny layer of the epidermis (absent in the figure) in an excavation of the skin. If the cup is removed the surface of the excavation has a red and moist appearance. The cup itself is whitish and friable, and

may be teased out when placed in water. The fungus is called *Achorion Schönleini* (from SCHÖNLEIN who discovered it in 1839).

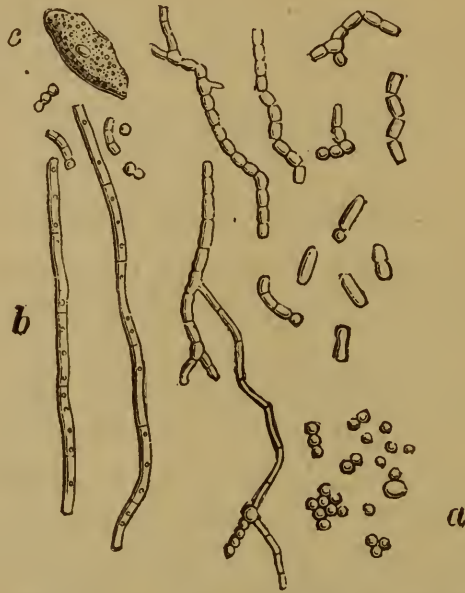

FIG. 161. FUNGI FROM A FRESH FAVUS-PATCH (NEUMANN).

a, separate conidia. b, mycelial filaments.
 c, epidermal cell beset with micrococci.



FIG. 162. CUP OR SCUTULUM OF FAVUS (NEUMANN).

a, free edge of the cup. f, epidermis.
 b, dead and disintegrated horny layer of the g, altered papilla.
 epidermis. h, cellular infiltration beneath the cup.
 c, d, mycelial filaments. i, cutis.
 e, conidia.

If the favus-cups are not removed they coalesce to form large con-

tinuous masses. When the horny skin which binds them down is cast off or broken through, these masses are exposed and dry up into yellowish mortar-like crusts. The hairs look dull and powdery and are easily pulled out. This is due to the fact that the hyphæ and conidia enter the opening of the hair-follicle and grow into the bulb and shaft of the hair (Fig. 163 *a*), and also into the root-sheaths.

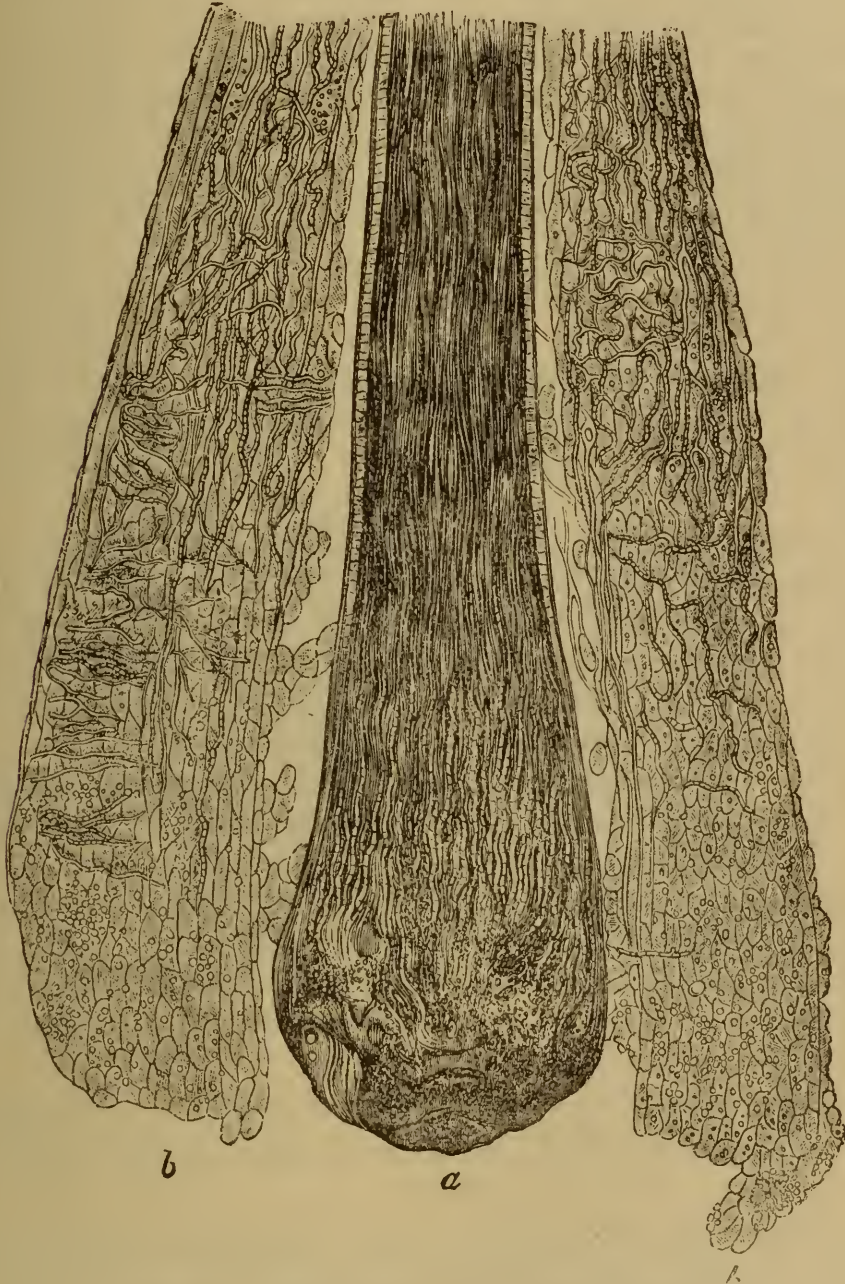

FIG. 163. HAIR AFFECTED WITH FAVUS (after KAPOSÍ).

a, hair-bulb and shaft.

b, root-sheath beset with hyphæ and conidiæ.

The hair may be actually extruded by the growing fungus, and the papillæ may become atrophied by pressure. At the same time the surrounding tissue is affected with more or less intense inflammation, which

may take on an eczematous character. When the fungus settles in the nail (*onychomycosis favosa*), yellowish deposits or thickenings are formed, and the substance of the nail becomes loosened and softened.

411. **Tinea tonsurans** (*herpes tonsurans* or common ringworm) is an affection produced by the filaments and spores of *Trichophyton tonsurans* (discovered by GRUBY in 1844). It assumes a different appearance according as it occurs on hairy or non-hairy parts.

Tinea tonsurans capillitii, or ringworm of the scalp, gives rise to bare circular patches from the size of a sixpence to that of a crown-piece, or to an irregularly scattered eruption, the hairs over the affected spots being broken off short and frayed at the ends. The surface of the patches is smoothed or scaly, and their margins are reddened. Vesicles and scabs are occasionally produced. The patches may be few or many, and grow steadily in size until the affection is cured.

On non-hairy parts rings of vesicles (*tinea (herpes) tonsurans vesiculosus*) and red scaly circular patches (*tinea tonsurans squamosus*) are produced, the affection being then generally described as *tinea circinata* or ringworm of the body. Sometimes a number of red spots appear in rapid succession at various points, and heal as rapidly without attaining any great size.

Trichophyton tonsurans forms long slender and but little branched mycelial filaments; it produces spores within the body, but the mycelium is not aggregated into scutula like that of *Achorion*. It readily penetrates the hair-shaft, making it brittle or rotten. In scaly ringworm of the body the fungus penetrates the upper layers of epidermal cells immediately underneath the horny layer (KAPOSI).

When the fungus attacks the nails (*onychomycosis tonsurans*), they become opaque and split into laminae, becoming at the same time very brittle.

Sycosis parasitaria (tinea sycosis or barber's itch) is due to an inflammation of the skin and subcutaneous tissue accompanying the invasion by *Trichophyton* of the hairy parts of the face and neck. Exudation and suppuration are set up, and pustules, abscesses, and papillary growths, are the result (Art. 405).

Eczema marginatum is an eczematous inflammation caused by *Trichophyton*, and affecting chiefly the genitals and the parts around them (KAPOSI).

412. **Pityriasis versicolor** (*tinea versicolor, mycosis microsporina*) is characterized by the appearance of uniform pale or dark yellowish or brownish patches of various sizes and shapes, and either smooth and shining or dull and scaly on the surface. They occur chiefly on the trunk, neck, and flexor surfaces of the limbs, never on the hands or feet or on the face. The epidermis is readily scraped away from the patches, and is found to contain the filaments and spores of a fungus called *Microsporon furfur* (discovered by EICHSTEDT in 1846). It grows in the horny layer

of the epidermis and does not penetrate the hairs or their follicles. It does not usually set up any hyperæmia or inflammation.

Pityriasis rosea (GIBERT) or *pityriasis maculata* and *circinata* (BAZIN) is an affection of the skin resembling ringworm, and it is stated that it is due to a filamentous fungus. According to BEHREND (*Berl. klin. Woch.* 38 and 39, 1881; 34, 1882), who calls the disease *Roseola furfuracea herpetiformis*, it is characterized by the formation of prominent rosy spots from the size of a millet-seed to that of a bean, which are covered with powdery epidermal scales. They generally occur on the neck, and thence spread quickly over the body, leaving the head, hands, and feet unaffected. The spots disappear in two or three days. In some cases the epidermal scales contain spores and delicate mycelial filaments.

HEBRA recently described (*Wiener med. Blätter* 1881) a peculiar itching mycosis of the skin affecting the neck, elbows, and hams, and due to a fungus resembling that of *pityriasis versicolor*. Small shining grayish-yellow flattened papules are formed, which are grouped in clusters or arranged in long rows.

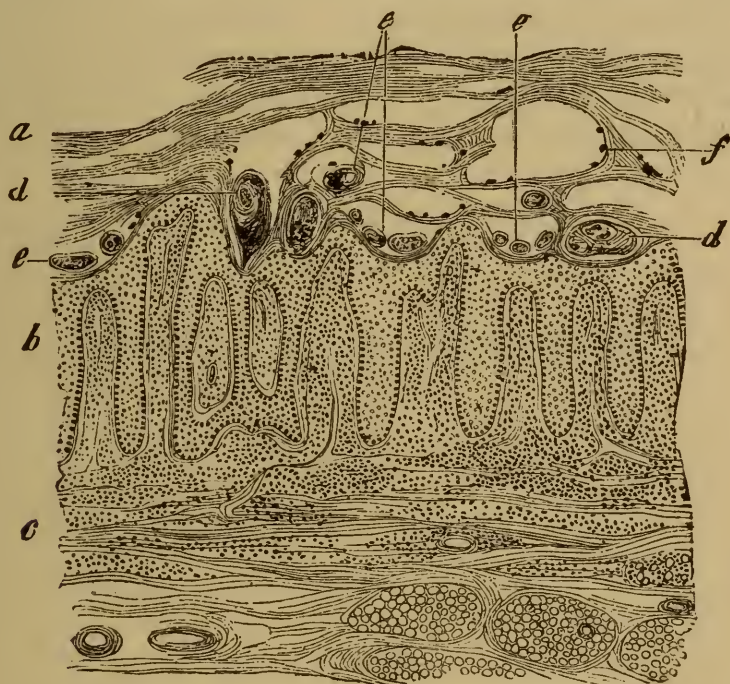


FIG. 164. SECTION OF THE SKIN IN SCABIES.

(Carminic staining : $\times 20$.)

- | | |
|--|--|
| a, horny layer traversed by numerous burrows. | c, cutis infiltrated with cells. |
| b, rete mucosum, with hypertrophied and infiltrated papillæ. | d, section through an adult itch-mite. |
| | e, eggs and embryos of various sizes. |
| | f, excreta of the itch-mite. |

413. **Animal parasites.** We have already described (in Arts. 225, 226, and 235) the various animals that infest the cutaneous tissues, and the affections to which they give rise. Here we need mention only **scabies** or itch, due to the settlement of the *Acarus scabiei* (Art. 225) in the epidermis.

The itch-mite pierces the horny layer and bores its way obliquely through it till it reaches the rete mucosum in the neighborhood of the papillæ. As the epidermal cells grow and approach the surface, it con-

tinues to work its way downwards so as always to keep below. In this way it gives rise to burrows (*cuniculi*) which penetrate the skin obliquely and are irregularly zigzagged and curved: they may reach the length of one or two centimetres. The mite sits at the blind end of the burrow (Fig. 164), leaving behind its excreta (*f*) in the form of yellow, brown, or black grains and lumps. The female also lays its eggs in the burrow, and as these are hatched the young mites may be seen in all stages of development (*e*).

The irritation caused by the mite directly and by the scratching which it induces gives rise to eczematous inflammation of the skin, with the formation of vesicles and pustules. Pus may collect beneath the burrows of the *Acarus*.

When the affection is allowed to become chronic the skin may be very gravely altered, the epidermal layers being greatly thickened and pervaded by the burrows in all directions. Inflammatory hypertrophy of the cutis takes place, and the papillæ (*b*) become enlarged and notably elongated. The horny layer (*a*) may become almost honeycombed or cavernous from the number of burrows which traverse it.

SECTION VI.

THE MUCOUS MEMBRANES.

CHAPTER XLIII.

STRUCTURE AND FUNCTIONS.

414. The **general structure** of a mucous membrane is similar to that of the skin, and its surface is everywhere in continuity with the exterior surface of the body. In textural details, however, there are considerable differences. The fibrous or reticular tissue (the **mucosa**) underlying the epithelial cells is looser and more cellular than the cutis; indeed in many parts it assumes the structure of **lymphadenoid tissue** and encloses a multitude of lymphoid elements in its meshes. The **epithelial covering** is thinner and more delicate than the epidermis, in some places consisting only of a single layer of juicy cylindrical cells; and even where the layers are numerous there is no protecting horny covering as in the case of the skin.

The mucous membranes are all well supplied with blood-vessels and lymphatics, which extend up to the epithelial strata. The vessels are in general continuous with those of the loose-textured and vascular submucous connective tissue (the **submucosa**). The submucosa is abundant in the mucous membranes of organs which are exposed to rapid and repeated changes of area and volume, and whose lining-membrane is consequently apt to be thrown into folds. In organs, like the uterus, which are not exposed to such sudden variations the submucosa is absent.

The epithelial covering of the mucous membranes is highly permeable; so that liquids and small corpuscular bodies pass in from the outer surface, or pass out and are excreted from the blood-vessels. These matters pass partly between the epithelial cells, and partly through their substance.

All the mucous membranes yield a secretion, which, apart from the liquid excreted from the vessels (usually small in amount), is characterized chiefly by the presence in it of **mucus**. The mucus is derived from certain of the epithelial cells, which elaborate it within their protoplasm and then extrude it. Lymphoid elements also escape from the reticular substructures, and passing between the epithelial cells reach the surface and form the swollen spherules known as **mucus-corpuscles**. According to STÖHR they are most abundant where the mucosa contains lymphadenoid tissue.

The mucus secreted by the membrane is of great service to it both in normal and in morbid conditions. It forms a protective covering,

and is often of use in warding off the effects of noxious substances or influences which may tend to affect the membrane injuriously. In certain circumstances the extruded lymphoid elements may act in a similar way. If the two together are insufficient to remove or to withstand the noxious agency, the mucous membrane undergoes more or less extensive alteration and injury.

Noxious matters also reach the membrane from within by way of the blood, but the injuries so produced are on the whole less important than the former class.

CHAPTER XLIV.

HYPERÆMIA AND HÆMORRHAGE.

415. **Congestive hyperæmia.** Many of the mucous membranes are physiologically subject to periodic hyperæmia. The blood-supply of the alimentary canal during digestion, and of the uterus during menstruation, is very strikingly increased. The increase is governed by vasomotor influences transmitted through the nerves, in obedience to which the afferent arteries are dilated, and so convey more blood to the parts.

Morbid influences may likewise give rise to hyperæmia, either by paralyzing the vaso-constrictor, or stimulating the vaso-dilator nerves. The morbid stimuli may act on the central nervous system, or, by reflex action, on the mucous membrane itself. The swallowing of hot food makes the stomach hyperæmic; the inhalation of irritating vapors or the act of rubbing the eyelid will determine blood to the bronchi or the conjunctiva respectively.

A mucous membrane when hyperæmic becomes intensely reddened, and the distended vessels can be distinguished on close examination. At the same time the secretion becomes more abundant, often visibly so after the congestion has lasted a little time.

Passive hyperæmia or engorgement usually gives rise to livid redness; but if the membrane is exposed to the air (as in the case of the lungs) the tint may be almost arterial. Long-continued venous engorgement frequently leads to abiding varicose dilatation of the veins. If œdema results from the engorgement, the membrane usually swells up and assumes a sodden appearance. Where the submucosa is loose and open (as in the intestine) the swelling is sometimes very remarkable, the transuded liquid collecting in great abundance in the meshes of the tissue.

416. **Hæmorrhages** occur very frequently in the mucous membranes. They may be slight, giving rise merely to minute specks of ecchymosis and the mingling of a few red corpuscles with the ordinary secretion; or so abundant that the membrane itself is soaked with blood, which at the same time pours away from the free surface. Excessive hæmorrhages of this kind often occur without any perceptible cause, especially in persons congenitally predisposed to bleeding (Art. 28). Many persons are particularly subject to bleeding from the nasal mucous membrane; others bleed from the surface of the large or small intestine or from the bladder, sometimes to such an extent that death ensues. Congestion, thrombosis,

embolism, wounds, disease of the vessels, may any of them give rise to hæmorrhage, and some of the inflammations of the mucous membrane are apt to assume a hæmorrhagic character, or at least to be accompanied by extravasations of blood. Such extravasations may be due to diapedesis or to actual rupture of the vessels.

The consequences of hæmorrhage are various : small extravasations are re-absorbed, but often (as in the intestine) leave behind slaty or black discolorations which may persist for a long time. Frequently the tissue infiltrated with blood necroses and breaks down ; erosions and ulcers are thus produced, which at times reach a considerable size. After extensive hæmorrhage, such as results from intense and enduring engorgement, large and continuous portions of the tissue may perish, and gangrene not uncommonly sets in.

CHAPTER XLV.

DEGENERATION, ATROPHY, AND HYPERTROPHY.

417. The various forms of retrogressive change described in Arts. 32-71 may all of them affect the mucous structures.

Necrosis occurs chiefly as the result of mechanical or chemical injury, and also of disorders of the circulation and inflammation. The changes produced are treated generally in Arts. 32-71, and with reference to particulars in Arts. 424-427. The issue of necrosis is always local inflammation and ulceration; repair takes place by regenerative growth, or by granulation and cicatrization.

In considering the various modes of degeneration it is convenient to separate the changes in the epithelial elements from those in the fibrous tissues of the mucous membrane. The former show signs of degenerative change much more frequently than the latter. One of the commonest manifestations is an abnormal increase of the mucous secretion (**catarrhal inflammation**, Art. 420). Fatty degeneration of the epithelial cells is also common; and abnormal and premature desquamation plays a considerable part in certain of the inflammatory processes. The fibrous structures are especially liable to **amyloid disease**, especially in the intestine. The walls of the vessels are the favorite seat of the degenerative change. The fibrous structures are sometimes affected by mucoid and fatty degeneration, but they are much less liable to such changes than the epithelium.

Atrophy of the mucous membrane, by which the epithelium is in part destroyed, is a condition of the greatest importance. In the alimentary canal the process can be followed in its most typical form; it is usually connected with or dependent on catarrhal inflammation.

It will be remembered that the mucosa of the intestine is mainly composed of a glandular stratum containing lieberkühnian crypts with the underlying muscularis mucosæ. The glandular stratum is about 0.4 to 0.5 mm. in thickness. In catarrhal conditions the epithelium is loosened and cast off in abnormal quantity; the fibrous tissue between the crypts is densely infiltrated, and often degenerates or suppurates (Art. 421, Fig. 167), so that the epithelium may in part be permanently lost. The glandular stratum is in consequence often wasted to the half or the third of its former thickness (Fig. 165), or the glands may disappear entirely (*e*) leaving nothing but a thin nucleated fibrous film.

The muscularis mucosæ is in general but slightly affected, though it too may become atrophied. The submucosa is usually little altered, unless the inflammation is very intense; and if the inflammation does not pass into ulceration, the lymphatic tissue of the mucosa remains almost intact.

The mucous membranes of the stomach, uterus, etc., are affected in much the same way. Their glands are usually atrophied or obliterated, but in some cases they may undergo a kind of cystic degeneration.

418. The **power of repair** which the mucous membranes possess is exemplified in the rapid restoration of lost epithelium. But this restoration is only complete if the underlying fibrous structures are themselves uninjured, or at least effectively restored. If from any cause a small portion of the fibrous coat is destroyed, the regeneration of the corresponding epithelium is imperfect. If the portion destroyed is of any

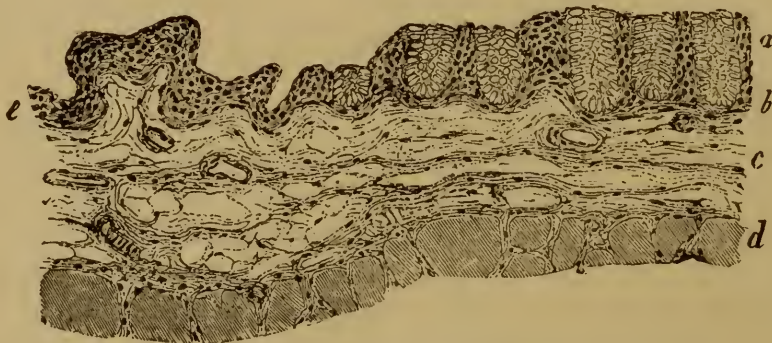


FIG. 165. MUCOSA AND SUBMUCOSA OF AN ATROPHIC INTESTINE.

(Alum-carminé staining: $\times 80$.)

- | | |
|---|--|
| <p><i>a</i>, glandular layer reduced to a half of its normal thickness.</p> <p><i>b</i>, muscularis mucosæ.</p> | <p><i>c</i>, submucosa.</p> <p><i>d</i>, outer muscular coat.</p> <p><i>e</i>, atrophy complete.</p> |
|---|--|

great size, repair is effected by granulation and cicatrization, or a chronic open ulcer is formed.

As regards **hyperplasia**, the various membranes comport themselves in different ways. Hyperplasia of the uterine mucous membrane is very common; in the bladder, œsophagus, and small intestine it is rare. The hyperplasia is manifested as a more or less extensive thickening of the membrane, or in the production of localized papillary, polypous, or fungous excrescences. These changes are most commonly met with in the uterus, stomach, colon, and nose.

The thickened or polypous membrane may be altogether normal in its apparent structure. But as the hyperplastic process is very frequently associated with some form of inflammation, the overgrown portions usually exhibit certain morbid alterations. The epithelium is often atrophied, the glands obliterated or transformed into cysts (Art. 422), while the fibrous elements are increased, and infiltrated with cells. In other instances the glands may be hypertrophied.

CHAPTER XLVI.

INFLAMMATORY AFFECTIONS.

419. The inflammations of the mucous membranes are the commonest of all affections, and they play a very considerable part in pathology. In by far the greater number of cases they are induced by noxious agencies acting on the external surface of the membrane; they are rarely due to noxious matters carried to it by the circulation. Thus cystitis, that is inflammation of the mucous membrane of the bladder, is often caused by the action of morbid or decomposed urine; intestinal inflammation by the ingestion of irritant substances; and bronchial inflammation by the inhalation of impure air. Symptomatic inflammations are met with chiefly in connection with certain general infective diseases.

The intensity, extent, and duration of the inflammations of the mucous membranes vary greatly in different cases; and a number of different forms are distinguished accordingly.

420. In **catarrhal inflammations**, as the name implies, the characteristic feature is a morbid increase of the secretion of the membrane. Hyperæmia is of course present, and often to a remarkable degree in the early stages, but the alteration in the nature and amount of the secretion is the distinguishing character.

The catarrhal secretion is furnished partly by the blood-vessels and partly by the epithelial cells. In the early stages the blood-vessels permit the extravasation of an abundant colorless or sometimes blood-stained liquid, containing a multitude of white corpuscles (Fig. 166, 1) interspersed with a few red ones. When the secretion consists essentially of this liquid exudation, we have what is called **serous catarrh**.

The liquid exudation from the blood-vessels is always mingled with secretions from the epithelial cells. These cells normally produce mucus from their protoplasmic contents—the cylindrical cells chiefly, but to some extent also the stratified pavement epithelial cells, like those of the bladder. The process may be well observed in the cells of the intestinal and bronchial epithelium; the so-called goblet-cells of these membranes being simply mucus-forming structures. In catarrh the production of mucus is much increased, the number of goblet-cells (Fig. 166, 6) becoming considerably greater than in normal conditions. Great quantities of glassy mucus are thus deposited on the membrane, or, as in the case of nasal catarrh, are cast off from its free surface. If the membrane con-

tains mucus-glands their secretion is simultaneously increased, and mingles with that of the lining epithelium.

At first the changes just described are the only ones, or at least the only ones that are obvious. Sooner or later however other changes set in, unless the inflammation speedily subsides and the membrane recovers. The epithelial cells begin to be shed, and the secretion is rendered turbid by their presence. These cells vary of course in appearance with the character of the membrane to which they belong. From cylindrical epithelium we get cylindrical cells (3), which are swollen and translucent or altogether in a state of mucoid degeneration (Art. 55). Goblet-cells (6), ciliated cells (5), squamous pavement cell (11, 12, 18), are all met

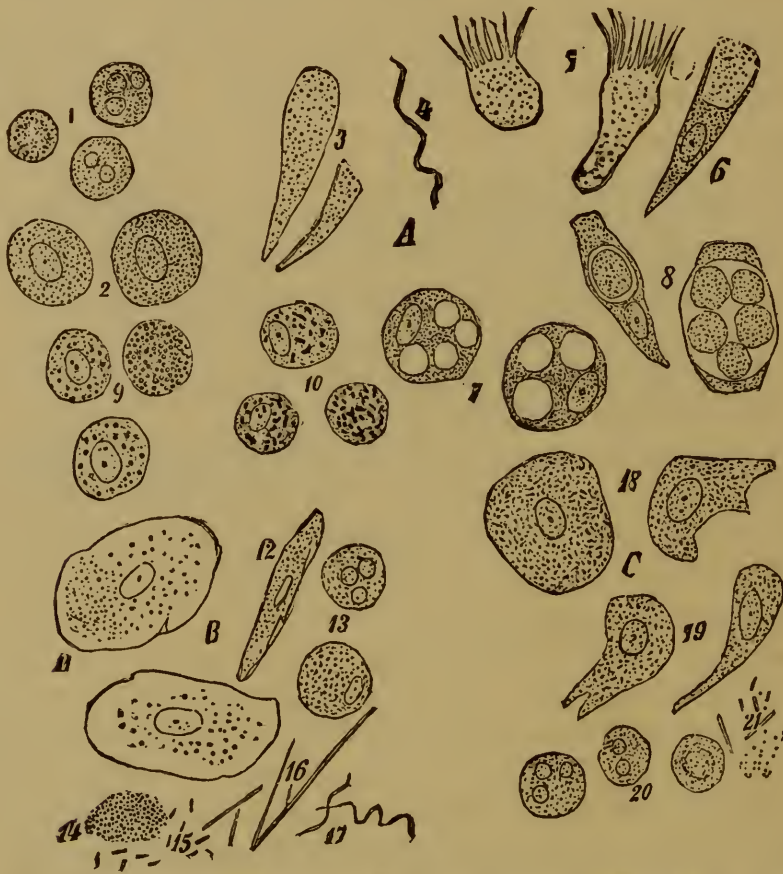


FIG. 166. CATARRHAL SECRETIONS FROM VARIOUS MUCOUS MEMBRANES. ($\times 400$.)

A from cylindrical epithelium, B from the mouth, C from the bladder. 1, leucocytes (pus-corpuscles). 2, large leucocytes with clear nuclei from the nose. 3, mucoid cylindrical cells from the nose. 4, *Spirillum* from the nose. 5, mucoid ciliated cells from the nose. 6, goblet-cell from the trachea. 7, leucocytes from the nose, containing masses of mucus. 8, epithelial cells from the nose, containing pus-corpuscles. 9, fatty cells from cases of chronic laryngeal and pharyngeal catarrh. 10, cells from sputum containing soot-pigment. 11 and 12, squamous epithelium from the mouth. 13, mucus-corpuscles. 14, micrococci. 15, *Bacterium termo*. 16, *Leptothrix buccalis*. 17, *Spirochaeta denticola*. 18, cells from the surface layer—and 19, from the deeper layers—of the bladder. 20, pus-corpuscles. 21, *Schizomyces* or bacteria.

with in catarrhal secretions. Where the epithelium is stratified the polymorphous cells of the deeper layers (19) may be shed with the superficial cells. When the secretion thus contains a considerable proportion of shed epithelial cells we have what may be called **epithelial catarrh**.

In the later stages we may have not only an excessive desquamation of the epithelium, but also an abundant extravasation of leucocytes from the superficial blood-vessels. Many forms of catarrhal inflammation are thus characterized by an almost purulent secretion, and are described as **purulent catarrh**. The leucocytes may be small and uninuclear, or may appear multinuclear in consequence of the breaking-up of their nuclei into fragments (1, 13, 20). In recent cases they are often swollen and slimy-looking, and constitute the so-called mucus-corpules (13). Sometimes spherical cells are met with, which contain transparent globules of mucus in their interior (7); and the smaller leucocytes may at times penetrate into the substance of the degenerate and desquamated epithelial cells (8). Such cells have been mistaken for brood-cells. In chronic catarrhs some of the cells undergo fatty degeneration (9); while others contain particles of dust or soot (10) derived from without.

The components of the catarrhal secretions above referred to are such as come from the mucous membrane itself. Many extrinsic substances may however be found mingled with these. In catarrh of the bladder we often find crystalline deposits from the urine mixed with the mucous secretion; the secretion of intestinal catarrh is always mingled with matters derived from the food. Bacteria are also very frequently met with (4, 14, 15, 16, 17, 21), in the various forms of micrococci, bacilli, and spirilla. They are in part to be regarded as unimportant accidental impurities, in part as irritants inducing or maintaining inflammation. It is impossible at present to decide the part taken by the different forms.

421. Catarrhal inflammations of the mucous membrane are usually transient. The characteristic symptoms sooner or later disappear and complete restoration follows. Sometimes however the process becomes chronic, and then certain secondary changes are induced.

In addition to the alterations in the secretion and the epithelial cells already mentioned, a membrane affected with catarrh shows signs of cellular infiltration in the connective tissue of the mucosa and often also of the submucosa; and this infiltration is in some cases very considerable. When complete restoration takes place the infiltrated cells disappear either by migration to the surface, or by passing into the lymphatics, or by disintegration and absorption. Where the epithelium has been lost by desquamation repair is effected by multiplication of the remaining epithelial cells.

This result is however not invariable; the inflammation may become intensified so that the tissues perish over some considerable extent, or continuing to be of moderate intensity it may be unduly protracted, and so occasion extensive alteration in the tissues.

The intensification of the inflammatory process is manifested histologically as an increase of the cellular infiltration. Thus, for instance, in the colon the surface layers of the connective tissue separating the lieberkühnian crypts may be densely infiltrated with leucocytes (Fig. 167 *d*). The overlying epithelium is soon lost; that of the crypts per-

sists, but it is often loosened and separated from its basement tissue. In the later stages it also may be shed altogether and extruded from the crypts.

When the infiltration is extreme the tissue perishes by necrosis. Patches of various sizes die outright and are cast off with the pus which is secreted from the surface (*f*). In this way ulcers (*g*) are produced which may be large or small according to the extent of the initial necrosis. The lymph-follicles, in membranes that possess them, are often the chief seat of the inflammation and ulceration. Ulcers starting in them are known as **follicular ulcers**. When catarrh of a mucous membrane passes into ulceration the inflammatory infiltration usually extends far beyond the limits of the ulcer. Thus in dysenteric ulceration of the colon the submucosa (*e*) is infiltrated as well as the mucosa (*d* *d*₁).

422. When the inflammatory process is of long duration, a certain

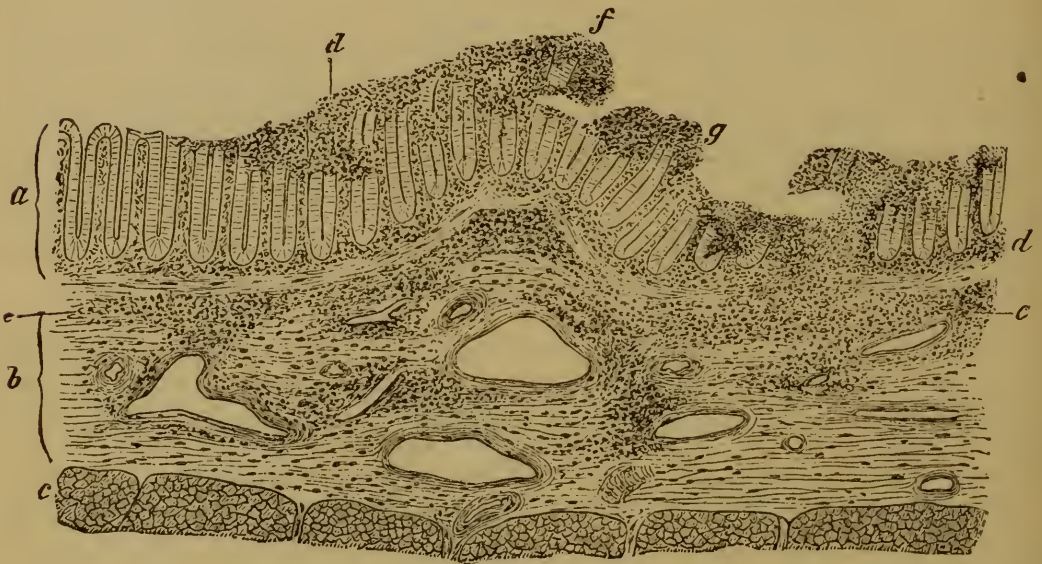

FIG. 167. SECTION OF THE COLON FROM A CASE OF DYSENTERY.

(Hæmatoxylin staining: $\times 25$.)

a, mucosa.

b, submucosa.

c, muscular coat.

d, infiltration of the mucosa between the crypts.

*d*₁, infiltration beneath the crypts.

e, infiltration of the submucosa.

f, infiltration of the superficial glandular layers which are in process of desquamation.

g, ulcer with infiltrated floor.

amount of **fibrous hyperplasia** takes place, and that whether the process is accompanied by ulceration or not. In the former case the hyperplastic tissue often takes the form of papillomatous outgrowths from the borders of the ulcer, and these sometimes reach a remarkable size. Even where there is no ulceration similar papillomatous, warty, or cauliflower excrescences may be formed. In other cases the fibrous hyperplasia is more diffuse, giving rise merely to bands and unevennesses of the surface; but both forms are often found associated.

Thus after long-continued catarrh of the stomach the mucous membrane has often a grayish tint and is rough with dense fibrous bands and nodes, or it is beset with ridges and prominences which do not disappear when the organ is distended (Fig. 168). These prominences are at least in part due to fibrous overgrowth (*e*).

When the membrane contains glands, the openings of some of them become obstructed, and they are thus distended into **cysts**. Some of the glands may be obliterated altogether by the destruction of their epithelium. In other cases new glands are formed, or at least papillary outgrowths covered with epithelium spring up from the walls of the glandular cysts. The growths thus produced, which depend much more on fibrous than on glandular hyperplasia, often resemble tumors, and have been incorrectly described as adenomata (Art. 167). They occur chiefly in the stomach and uterus, and might appropriately be called **inflammatory papillomata**.

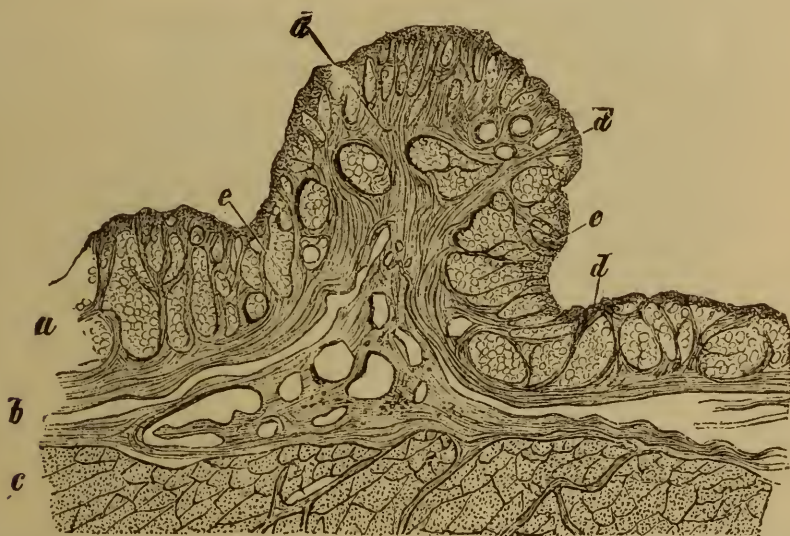

FIG. 168. ATROPHY OF THE GASTRIC GLANDS WITH FIBROUS HYPERPLASIA OF THE MUCOSA.

(Hæmatoxylin staining: $\times 10$.)

a, mucosa.
b, submucosa.
c, muscular coat.

d, hyperplastic fibrous tissue.
e, gastric glands.

When the membrane contains lymphadenoid tissue, this may likewise become hyperplastic under the influence of long-continued catarrhal inflammation. The follicles are enlarged and project as rounded nodules from the mucous surface.

423. **Croupous inflammation.** When a mucous membrane is so injured that its epithelium is here and there partially destroyed, and at the same time its blood-vessels are so damaged that an abundant exudation is poured out on the surface, coagulation of the latter may take place in the manner described in Art. 35. In this way a pale yellowish membrane (Fig. 169 *a*) is formed on the surface consisting of fibrinous

filaments and granules beset with pus-corpuscles, or of shining homogeneous blocks (*c*) representing cells which have undergone coagulative necrosis. This **false membrane** is connected with the underlying structures by fibrinous threads, but it is usually loosely adherent, and can be readily stripped off disclosing the red hyperæmic mucous membrane beneath. An inflammation of this kind in which the surface exudations coagulate in a loosely-adherent false membrane is described as croupous. It implies a somewhat abundant extravasation of liquid and of cells, and the absence of such agencies as hinder coagulation. The epithelial cells are always more or less injured, being either necrotic or in process of degeneration and desquamation; but this injury of the cells need not precede the appearance of the inflammation. Inflammatory disturbance of the circulation may be the primary lesion, and the alteration of the epithelium secondary.

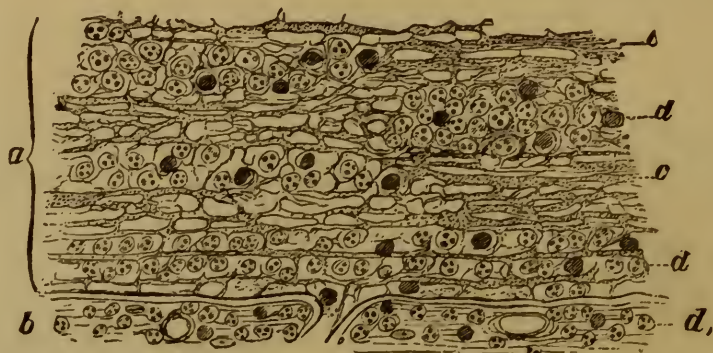


FIG. 169. CROUPOUS MEMBRANE FROM THE TRACHEA. ($\times 250$.)

a, section through the false membrane.

b, upper layer of the mucous membrane, infiltrated with pus-corpuscles (d_1).

c, filaments and granules of fibrin.

d, pus-corpuscles.

The fibrous structures of the inflamed mucous membrane always contain liquid and cellular exudations. If the liquid lie in the larger lymph-spaces or in dilated lymphatics it also may coagulate and give rise to fibrous-looking clots, rarely to homogeneous and continuous masses. We might in such cases say that the croupous inflammation was deep or parenchymatous, as well as superficial in the ordinary sense.

Croupous inflammation occurs chiefly in the respiratory mucous membranes, rarely in the alimentary tract.

424. **Diphtheritic inflammation.** When a mucous membrane is injured in such a way that its epithelium dies without desquamation, while its blood-vessels are damaged and pour out an abundant exudation, it sometimes happens that the dead epithelial cells become saturated with the exuded liquid and then pass into a peculiar condition of rigidity akin to coagulation. The seat of this change appears to the naked eye as a dull grayish raised patch surrounded by red and swollen mucous membrane (Fig. 170). The exudation is rich in albumen, and the trans-

formed cells take on the appearance of a kind of coarse mesh-work (*c*) almost or altogether devoid of nuclei. The subepithelial areolar tissue (*d*) is beset with filaments of fibrin and leucocytes. Hæmorrhages (*f*) are not uncommon. Inflammations of this kind, in which the tissue itself coagulates into a solid mass, are called diphtheritic. When the necrosis and coagulation extend only to the epithelium we may speak of the process as **superficial diphtheritis**.

As we said in speaking of the croupous membrane it is by no means necessary that the whole of the epithelium ultimately affected should perish at the outset; some part of it at least may perish secondarily, in consequence of the inflammation.

Superficial diphtheritis occurs chiefly in the organs of the throat, but the conjunctiva and the epithelium of the urogenital organs are also ce-

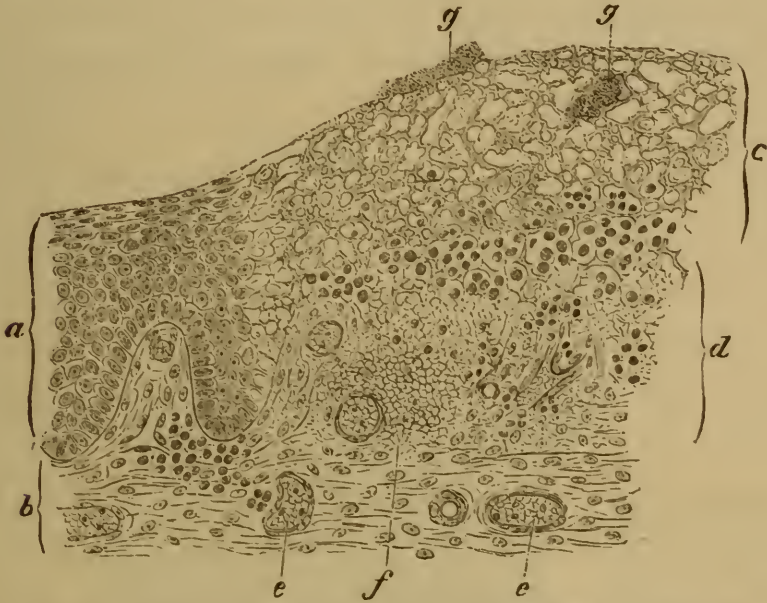

FIG. 170. SECTION THROUGH THE UVULA IN DIPHTHERITIS FAUCIUM.

(Aniline-brown staining: $\times 75$.)

- | | |
|---|---|
| <i>a</i> , normal epithelium. | <i>d</i> , areolar tissue infiltrated with fibrin and leucocytes. |
| <i>b</i> , normal areolar tissue. | <i>e</i> , blood-vessels. |
| <i>c</i> , necrosed epithelium transformed into a coarse mesh-work. | <i>f</i> , hæmorrhage. |
| | <i>g</i> , heaps of micrococci. |

asionally attacked. The structure of the respiratory organs and the intestine seems not to favor this form of inflammation. When their epithelium perishes from any cause it is usually shed or dissolved away, and a croupous false membrane is formed instead of the diphtheritic coagulation.

It thus appears that croupous inflammation and what we have called superficial diphtheritis are very closely related. Speaking generally the distinctive characters of the two processes are chiefly conditioned by the structure of the mucous membranes which they affect. Still it is convenient to assign distinctive names to them, and to reckon all cases in which the epithelium coagulates *en*

masse as diphtheritic. Necrosis and coagulation of the tissue are the distinguishing features of diphtheritic inflammation; whether it is superficial or deep its nature is the same, the mere seat is of secondary importance.

Inasmuch then as the croupous membrane consists essentially of coagulated exudation, croupous inflammation is at once distinguished from superficial diphtheritis. Nothing but confusion can result from speaking of the latter as pseudo-croup or pseudo-diphtheritis. True croupous inflammation may occur in mucous membranes that are normally covered with stratified epithelium, when the superficial cells have been destroyed and shed.

425. Deep or **parenchymatous diphtheritis** affects a greater extent of tissue than the superficial form. It is characterized by the coagulation not merely of the epithelium but also of the underlying connective tissue. The affected patch is swollen and assumes a whitish or grayish tint, the discoloration extending through the epithelium to the connective-tissue structures. The epithelium in some cases is lost altogether, and then the diphtheritic patch consists of dead connective tissue only (Fig. 171). The patch is turbid and granular in texture, or it may be

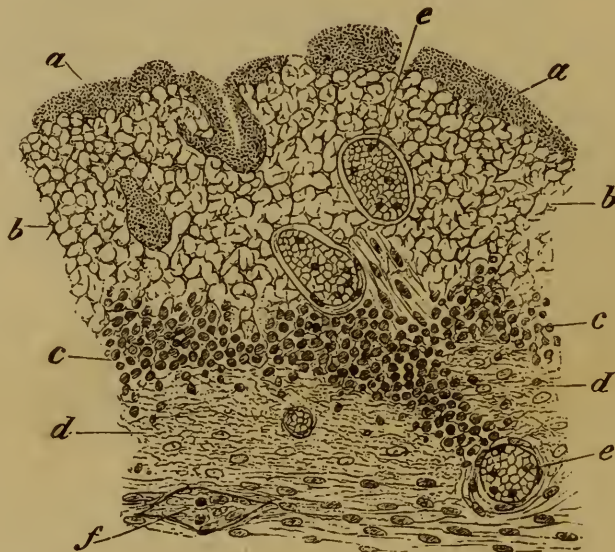


FIG. 171. SECTION OF THE UVULA FROM A CASE OF DIPHTHERITIS FAUCIUM.

(The epithelium has been shed: aniline-brown staining: $\times 100$.)

- | | |
|--|--|
| <i>a</i> , micrococci. | <i>d</i> , fibrinous exudation. |
| <i>b</i> , submucous tissue changed into amorphous blocks. | <i>e</i> , blood-vessels. |
| <i>c</i> , extravasated leucocytes. | <i>f</i> , lymphatic vessel containing cells and fibrin. |

homogeneous, or composed of amorphous hyaline blocks (*b*). The nuclei are always more or less completely lost. The small vessels (*e*) which permeate the patch show signs of a homogeneous transformation of their walls.

The dead tissue is separated from the living by a zone of cellular infiltration (*c*). Fibrinous filaments (*d*) are seen here and there through the mass. The lymphatics (*f*) in the neighborhood contain coagula and leucocytes.

Necrotic inflammation may attack any of the mucous membranes; it

is especially common as a result of infection of one kind or another. We are frequently able to demonstrate that it is associated with the invasion of the tissue by bacteria (a).

References on croupous and diphtheritic inflammation:—BRETONNEAU, *De la diphthérie* Paris 1826-27, *Arch. générales* 1855, *Memoirs on diphtheria* (New Syd. Soc.) 1859; VIRCHOW, *Handb. d. spec. Path. u. Ther.* I. Berlin 1854, and *Berl. klin. Woch.* 2, 1865; WAGNER, *Arch. d. Heilk.* VII., VIII., *Handb. d. allg. Path.*, *Ziems-sen's Cyclop.* VII.; CORNIL and RANVIER, *Man. Path. Hist.* I. London 1882; WEIGERT, *Virch. Arch.* vols. 70, 72, 80, and Art. *Entzündung in Eulenburg's Realen-cyclop.*; ZAHN, *Beiträge z. path. Hist. d. Diphtheritis* Leipzig 1878; LEITZ, *Diphtherie u. Croup* Berlin 1877; OERTEL, *Ziems-sen's Cyclop.* II.; SCHWENINGER, *Arbeiten a. d. path. Institute* Munich 1878; COHNHEIM, *Allg. Pathologie* I. Berlin 1881; HEUBNER, *Die experimentelle Diphtherie* Leipzig 1883.

426. The formation of the necrotic patch or slough is of course not the final stage of the diphtheritic process. The sloughs themselves act as irritants and set up inflammation around them. Superficial epithelial sloughs become in this way infiltrated with pus and so are loosened and cast off. The loss of substance is then made good by regenerative multiplication of the remaining epithelial cells. Larger and deeper sloughs may in like manner be separated by suppurative inflammation taking place around them, and the deficiency is then made up by the formation of a cicatrix, which in process of time may be covered over with new epithelium. But the process often maintains its destructive character for a considerable time, extending continually to greater depths, and often inducing intense purulent inflammation over a wide area around the initial lesion.

Sometimes the necrotic inflammation takes on a **gangrenous** character, that is to say micro-organisms penetrate the diseased tissues and set up in them septic or putrid decomposition. The affection is then much more grave, for the products of decomposition act as highly noxious irritants on the tissues that are still healthy. Definitive suppuration may however in this case also lead to the separation of the dead tissue from the living, and so allow the process of repair to begin.

427. **Phlegmonous inflammation.** In speaking of catarrh we said that the inflammatory process might become so intensified that it passed into the purulent form, that is to say into suppuration. In addition to this purulent catarrh we occasionally meet with a suppurative form of inflammation in which the exudation is purulent or fibrino-purulent, but is not like the former merely superficial. This form gives rise to diffuse purulent infiltration of the mucosa and submucosa, which may in consequence become enormously swollen and as it were saturated with pus. If the patient survives, large portions of the submucosa may break down and dissolve in the purulent exudation. This form corresponds to phlegmonous inflammation of the integument (cellulitis), and is also described as phlegmonous. It occurs in the mucous membranes

of the pharynx and stomach, and rarely elsewhere. It is due to some microparasitic infection.

When the affection is recent the tissues are everywhere infiltrated with liquid and cellular exudations and with pus-corpuscles. Here and there granular and fibrillated coagula are seen, and presently the infiltrated tissue and the extravasated cells become necrosed. The cells then look turbid and granular, lose their nuclei, and disappear; and the epithelium and connective tissue perish in like manner.

CHAPTER XLVII.

INFECTIVE GRANULOMATA AND TUMORS.

428. **Tuberculosis** of the mucous membranes is one of the commonest of all diseases. In post-mortem examination we generally meet with it in the form of tuberculous ulceration, but opportunities often occur for studying the process in its early stages. It begins as a cellular infiltration of the sub-epithelial tissue, which is either localized in definite nodules, or diffusely scattered with here and there slightly marked aggregations. If there are any lymph-follicles in the tissue the infiltrated cells tend to accumulate round them. The smallest nodules of all have often no very characteristic appearance, but they occasionally contain giant-cells. Caseation usually sets in early (*c*). The tubercu-

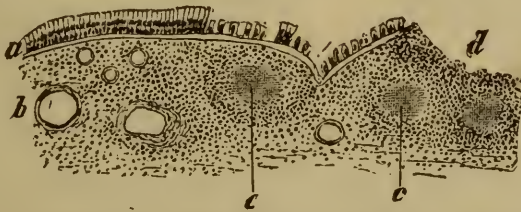


FIG. 172. TUBERCULOSIS OF THE BRONCHIAL MUCOUS MEMBRANE. ($\times 25$.)

a, epithelium. *c*, tubercle.
b, infiltrated fibrous tissue of the mucosa. *d*, border of a small ulcer.

lous nodules, which at first project somewhat above the surface of the membrane, become thereupon white and opaque. Disintegration speedily follows; the sub-epithelial nodules break through the epithelium, and rounded or sinuous ulcers of various sizes (Fig. 172 *d* and 173 *h*) are formed. The floor and margins of such ulcers are infiltrated with cells, the surface portions being necrotic. Tubercles are often but not always found seated in the infiltrated zone.

In the mucous membrane of the bronchi and bladder the tuberculous growths do not attain any large size. In the larynx, glottis, and epiglottis the sub-epithelial granulomatous tissue may sprout into fungous growths resembling exactly the fungating granulomata of bone (Art. 121). The epithelium is thereby raised into warty excrescences, and when they break down more or less extensive ulcers are produced.

Tuberculous disease of the large and small intestine resembles that of the laryngeal mucous membrane, but the ulcerations are usually much larger. The tubercles (Fig. 173 *i i*) are seated chiefly in the submucosa;

the cellular infiltrations of the mucosa are less definitely aggregated. When the tubercles break down cavities are formed in the submucosa (h_1), which we may call **tuberculous abscesses**, and these gradually extend into and through the mucosa and ultimately form open ulcers on the surface (h).

The **tuberculous ulcer** when once formed usually advances by progressive disintegration of its infiltrated margins. The infiltration of cells and their aggregation into tubercles being very irregular in their course (Fig. 173), the process of disintegration is also irregular, and consequently the outline of a tuberculous ulcer of any great size is usually without any regularity. Its margins are often red and swollen and beset with grayish and yellowish nodules, or they may be but slightly swollen

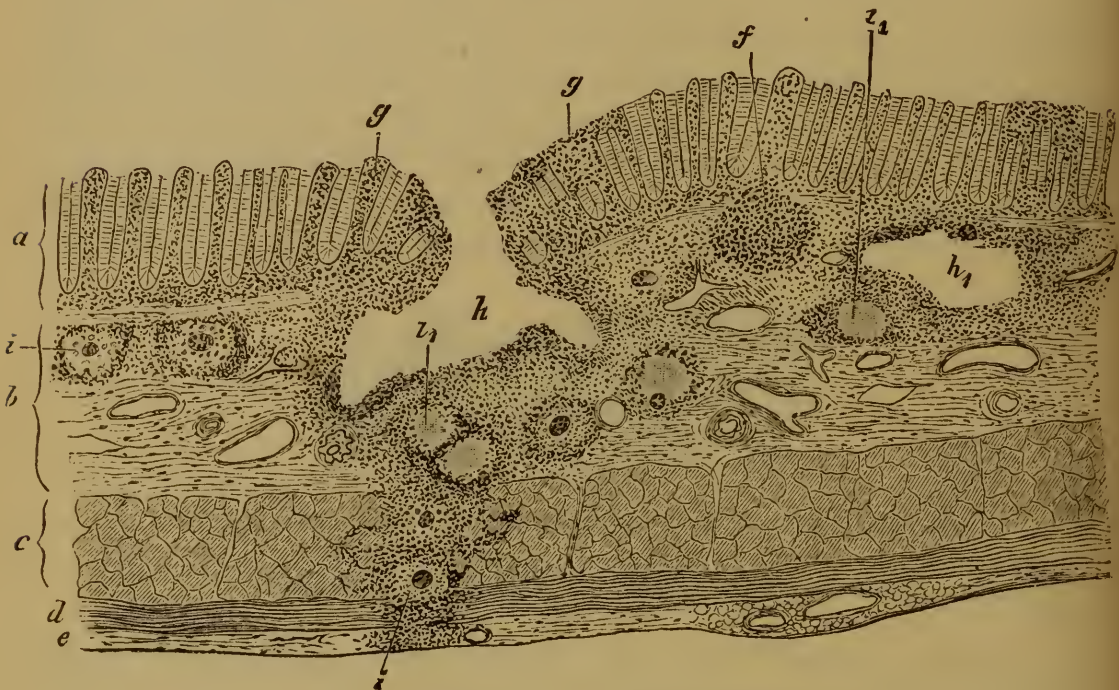

FIG. 173. TUBERCULOSIS OF THE LARGE INTESTINE.

(Bismark-brown staining: $\times 30$.)

- | | |
|-------------------------------|--|
| a , mucosa. | g , cellular infiltration of the mucosa. |
| b , submucosa. | h , tuberculous ulcer. |
| c , internal muscular coat. | h_1 , tuberculous abscess. |
| d , external muscular coat. | i , recent tubercle. |
| e , serous coat. | i_1 , caseous tubercle. |
| f , solitary follicle. | |

and sharply cut or even undermined. The floor is uneven and often beset with yellowish nodular deposits. Sometimes papillary outgrowths of considerable size arise from the margins and floor of the ulcer.

Complete repair very seldom takes place in a tuberculous ulcer. When it does it is by the separation and extrusion of the whole of the diseased tissue, healthy granulations springing up beneath it. From these cicatricial tissue is elaborated, which at length is covered over with epithelium growing in from the borders.

In most cases however the process advances steadily, and if death does not intervene a very extensive destruction of tissue is the result.

429. **Syphilis** gives rise to simple catarrhal inflammations of no great severity, and also to granulating ulcers analogous to those of tuberculosis. The ulcers begin as soft grayish-white elevations of the mucous membrane corresponding to the syphilitic condylomata of the skin. These look like hyperplastic follicular structures, but as a fact they do not start in the follicles. Cases do however occur in which the follicles are affected by syphilis; and then they become enlarged and speedily break down. The granulomatous syphilitic growths are seated chiefly in the mucosa and submucosa. When fully developed and about to break down they consist of simple cellular tissue exactly resembling granulation-tissue.

The first thing to appear is an eruption of small soft rounded nodules, which are often highly vascular. Sometimes (especially in the larynx) this is accompanied by the appearance of larger nodulated growths. These growths break down and form ulcers which continue to advance by progressive disintegration of their margins and floor. The diseased tissue is grayish or yellowish in tint. When the process comes to an end puckered scars and papillary excrescences are left. Syphilitic ulcers of this kind are met with chiefly in the mouth, pharynx, larynx, vagina, and rectum (Art. 435).

430. **Glanders** of the mucous membrane begins with the formation of small sub-epithelial nodules (Art. 135), which are generally larger than those of tuberculosis; sometimes indeed (as in the stomach) they are as large as a hazel-nut. Caseation, suppuration, and ulceration speedily ensue; the ulcers being covered with yellowish muddy-looking shreds of necrotic tissue, while their margins are red and hyperæmic. The foci of infection are usually numerous, new ones forming in contiguity to the old ones, and in this way, as successive ulcers coalesce, large irregular sinuous open sores are formed. They secrete a dirty creamy pus. When they heal they give rise to irregular puckered scars.

In horses the affection attacks chiefly the mucous membrane of the nose; it is rare to meet with it elsewhere, though sometimes the entire alimentary canal is beset with the characteristic nodules. Glanders of the mucous membrane in man is on the whole a rare affection.

Lupus affects the mucous membrane of the nose, mouth, pharynx, larynx, and perhaps the vagina; in course and appearance it exactly resembles the skin-affection (Arts. 132, 392).

Leprosy (Arts. 131, 392) appears as a nodular or diffuse infiltration of the mucous membrane of the mouth, pharynx, larynx, nose, and eyes. The nodules break down and give rise to leprosy ulcerations.

431. The most important **tumors** of the mucous membranes are unquestionably adenoma and carcinoma. Other kinds are on the whole rarely met with, though cases are recorded of lipoma (in the intestine),

sarcoma (intestine, uterus), myxoma (vagina), fibroma (uterus, stomach), and lymphoma. The tumors which originate in the connective tissue usually take the form of rounded swellings projecting above the surface of the mucous membrane.

Adenoma (Arts. 167-169) appears in two different forms; either it is confined to the mucosa, or it extends into the submucosa and thence into the surrounding tissues and organs. The first form gives rise to polypous tumors whose general structure corresponds closely with that of the mucosa; that is to say though the glandular elements are larger, more numerous, and less regular than in the normal tissue, they exhibit the typical gland-structure characteristic of the membrane. They may most

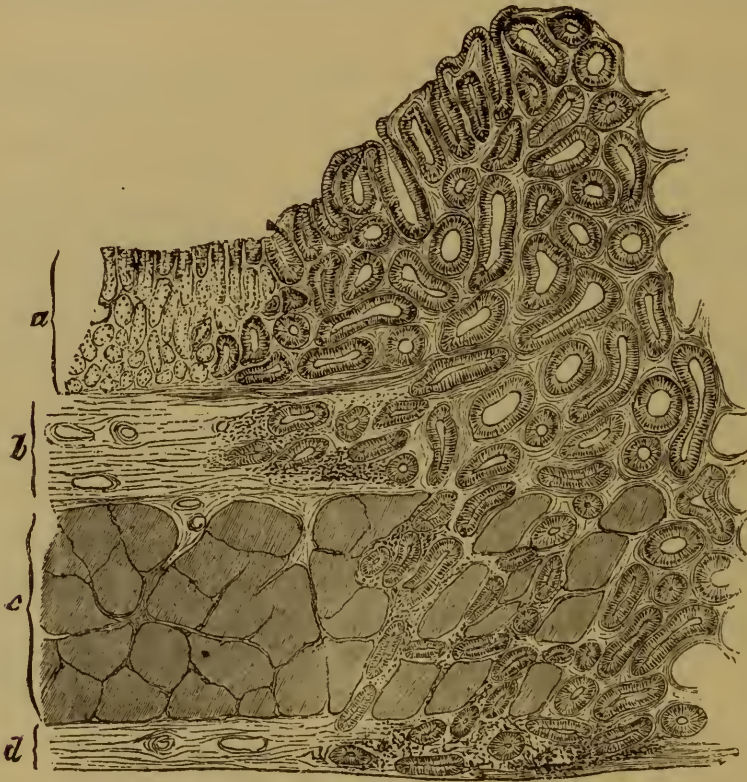


FIG. 174 A. DESTRUCTIVE ADENOMA OF THE STOMACH.
(Hæmatoxylin staining: $\times 25$)

a, mucosa. b, submucosa. c, muscular coat. d, serous coat.
e, adenomatous neoplasm starting from the mucosa and invading the other coats.

appropriately be described as **glandular hyperplasias** of the mucous membrane. The second form of adenoma, described as destructive adenoma, **adenocarcinoma**, or sometimes epithelioma, also agrees in structure with the glandular type, but its mode of growth and its tendency to invade the surrounding tissues distinguish it sharply from the other form.

Both adenocarcinoma and simple **carcinoma** take their origin in the lining epithelium of the surface, or in the epithelium of the glands. They form tumors that vary much in size and consistence. They both tend to infiltrate not only the mucosa but the submucosa and deeper

tissues, the infiltration resulting in the transformation and destruction of the invaded structures. Fig. 174 *A* illustrates this point very clearly. The neoplasm has started in the mucous glands of the stomach and thence invaded the several coats, altering and destroying their structure in its progress.

All cancers (adenocarcinomata and carcinomata) of the mucous membrane ultimately break down and ulcerate, giving rise to what are called cancerous ulcers. Blood-vessels are sometimes invaded and serious hæmorrhage may thus be caused. The cancerous infiltration advances steadily, and is closely followed by the ulceration ; in this way open sores of extraordinary size are produced. For example, cancerous ulceration of the uterus sometimes leads to frightful destruction of the pelvic and abdominal organs ; the greater part of the uterus, and the walls of the bladder, vagina, and rectum may be successively attacked and destroyed. Cancer of the intestine usually proves fatal before the destruction of tissue becomes very extensive.

It sometimes happens in cases of cancer of the mucous membrane that the greater part of the neoplastic tissue is itself destroyed by ulceration. The open wound which is left granulates and cicatrizes, giving rise to marked induration and contraction of the tissues. A true cancerous ulcer, open or cicatrized, may in such a case look exactly like a simple inflammatory ulcer or induration.

Carcinoma of the mucous membrane takes various forms ; sometimes it is soft and marrowy, and is then clinically described as encephaloid or medullary cancer ; in other cases it is firm and coarsely fibrous in structure ; in other cases again it is colloid or jelly-like.

SECTION VII.
THE ALIMENTARY TRACT.

CHAPTER XLVIII.

GENERAL CONSIDERATIONS.

432. The **alimentary canal** consists essentially of an epithelial tube, which is furnished on its outer surface with certain auxiliary structures chiefly of a muscular kind. The diseases of the alimentary canal are thus for the most part diseases of mucous membrane. Their pathology is mainly a special application of the general principles considered in the last Section. In particular the causation of most of these diseases comes under the description already set forth in general terms. They are due as a rule to the presence in the alimentary canal of substances which are either noxious in themselves, or have undergone some abnormal decomposition after ingestion. It is not to be forgotten, however, that irritant matters may be conveyed to the intestinal tissues by the blood or lymph, and that morbid changes may be thus induced.

The different segments of the alimentary canal differ considerably in their structure as well as in their functions. To these differences correspond certain striking differences in the pathological phenomena they exhibit. The forms of disease to which they are subject, the course a given disease may run, and the textural changes it sets up, all differ in the different parts of the tract. In fact this single viscus furnishes us with numerous and striking illustrations of the principle—that the special form assumed by a disease depends not merely on the nature of the originating cause, but also to a great extent on the structure of the affected organ, in other words on the anatomical predisposition of the tissues that are involved.

CHAPTER XLIX.

THE MOUTH.

Inflammatory affections: stomatitis.

433. The **inflammations** of the mucous membrane of the mouth resemble in some points the inflammations of the skin, and in other points those of mucous membranes in general. Various forms are distinguished according to their intensity.

The slightest degree of inflammation is described as **erythema**. It is characterized by more or less intense redness of the surface, and either rapidly disappears or passes into the more severe form known as **catarrhal stomatitis**. In this form the surface is intensely red or livid, the secretion of the membrane is increased, and the epithelium desquamates. Over the surface of the lips, cheeks, and gums the redness and swelling are in general uniformly diffused, on the hard palate they may appear in streaks and patches. The papillæ of the tongue are most affected; some of them usually become markedly prominent, and so give the surface a rough tuberculated look.

When the inflammatory exudation is abundant, clear vesicles or blebs are sometimes formed on the tongue, lips, and cheeks, where the epithelial covering is thicker or tougher than elsewhere and prevents the free escape of the exuded liquid. But here, as in the external skin, the process of vesiculation is always accompanied by a certain amount of liquefaction of the deeper epithelial cells. As the vesicles break small ulcers covered with a whitish film of detritus may be formed in their place.

The mucous glands become swollen, giving rise to grayish or grayish-red elevations of the surface, surrounded by a reddened areola. When its excretory duct becomes obstructed with mucoid cells, the gland may be dilated into a tiny cyst by the retention of its secretion.

In recent acute catarrh of the mouth the catarrhal secretion contains comparatively few cells; in the later stages the proportion becomes increased. The cells are in part extravasated leucocytes, in part desquamated epithelial cells. If the latter remain on the surface, they may accumulate so as to form a whitish or discolored gray and brown deposit or '**fur**,' which in the case of the tongue may reach a considerable thickness. Fissures and cracks often appear on the surface of the lips and at the angles of the mouth, and these may exude liquid and become covered with crusts. They may pass by degrees into small ulcers.

Catarrhal stomatitis is generally the result of some mechanical or chemical irritation of the oral mucous membrane: when the irritation is local, like that caused by a carious tooth, the stomatitis is likewise local. But there are also many specific poisons that set up inflammation within the mouth. In measles a spotty or macular eruption appears, in scarlatina a punctate or diffuse scarlet eruption. In small-pox, chicken-pox, herpes, pemphigus, and in foot-and-mouth disease, there are eruptions of vesicles and pustules, which pass through the same stages as those of the skin (Art. 370).

Erysipelatous inflammation may extend from the skin to the mouth, or may actually begin in the mouth, causing dark or livid redness and much swelling and sometimes even vesiculation (Art. 375). The tongue is the part most affected, inasmuch as not only the mucosa but the intermuscular connective tissue become densely infiltrated with liquid and migratory cells.

Aphthous stomatitis is a peculiar form of the catarrhal inflammation. It is distinguished by the appearance on the catarrhal mucous membrane of small whitish or slightly yellowish patches (*aphthæ*) from the size of a hemp-seed to that of a split-pea. The patches are isolated or grouped, and are most abundant over the tongue and lips. They are surrounded by a livid border, and may coalesce into larger patches or streaks, though these seldom reach any great size.

These aphthæ consist of a solid fibrinous exudation lying between the fibrous tissue and the epithelium (BOHN). The exudation may be reabsorbed, and the aphthæ then disappear. More commonly however the thin epithelial covering is broken through, the fibrinous film is exposed, and gradually separated and extruded by regenerative growth of the epithelium advancing beneath it from the margin. As the epithelium is reproduced simultaneously with the separation of the fibrin, no ulcers are in general produced; sometimes however suppuration is set up in the zone surrounding the aphthæ. The eruption occurs in successive crops and may thus be kept up for weeks.

Aphthous inflammation has been compared (BOHN) with impetiginous eczema of the skin (Art. 385). It occurs chiefly in children who are teething or otherwise subject to inflammatory affections of the mouth. It also occurs in connection with sore throat (angina), and with pneumonia, gastric catarrh, the acute exanthema, diphtheria, ague, whooping-cough, etc. It is rarely met with in adults, though it has been observed in women during menstruation, in pregnancy, and during the puerperal period. The affection is entirely unconnected with any invasion of fungi (Art. 436).

On croupous and diphtheritic stomatitis see Art. 443; on corrosive stomatitis see Art. 450.

The term **aphthæ** has not always been applied to the same affection. HIPPOCRATES describes the white patches of 'thrush' (Art. 436) as aphthæ; and many

authors still use the term in this sense, while others apply it to various other affections of the mouth. Nowadays common usage is more strict, and the term is confined to the form of stomatitis spoken of in the text (BOHN). See BILLARD (*Maladies des enfants* Paris 1823), BOHN (*Die Mundkrankheiten d. Kinder* Leipzig 1866, and *Gerhardt's Handb. d. Kinderkrankheiten* IV.).

The foot-and-mouth disease of cattle is sometimes communicated to man, the infection being generally conveyed by the use of uncooked milk from diseased animals. Small vesicles with whitish turbid contents appear on the mucous membrane of the mouth; they then rupture and leave behind dark-red slowly-healing erosions. See BOLLINGER (*Ziemssen's Cyclopaedia* III.), PÜTZ (*Die Seuchen u. Herdekrankheiten* Stuttgart 1882), DEMME (*Bericht üb. d. Thätigkeit d. Kinder-spitals* Berne 1882).

434. **Ulcerative stomatitis** is an affection which always starts from the alveolar margin of the gums (BOHN). It begins with redness, swelling, and loosening of the gums around the teeth. The alveolar margin becomes rounded and swollen, with blunt processes rising up between the teeth; hæmorrhage is not uncommon at this stage.

In the second stage the margin of the swollen gum becomes discolored, and the tissue softens and breaks down into a yellowish friable mass. Ulcers are thus formed, which rapidly deepen, the surface being overspread with shreds of softened tissue. The ulcerative process may extend directly to the contiguous parts of the cheeks and lips, and may work downward till it attacks the periosteum of the bony structures, leading to necrosis and the formation of sequestra.

The affection is usually acute, seldom chronic; children are especially liable to it, but adults do not escape. It attacks persons who are badly nourished or debilitated by disease, such as scrofulous disorders, intestinal complaints accompanied by exhausting discharges, typhoid, diabetes, or scurvy. Damp, cold, and impure air seem to favor its appearance.

Local irritation or injury may also lead to it, as in cases of chronic poisoning by mercury, phosphorus, lead, and copper. All of these substances if they repeatedly gain access to the mouth may cause ulcerative inflammation. The form which is due to long-continued phosphorus-poisoning is very apt to extend deeply into the tissues, and so give rise to periostitis and necrosis of the bones of the jaws.

Noma, *cancrum oris*, or 'water canker,' is an affection allied to ulcerative stomatitis, but of a much more serious character. It may begin as an ulcerative stomatitis or appear independently (BOHN). In the former case the disintegration of the tissue of the gums extends rapidly, and the tissue breaks down into a pulpy gangrenous or putrid mass. If the affection is not preceded by ulcerative stomatitis, the first symptom is the appearance of a livid swelling on the inner surface of the cheek near the angle of the mouth, accompanied generally by a free flow of foul saliva; a patch of grayish-yellow infiltration then appears, and this speedily breaks down and becomes gangrenous. Sometimes vesicles or blebs arise on the gangrenous surface. The disease goes on to attack the

outer skin of the cheek, giving rise first to a purplish spot on which a kind of blister appears. The spot then becomes black, and gangrene sets in and spreads. As a rule the surrounding tissue is highly œdematous.

The affection is generally confined to one side. Once the gangrene has begun the destructive process advances rapidly in all directions and may reach an astonishing extent. It is nearly always fatal. In rare cases the process comes spontaneously to a standstill, and the wound heals by granulation and cicatrization, resulting in more or less grave disfigurement of the face.

Noma is most frequent between the ages of two and twelve; it is rarely met with earlier or later. It attacks weakly or debilitated children, who are exposed to unhealthy conditions of various kinds.

Suppurative inflammation of the mucous membranes of the mouth and the parts underlying should be distinguished from ulcerative stomatitis and noma. It may affect any part, but appears most commonly in the tongue and gums. In the latter it frequently arises in connection with decayed teeth. The gum becomes red and swollen and presently pus forms beneath the surface; this is called a **gum-boil** or *parulis*. Suppurative inflammation of the tongue (**glossitis**) starts from a wound or ulcer, or from some acute inflammation like that due to erysipelatous infection. According to the way in which the inflammation starts, the whole tongue or a limited part of it becomes notably swollen, and presently appears more or less extensively infiltrated with pus. When the abscess so produced is evacuated, repair is effected by cicatrization.

References on ulcerative stomatitis and noma:—BOHN, *loc. cit.*; VON BRUNS, *Handb. d. operat. Chir.* vol. i. part 2, 1859; HIRSCH, *Historisch-geograph. Pathologie* II. 1864; GIERKE, *Jahrb. f. Kinderheilk.* (new series) I.

435. The infective granulomata described in Arts. 117–135 are all of them met with in the mucous membrane of the mouth.

Syphilis gives rise to primary, secondary, and tertiary lesions. Primary sores within the mouth resemble those of the skin (Art. 391). As secondary affections we have condylomata or mucous patches (Art. 379) on the lips and on the tongue, and also thickened opaline patches covered with milky-looking epithelial deposits and described as syphilitic psoriasis of the lips, tongue, or cheek; the latter resemble the superficial corrosions caused by applying nitrate of silver to the mucous membrane. Cracks, fissures, and ulcers due to syphilitic infection are frequently observed, especially about the tongue. In the tertiary stage gummata are formed, varying in size from that of a pea to that of a hazel-nut. They especially affect the tongue and are seated partly in the mucous membrane and partly in the muscular structures. When they break down they give rise to deep and spreading ulcerations. If the ulcers heal the scars are usually coarse and puckered. LANGENBECK states that can-

cers are apt to develop from gummatous nodes and scars (*Langenbeck's Arch.* XXVI.).

Lupus often extends from neighboring part to the mucous membrane of the mouth, and causes more or less extensive destruction of tissue (Art. 392).

Tuberculosis seldom attacks the mouth, but when it does it is chiefly the tongue which is affected. Tubercles are developed in the mucous membrane; the surrounding tissues become infiltrated and presently become caseous and break down. When such a caseous patch breaks through the surface layers, a tuberculous ulcer is produced. The edges and base of the tongue are favorite seats. The floor and margins of the ulcers are hard and densely infiltrated. When the tuberculous disease seizes on the muscular substance the greater part of the tongue may become studded with tubercles and infiltrated with granulation-cells.

With regard to **leprosy** and **glanders** see Arts. 131, 133, 392.

Parasitic affections.

436. The oral cavity is always infested by a multitude of vegetable microparasites, which gain entrance to it from without and find in it a fitting soil for their growth. Moulds, yeasts, and bacteria are all met with; of the latter micrococci and sarcinæ occur as well as bacilli and spirilla. Most of these fungi have no pathological significance; they are mere saprophytes subsisting on the remains of food and the dead or desquamated epithelium which lie decomposing in the mouth. Where cleanliness is not observed they may occasionally set up putrefactive decomposition and so cause irritation and inflammation.

Pathogenous organisms, however, often gain access to the mouth as well as these non-pathogenous forms. The **tuberculous bacillus** is constantly found in the sputa in cases of tuberculous phthisis, and in this way must occasionally lodge in the tissues of the mouth. And we have already pointed out that tuberculosis of the mouth does occur (Art. 435). The **ray-fungus** or *Actinomyces* (Arts. 134–135) attacks the tongue and jaws, producing the peculiar affection called actinomycosis (Fig. 174 *B*).

By way of a correction to the account of actinomycosis given in the first volume (Arts. 134 and 135) we may here note that though ISRAEL was the first to observe and describe the ray-fungus in the human subject, it was PONFICK who first recognized the true nature of the disease, and declared it (*Berl. klin. Woch.* 1879, *Breslau ärztl. Zeitschr.* May 9, 1879) to be identical with the cattle-disease previously described by BOLLINGER. PONFICK was also the first to demonstrate the genesis of the disease by means of his inoculation-experiments.

Measles, scarlatina, erysipelas, small-pox, diphtheria, etc., all give rise to inflammatory conditions of the mouth; and as we regard these diseases as due to microparasites, we must assume that the corresponding pathogenous organisms gain access to the tissues of the mouth.

Saccharomyces albicans (REESS), *muguet*, or **thrush-fungus** is a

special parasite of the mouth ; it has hitherto generally been referred to as *Oidium albicans*. It is one of the *Blastomycetes* or yeasts, and is therefore akin to if not identical with *Mycoderma vini* or *Saccharomyces cerevisiæ* (Art. 224). As it occurs in the mouth it assumes the form of rounded or oval glistening cells and delicate filaments. Outside the body it may be cultivated in sugary or starchy liquids, and then produces round or oval cells, seldom filaments. When it grows in the mouth it gives rise to minute whitish slightly raised specks on the mucous membrane. These may be sparsely scattered or aggregated into groups on the inner surface of the lips and on the tongue. As they grow and multiply they coalesce into whitish or discolored films. After a time the film is cast off, the surface-

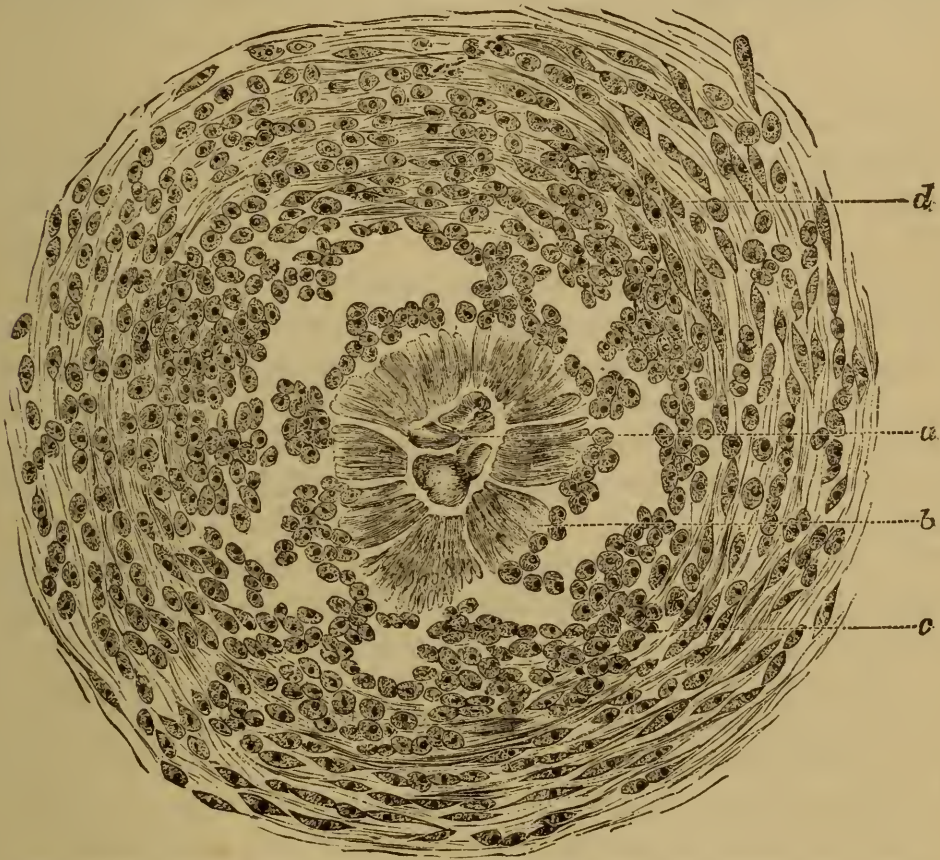

FIG. 174 B. NODULE CONTAINING *ACTINOMYCES* FROM THE TONGUE OF A COW.

(After SIMS WOODHEAD; Stained with Spiller's blue; $\times 300$.)

- | | |
|--|---|
| a, central core (? mycelium). | c, epithelioid cells in the granulomatous nodule. |
| b, radiating club-shaped bodies (? conidia). | d, formative cells and new fibrous tissue. |

beneath appearing red and sometimes eroded. The thrush-film may reappear on the same spot, and the affection may advance gradually till it reaches the pharynx and sometimes even the œsophagus.

The fungus grows mainly in the middle layers of the stratified epithelium. The upper layers are thereby raised and shed. The filaments and spores are usually thrust between the cells, though sometimes they penetrate the cell-substance and multiply within it. From the middle layers the fungus may penetrate into the deeper layers and ultimately reach the

fibrous structures. According to WAGNER and BUHL it may even penetrate the blood-vessels. As it grows downwards it sets up inflammation in the deeper tissues.

Young children are especially liable to thrush. The fungus may develop in the perfectly healthy mucous membrane of the new-born infant. Its growth is favored by the use of cows' milk and starchy foods, and by imperfect cleansing of the infant's mouth. Among adults it is nearly always in case of great weakness or wasting due to diseases like typhoid, septicæmia, phthisis, etc., that thrush makes its appearance.

References: Art. 224; REUBOLD, *Virch. Arch.* vol. 7; BURCKHARDT, *Charité-Analen* XII. (1864); GRAWITZ, *Virch. Arch.* vols. 70, 73; REESS, *Phys.-med. Gesell. zu Erlangen* 1877-78; BOHN, *loc. cit.*; E. WAGNER, *Jahrb. f. Kinderheilk.* 1868.

Hypertrophy and Atrophy.

437. The epithelium of the mouth, and especially that of the tongue, is continually being shed and continually renewed by regenerative multiplication. Whenever, as in catarrhal affections, the growth of new epithelium is increased, or the removal of the desquamated cells is impeded, whitish accumulations or deposits are formed on the surface of the mucous membrane. These deposits are often augmented by the remains of food, and by rapidly-growing fungous parasites which settle in them, and in this way a continuous film or fur is produced. This may assume the most various tints according to the food used, and if the mouth be kept open may dry up into crusts and irregular flakes separated by cracks and fissures.

Under long-continued irritation, such as is caused by the constant slight friction of the tobacco-pipe, by fungous growths, or by syphilis, the oral epithelium may pass into a morbid condition resembling cornification. White streaks and patches on the tongue and cheeks are thus produced, which have received very various names. The milky opaline patches (*plaques opalines*) of syphilis have already been referred to (Art. 435). SCHWIMMER proposes the name of **leukoplakia** for the non-syphilitic white patches which sometimes follow upon erythematous inflammation. Others speak of such patches, which are characterized by thickening, cornification, and desquamation of the epithelium, as **lingual psoriasis** or **ichthyosis**. There seems some ground for believing that leukoplakia is in certain cases at least a precursor of epithelioma of the tongue (HULKE, NELIGAN, BARKER). DESSOIR describes a certain dark discoloration of the tongue due to accumulations of spores, dead epithelium, and accidental impurities, as *langue noire* or **glossophytia**. A hyperplastic condition of the epithelium, in which hair-like epithelial processes rise from the tips of the lingual papillæ, has been described as 'hairy tongue.'

Hyperplasia of the connective tissue of the oral mucous membrane and the adjoining structures is due either to some chronic inflammatory

process, or to conditions that are congenital or developed in early infancy.

Inflammatory hyperplasia is most commonly met with in connection with the gums. It gives rise to circumscribed tumor-like thickenings, which usually retain for long the aspect and texture of granulation-tissue, and may therefore be described as granulomatous. Chronic inflammation of the tongue generally leads to fibrous induration and deformity, the muscular tissue becoming degenerate and atrophied.

Congenital and infantile hyperplasia affects chiefly the lips (**macrocheilia**) and tongue (**macroglossia**). The lips may be so thickened as to look like great unwieldy tumors: the tongue may outgrow the capacity of the mouth to hold it, and it may thus press the teeth outwards and protrude from the mouth (*prolapsus linguae*, *glossocèle*). The protruded part is usually dried up and fissured, and ulcers form at the points where it is in contact with the teeth. In the congenital form the enlargement is seldom very great at birth, but it rapidly increases in the first few months of life. The affection is frequently met with in cretins and idiots.

The enlargement of the tongue and lips is due either to an overgrowth of all the constituent tissues or of the fibrous tissue only, or to the development of neoplastic tissue. The overgrowth may be local or general: in the former case isolated nodes and tuberosities are produced.

In the fibrous form the muscular fibres are generally diminished in number; the fibrous tissue may be dense and firm or soft and cellular, and it is here and there infiltrated with leucocytes. The infiltration is most marked when the protruded portion of the tongue is fissured and ulcerated, and so subject to intercurrent inflammation. The lymphatics of the hyperplastic fibrous tissue are nearly always dilated (Art. 438).

Of the atrophies and degenerations to which the tissues of the mouth are liable those that affect the tongue are the only ones of any great importance, and of these the most striking are those that affect its muscular substance. Simple atrophy (Art. 46), fatty degeneration (Art. 50), and waxy degeneration (Art. 38) of the lingual muscles have all been described. They depend on local disorders of nutrition due to inflammatory conditions, or on neurotic disturbance in connection with disease of the hypoglossal nerve and its nucleus in the medulla oblongata.

Among the degenerative affections of the fibrous tissues amyloid change must be specially mentioned. It attacks the intermuscular fibrous tissue as well as that of the mucous membrane, and gives rise to isolated nodes or nodules, or (in the tongue) to a uniform lardaceous transformation. The muscles and mucous glands atrophy and disappear when surrounded by the amyloid substance.

Atrophy of the gums and the alveolar parts of the jaws is apt to follow upon loss of the teeth, and is especially notable in advanced age.

References on macroglossia:—Arts. 315, 438; WEBER, *Virch. Arch.* vol. 7,

Pitha u. Billroth's Handb. d. Chir. VI.; VIRCHOW, *Die krankh. Geschwülste* III.; ARNSTEIN, *Virch. Arch.* vol. 54; HUMPHRY, *Med. chir. Trans.* XXXVI. (1853); ARNOTT, *Trans. Path. Soc.* 1872; MAAS, *Arch. f. klin. Chir.* XIII.; WEGNER, *ibid.* XX.; CLARKE, *Diseases of the tongue* London 1873; VARIOT, *Journ. de l'anat. et de la physiol.* 1830; POSTER, *Jahrb. f. Kinderheilk.* XVIII. (1882); BARKER, *Holmes's Syst. of Surgery* II. London 1883.

On hyperplasia of the epithelium:—CLARKE, *Practitioner* Aug. 1874, *Brit. Med. Journ.* 1, 1874; SCHWIMMER, *Vierteljahrs. f. Derm. u. Syph.* v (1878); VOGEL, *Ziemssen's Cyclop.* VII.; KLEBS, *Arch. f. exp. Path.* v.; NEDOPIL, *Arch. f. klin. Chir.* XX.; HULKE, *Trans. Clin. Soc.* 1869; NELIGAN, *Dublin Quart. J. Med. Science* 1862; DEBOVE, *Le psoriasis buccal* Paris 1873; MAURIAC, *De la psoriasis de la langue et de la muqueuse buccale, Union méd.* 1873-74; R. WEIR, *Ichthyosis of the tongue, New York Med. Journ.* March 1875; TRÉLAT, *Bull. Soc. Chir.* 1875; *Trans. internat. med. congress* vol. III. London 1881; DESSOIR, *De la langue noire* Paris 1878; BARKER, *Holmes's Syst. of Surgery* II. 1883.

On amyloid change see ZIEGLER, *Virch. Arch.* vol. 65.

Tumors and Cysts.

438. The most important of the tumors affecting the mouth in the early years of life are the angiomata and lymphangiomata. **Angiomata** are met with chiefly about the lips, appearing as dark-red or livid slightly-raised patches. **Lymphangiomata** occur in or about the tongue. Some of the tissue-changes included under the name of macroglossia are due to lymphangiomatous growths.

In Art. 437 we mentioned that the hyperplastic fibrous tissues in the tongue and lips generally contain dilated lymphatics. Cases often occur in which such lymphatics constitute the greater part of the substance of the tongue. The entire tongue—muscles, mucous membrane, and papillæ—may be transformed into a kind of fine-meshed sponge or honey-comb. The spaces and meshes contain lymph, the septa between consist of delicate fibrous tissue interspersed with a few scattered muscular fibres. The fibrous tissue may or may not be highly cellular. In the former case it contains patches of lymphadenoid tissue; the neoplasm is then in fact a combination of lymphangioma and lymphadenoma. In other cases the tissue contains an extraordinary amount of fat, the tumor being then most fitly described as lymphangio-lipoma. The dilated lymph-spaces are usually small, but sometimes they become distended into globular cysts, from the size of a pea to that of a cherry (**cystic hygroma**).

The lymphangiomatous growth is often confined to the tongue proper, but it may extend to the neighboring parts, or new foci may appear in the tissues of the root of the tongue. It would seem that the largest cysts are met with in the latter situation. From the root of the tongue the growth may extend in various directions, occasionally passing down towards the pharynx or upwards to the palatal structures.

Of the other congenital or infantile growths within the mouth we may mention the teratomata (Arts. 13, 178).—Lipoma, fibroma, myxoma,

and sarcoma also occur; they form tumors which vary much in size and seat.

Of the tumors which develop in later life sarcoma and carcinoma are the most notable. **Sarcoma** mainly affects the gums (sarcomatous epulis), and as a rule starts in the deeper-lying structures like the periosteum or bone-marrow. It forms rounded tuberous growths, usually somewhat firm in consistence. When it starts in bone it contains bony trabeculæ in its substance (osteosarcoma, Art. 165), or sometimes giant-cells (myeloid sarcoma, Art. 159).

Carcinoma (in the form of **epithelioma**) attacks the lips, tongue, and gums. It begins as a small nodule, or a circumscribed hard grayish infiltration of the mucous membrane. Presently this becomes a palpable node projecting above the surface. The infiltrated tissue ulcerates, and around the ulcer the cancerous infiltration spreads more or less rapidly. If the diseased tissue is not removed, the cancerous ulcer may reach an astonishing size, especially in the case of the tongue and the gums. Adenoma of the mucous glands is a rarer form of tumor; it gives rise to circumscribed nodular growths.

References on lymphangioma of the mouth:—Art. 437; BILLROTH, *Beiträge z. path. Histologie* Berlin 1858; VIRCHOW, *Virch. Arch.* vol. 7; MAAS, *Arch. f. klin. Chir.* XIII.; VON WINIWARTEK, *Arch. f. klin. Chir.* XVI.; GIES, *ibid.* XV.; WEGNER, *ibid.* XX.; ARNSTEIN, *Virch. Arch.* vol. 54.

On lipoma of the tongue see WEBER (*Pitha u. Billroth's Handb. d. Chir.* VI.), GOSSELIN (*Paris médical* 20, 1881). On epithelioma see BARKER (*Holmes's Syst. of Surgery* II. London 1883).

439. As we pointed out in article 433, when the mucous glands are chronically inflamed they may become distended with accumulated secretion, and thus form small cysts of retention. Dilated lymphatics may likewise give rise to cysts, known as cystic hygromata (Art. 438). In addition to these varieties there are a number of other cystic structures, which occur in the mouth in various situations, more especially in or around the frænum of the tongue. These are referred to as cases of **ranula**, and have long been objects of considerable surgical interest. Notwithstanding this the manner in which they arise has only recently received a satisfactory explanation. VON RECKLINGHAUSEN has shown by careful anatomical investigations that the true or classical ranula is in fact a cystic dilatation of one of the main ducts of the glands of Nuhn and Blandin, two small mucous glands situated beneath the tip of the tongue. The duct is obstructed probably by inflammatory changes either within or around it, and the part behind the obstruction (which need not be complete) becomes distended with the secretion poured out by the gland-cells.

The contents of the ranula consist of a clear viscid or ropy mucous liquid, resembling the white of an egg; it may be quite colorless or stained

pale yellow or brown or pink. It contains no saliva. The cyst itself is usually globular or ovoid and lies close by the frænum.

Besides this form of ranula (the typical form), there are other cysts which are loosely classed with it. Wharton's duct, leading from the submaxillary gland, may be distended into a cyst. The cyst in this case is usually fusiform or cylindrical, though at times it becomes more distinctly globular. The occlusion of the duct is in general due to inflammation or to the formation of salivary concretions or calculi.

The ducts of the sublingual glands (ducts of Rivini and Bartholin) may also become distended into cysts lying beneath the tongue; and dermoid cysts are met with in the same situation. According to ROSER congenital cysts of the neck (Art. 8) may be displaced inwards so as to lie beneath the tongue, and sometimes simulate ranulæ. They often contain sebaceous matters.

Cysts occur in other situations, but much less frequently. Thus they are found at times in the muscular substance of the tongue and in the mucous membrane of its base. Such cysts are usually small, but now and then they attain a very considerable size (BOCHDALEK, LOTZBECK, HAMMERICH). They are due to the dilatation of the glands that occur at the base and around the root of the tongue.

The mucous glands of the lips may in like manner be transformed into cysts, which vary from the size of a pea to that of a hazel-nut.

The origin of ranula, as we have said, has been recently investigated with great care by VON RECKLINGHAUSEN (*Virch. Arch.* vol. 84). He reviews critically the various observations and theories already published, and describes the results of his own work on the subject. The classical ranula he proves to be due to the dilatation of the duct of the mucous glands at the tip of the tongue. He rejects the suggestion of FLEISCHMANN that it originates from a mucous bursa lying on the surface of the genio-glossus muscle. This bursa has been sought for in vain by various investigators; and moreover the true ranula always possesses a well-developed cylindrical epithelium.

BOCHDALEK (*Oesterr. Zeitschr. f. prak. Heilk.* XII. 1866), LOTZBECK (*Memorabilien* xv. 1870), and HAMMERICH, *Ueb. Schleimcysten d. Zungenwurzel* Würzburg 1877) have written on the cysts that are found at the base of the tongue. According to VIRCHOW, REUBOLD, BOHN (*Die Mundkrankh. d. Kinder* Leipzig 1866), DENIS, BILLARD, and others, in most infants the mucous membrane of the palate (in the neighborhood of the raphe and anteriorly) is more or less beset with white miliary nodules of various sizes. They are developed in the second half of foetal life, and are due to an accumulation of epithelial cells in the mucous glands of the hard palate. They may fairly be described as milium or comedones of the mucous membrane (Art. 404).

Changes affecting the teeth.

440. By far the most important morbid change affecting the teeth is that known as **caries**, a gradually progressive disintegration of the enamel and dentine.

First of all an opaque white spot (which may sometimes be discolored

green or black) appears on the transparent enamel. Here the prisms of the enamel are loosened and to some extent broken down. Then by degrees the dentine is attacked, and once attacked it usually disintegrates very rapidly. Decalcification of the dental tissue precedes the carious disintegration.

In the advancing margin of the diseased area the tubules of the dentine appear to be widened (KLEBS, LEBER, and ROTTENSTEIN) and surrounded by bright rings. Presently the tubules are seen to contain a granular mass, which turns blue when treated with iodine and increases in bulk at the expense of the bright rings. This mass is found to consist of micrococci and bacilli. According to KLEBS it is they that are the destroyers of the dental tissue, inasmuch as they have the power of decalcifying it. They are enabled to penetrate the substance of the teeth by the accidental formation of cracks or flaws in the enamel.

KLEBS has also shown that the mortar-like 'tartar' which often covers the teeth contains multitudes of micrococci and bacilli mingled with calcareous particles. He maintains that the organisms are able to precipitate calcium-salts from the nutrient materials they assimilate.

A very common result of caries is inflammation of the pulp or of the alveolar periosteum. The irritants which directly induce it are perhaps the bacteria which are present in the disintegrated dental substance, and set up septic decomposition around them.

The inflammation of the pulp and periosteum may pass into suppuration. In this case the surface of the gum in the neighborhood of the diseased tooth is red and swollen (**gum-boil** or *parulis*), and presently suppuration sets in and extends to the deeper tissue of the gum, forming an **alveolar abscess**. This breaks externally, and if the suppurative process around the root of the tooth continues, we may have formed an alveolar sinus or fistula.

Sometimes the inflammation extends beyond the region of the root of the tooth and gives rise to an extensive periostitis of the jaw. In this way large abscesses are sometimes formed, and necrosis of a portion of the jaw-bone may result.

References on dental caries:—KLENKE, *Die Verderbniss der Zähne* Leipzig 1850; NEUMANN, *Arch. f. klin. Chir.* VI.; LEBER and ROTTENSTEIN, *Untersuch. üb. d. Caries d. Zähne* Berlin 1867; WEDL, *Pathologie d. Zähne* Leipzig 1870; KLEBS, *Arch. f. exp. Path.* v., Article *Leptothrix buccalis* in *Realencyclop. d. gesammten Heilkunde*; COLEMAN, *Dental surgery and pathology* London 1881; Discussion, *Trans. internat. med. congress* III. London 1881.

According to MILLER (*Cent. f. d. med. Wiss.* 13, 1882, *Arch. f. exp. Path.* XVI.) the bacteria present in the mouth set up acid fermentations, and the acid produced decalcifies the dental tissues. Thereupon micrococci and bacilli penetrate the dentine and set up putrefactive decomposition in the decalcified tissue.

441. **Tumors** arising from or connected with the teeth are of two chief kinds. The one is spoken of as dental osteoma, the other as

odontoma. **Dental osteoma** or exostosis consists of a diffuse or somewhat circumscribed thickening of the *crusta petrosa* or cement; and ought indeed scarcely to be reckoned among the tumors, as it is rather of the nature of an inflammatory hyperplasia. Very few cases of true **odontoma** have been described. So far as can be made out the small tumors so named (composed of dentine and enamel) arise from the pulp of the tooth in the early stages of its growth. Odontoma cannot be developed when the tooth is mature.

Fibroma, myxoma, and sarcoma may in rare cases be developed from the pulp as the tooth is being formed. Such growths are however much more commonly derived from the periosteum of the dental follicle, the alveolar process of the jaw, the bone-marrow, or the gum itself. These tumors, which arise close to the teeth or actually from their sockets, are included under the surgical term **epulis**. Some of them start in inflammatory granulation-tissue, but most are really sarcomatous (Art. 438).

Cysts of the jaws may be produced by the morbid dilatation of the dental follicles. The cysts are seated on the alveolar ridge, and sometimes reach a very large size, some as large as an apple and larger having been described. Their contents are liquid, and occasionally rudimentary teeth are found in them (**dentigerous cysts**).

References:—VIRCHOW, *Die krankhaften Geschwülste* II. (1864-65); MAGITOT, *Mémoire sur les kystes des mâchoires* Paris 1872; USKOFF, *Odontom d. Unterkiefern*, *Virch. Arch.* vol. 85; SALTER, *Holmes's Syst. of Surgery* II. London 1883; EVE, *Brit. Med. Journ.* 1, 1883.

HUTCHINSON (*Lond. Hosp. Rep.* II., 1865; *Trans. Path. Soc.* 1858-59, and *Clinical Surgery* XI. London 1878) has pointed out that the permanent incisors, and especially the upper central incisors, of children suffering from congenital syphilis often undergo a peculiar arrest of development. They are either altogether stunted, or as they emerge from the gum their sides instead of being parallel converge, while the cutting edge is concave. After a time, the dentine being exposed, the cutting edge becomes deeply notched; and when the tooth is full-grown it appears pointed or peg-shaped, with the crescentic notch truncating its apex, so to speak. The cause of this deformity is said to be a specific alveolar stomatitis during infancy (BÄUMLER, *Ziemssen's Cyclop.* III.).

CHAPTER L.

THE THROAT.

442. The mucous membrane of the throat (including in the term the soft palate, tonsils, and pharynx) resembles that of the mouth in structure; it contains, however, a large amount of lymphadenoid tissue, which at various points is aggregated into nodules or follicles. In the tonsils especially this tissue is very abundant. According to STÖHR (*Biolog. Centralblatt* 1882) lymphoid cells are continually migrating from the lymphadenoid tissue to the free surface.

The disorders of the back of the mouth and pharynx correspond with those of the mouth generally, and many of them are indeed but partial manifestations or results of the latter. Certain forms of inflammation and certain new growths are however confined to the soft palate, tonsils, and pharynx, or at least produce in them their most characteristic symptoms.

Inflammation of the throat (referred to generally as **angina** or **pharyngitis**) may be due to local irritation, or to some general affection like measles, scarlatina, or small-pox. The catarrhal varieties give rise to redness and swelling, which may be diffused or disposed in irregular streaks and patches. The mucous membrane at the same time pours out a slimy or purulent secretion, which often forms a film or coating on the surface. In some of the inflammatory affections (such as that which accompanies small-pox or herpes labialis) vesicles are formed; these speedily rupture, and leave small erosions of the surface (*angina vesiculosa*). Often too, especially in children, the inflamed membrane is beset or overlaid with white patches of thrush (Art. 436). The lymphadenoid follicles are sometimes the parts chiefly affected. The solitary follicles of the pharynx and the serous glands at the back of the tongue swell up and project above the surface, and the tonsils are likewise enlarged (*angina tonsillaris*). If the swollen follicles break down small erosions or ulcers may be left (follicular ulceration). In chronic catarrhal conditions these changes in the follicles and tonsils may become very marked *angina* or *pharyngitis granulosa*. At the same time the mucous membrane, especially that of the uvula, becomes thickened; and the mucous glands become hypertrophied or distended, and project above the surface like small granulations. Accumulations of shed epithelium and pus-corpuscles col-

lect in the crypts of the enlarged tonsils, forming gray or yellowish plugs which occasionally become calcified. The tonsils may also become permanently enlarged as a result of chronic or often-repeated inflammation; in other cases they become atrophied or shrunken. When they are enlarged the chief seat of hyperplasia is the lymphadenoid tissue, which appears more diffused and less markedly aggregated into follicles than is normal. When they shrink it is the lymphadenoid tissue which disappears, its place being partly taken by ordinary fibrous tissue. Inflammation of the tonsils is apt to issue in the formation of small **tonsillar abscesses**, which break through the surface and evacuate their contents. The site of such an abscess is afterwards marked by a cicatrix.

443. One of the most important forms of inflammation to which the throat is liable is the **diphtheritic inflammation**, most familiarly known in connection with diphtheria.

As we have already seen (Arts. 424-426), diphtheritic inflammation of a mucous membrane is associated with the necrosis of the epithelial layers only (superficial form), or of the epithelial and fibrous layers together (parenchymatous form).

In the pharynx the process begins with the formation of small round grayish filmy patches on a red and swollen base. The grayish film is at first thin and soft, but presently it becomes thicker and more yellowish, or if hæmorrhage takes place it becomes brown or black. The patches are sometimes few and isolated, or numerous and confluent, in which case they often form large dense masses or false membranes. At first these patches or masses are closely adherent to the underlying tissue, afterwards they are loosened and can readily be removed or are cast off spontaneously. Often the underlying surface of the mucous membrane appears to be intact; it is reddened but there is no perceptible loss of substance: this is the case in superficial diphtheritis. In other cases a visible erosion or ulcer remains when the false membrane is removed: this indicates deep or parenchymatous diphtheritis. The floor of the ulcer is red or dirty gray, the latter showing that the necrotic inflammation has extended still deeper into the mucous membrane.

The seat of the diphtheritic patches varies much in different cases, as may be observed in the living patient as well as *post mortem*. Sometimes the tonsils are the parts most affected, in other cases the palate and uvula, and often enough the epiglottis and the entrance to the larynx.

In addition to the formation of these patches there is always a certain amount of œdematous swelling of the tissues, which in the case of the tonsils and the parts around the glottis frequently becomes extremely marked.

If the patient survives repair takes place by the extrusion of the false membranes, regeneration of the necrosed parts, and re-absorption of the exudation. If the necrosis has extended deeply cicatrices may be formed. Now and then the affection takes a more dangerous turn,

gangrene setting in and causing very rapid and extensive destruction of the tissues.

A certain amount of croupous exudation very often accompanies the development of the diphtheritic membranes. Some of the gray or yellowish patches may consist simply of coagulated exudation, such as characterizes simple croupous inflammation. These patches are apt to be formed at spots where the epithelium has been stripped off.

444. Pharyngeal diphtheritis may be the result of various noxious agencies. It can be produced in animals by the action of certain corrosive substances properly applied to the mucous membrane. In man it is most commonly observed in connection with various infective diseases, such as scarlatina, measles, typhoid, small-pox, and diphtheria. It is the characteristic symptom of the latter.

Diphtheria is an infective disease, met with chiefly in children. The virus enters the system usually by the mucous membrane of the pharynx, and it first of all sets up local inflammatory changes there. The changes may be simply of the nature of catarrh, or they may be more intense and more dangerous. In by far the greater number of cases the various processes of diphtheritic inflammation are induced. But in many instances the epithelium is simply shed, and circumscribed yellowish typically croupous false membranes are formed from the coagulated fibrinous exudation. Gangrene is a rarer complication. The mucous membrane of the respiratory organs—larynx, trachea, and bronchi—is usually affected at the same time as that of the throat. Where the epithelium is cylindrical the inflammation is generally of the croupous type.

It seems now highly probable that diphtheria is due to an invasion of micrococci. When the affected epithelia are examined in the early stages of the disorder, we find in and upon the inflamed spots heaps and clusters of micrococci (Fig. 170 *g* and Fig. 171 *a*) such as do not normally occur in the mouth or throat. These are regarded as the virus of the disease, and they are supposed to affect the system in general through the vessels of the pharynx.

We have not here space to describe in detail the various controversies that have arisen as to the nature of the virus of diphtheria. The most important references have been given in Art. 204. HEUBNER recently investigated the subject of scarlatinal diphtheritis (*Jahrbuch der Kinderheilk.* new series XIV.) and compared it with the diphtherial affection. He regarded the pathological processes in the two cases to be different, as judged both by the naked-eye appearances and by the character of the histological changes. ZIEGLER is however quite unable to agree with him in this point: the poison of scarlatina may induce in the fauces exactly the same histological changes as those which are characteristic of diphtheria. In a still more recent and very suggestive paper (*Die experimentelle Diphtherie* Leipzig 1883) HEUBNER seems to have now arrived at a like conclusion. He indeed affirms that localized diphtheritic inflammation of a mucous membrane may be set up without micrococci, and then the inoculation of any kind of micrococci may suffice to induce the general disease.

445. **Phlegmonous inflammations** and abscesses are more common in the fauces and tonsils than in the mouth itself. They begin with intense redness and swelling of the affected parts. The exudations and pus collect in the loose meshes of the submucosa, giving rise to abscesses of various sizes, which at length break through the mucous membrane. The commonest causes of such suppurative inflammations are mechanical injury followed by some septic infection, and glanders, syphilis, anthrax, etc. Retropharyngeal abscesses are occasionally due to caries of the cervical vertebræ. Abscesses about the throat are dangerous inasmuch as they may lead to the erosion and rupture of blood-vessels, or may directly or indirectly involve the entrance to the larynx. This last accident is generally brought about by the induction of œdema in the mucosa or submucosa of the glottis, which often accompanies the formation of an abscess in the neighboring parts.

In rare cases phlegmonous inflammation may issue in gangrene. Dark and discolored patches are formed, which rapidly extend and disintegrate. Gangrene is most commonly observed in connection with small-pox, typhoid, dysentery, and diphtheria.

446. The **syphilitic affections** of the throat resemble those of the mouth. Simple catarrhal inflammation, the formation of granulomatous foci or gummata, ulceration, and scarring, are all met with. Scarring may give rise to very considerable distortion and deformity of the parts.

Tubercle and tuberculous ulceration occur chiefly in the larynx. The surrounding tissues are sometimes markedly œdematous. The tonsils are not infrequently attacked by tuberculosis.

Lupus is most apt to affect the soft palate; it is rare in other parts, such as the larynx. The infiltrated tissue breaks down and large unsightly ulcers are produced. Lupus of the face generally accompanies the affection of the mucous membrane.

Papillary growths and mucous polypi sometimes occur around the uvula and the border of the soft palate; but they are not very common. Cysts of retention, of small size, now and then arise from dilatation of the mucous glands.

Tumors are rare in the region of the throat, but both connective-tissue and epithelial growths are occasionally met with.

CHAPTER LI.

THE SALIVARY GLANDS.

447. The salivary glands are racemose glands whose secretion is discharged into the oral cavity. The chief disorders to which they are liable are those due to inflammations, and to the growth of tumors.

Mumps or epidemic parotitis is an infective inflammatory swelling of the parotid gland. The submaxillary and sublingual glands may be affected at the same time. The glands and the overlying tissues are much enlarged, and feel doughy to the touch.

Similar swellings occur as secondary symptoms in connection with certain infective disorders like typhoid, cholera, pyæmia, syphilis, diphtheria, etc.

The swelling is due to inflammatory serous and cellular infiltration of the interalveolar fibrous tissue of the glands. It issues either in resolution, or in fibroid induration, or in suppuration and abscess. Sometimes gangrene supervenes.

Angina Ludovici is an acute phlegmonous inflammation of the tissue surrounding the submaxillary gland, resulting often in suppuration or gangrene.

Milder forms of inflammation are also met with in connection with disorder of the salivary glands, resulting from mechanical injury or retention of their secretion or from other causes not easy to determine. When chronic they lead to fibrous hyperplasia, while the gland-substance often becomes atrophied. If the duct becomes involved in a contracting cicatrix it may be obstructed or altogether occluded.

448. A **salivary fistula** is an opening or channel connecting a salivary duct with the surface of the mucous membrane or the skin. It results either from a wound, or from some suppurative inflammation leading to perforation.

When a salivary duct is obstructed or occluded the smaller ducts behind the obstruction become dilated by the retained secretion. These dilated ducts are either cylindrical or sausage-shaped, or fusiform, or even pear-shaped. As the accumulation goes on the ducts and the lumen of the gland become distended into globular cysts, often of very considerable size.

The cysts produced by dilatation of the submaxillary and sublingual ducts protrude from beneath the tongue, and are often spoken of as

ranulæ, like those which arise from dilatation of the mucous glands of the tip of the tongue (Art. 439).

Salivary calculi are stony concretions which form occasionally in Stenson's and Wharton's ducts. They consist of calcium phosphate and carbonate. Sometimes they enclose foreign matters which have accidentally gained access to the ducts. According to KLEBS they also contain fungi, and these he regards as the active factors in bringing about the precipitation of the calcium salts.

Tumors both of the connective-tissue and the epithelial types are met with in the salivary glands. Of the former class fibroma, sarcoma, enchondroma, and myxoma, may be mentioned. They usually give rise to definite nodes or nodules, and sometimes include cystic cavities (cystic sarcoma). Carcinoma usually begins as an isolated nodule, which extends so as to involve the whole gland, and then invades the surrounding tissues. Ulceration and gangrene now and then supervene. These neoplasms are very apt to exhibit a mixed type of structure, especially those of the parotid gland. Thus cartilaginous, mucoid, sarcomatous, and fibroid elements may all occur within the same tumor. Sometimes the peculiar hyaline formations characteristic of cylindroma (Art. 163) are met with. Combinations of carcinoma with sarcoma or enchondroma are not uncommon.

CHAPTER LII.

THE ŒSOPHAGUS.

449. The most important of the deformities to which the œsophagus is liable is **stenosis** or narrowing of its calibre. Five varieties of stenosis have been distinguished (ZENKER, VON ZIEMSEN) according as it is due to congenital malformation, compression, obstruction, stricture, or spasmodic contraction.

The œsophagus is wholly absent only in fœtuses which are very gravely malformed. Even a partial obliteration is rare when the fœtus is at all well-developed.

Simple **congenital** stenosis occurs both at the upper and at the lower end of the tube and may be simply annular or may extend over some small distance. Both varieties are rare.

Stenosis by **compression** is generally due to the pressure of enlarged scrofulous glands in the neck or mediastinum, mediastinal sarcoma, aortic aneurysm, etc. It produces grave functional difficulty only when the tube is in a manner encircled by the growth, so that there is no direction in which it can yield.

Stenosis by **obstruction** occurs when foreign bodies become wedged in the tube. The thrush-fungus may grow and multiply in the œsophagus to such an extent as occasionally to block up or seriously to narrow the passage. Polypous tumors growing from the mucous membrane may have a like effect, but very rarely. Cancerous growths are much more apt to be the cause of obstruction.

Strictures are due to the contraction of cicatrices or to cancerous change. Cicatrices most commonly follow upon injuries due to irritant or corrosive substances, such as boiling water, acids, or alkalies. The extent and tightness of the stricture depend on the size of the corrosion-wounds. If the corrosion has extended deeply into the tissues of the wall, the œsophagus may be transformed into a firm almost cartilaginous pipe, through which only the finest sound may be able to pass. Syphilitic strictures are very rare, as the œsophagus is on the whole seldom attacked by syphilitic inflammation. Cancerous strictures are due to the infiltration of the whole circumference of the œsophagus by the neoplasm, by which it is transformed into a kind of tough unyielding tube, the infiltrated tissue often at the same time undergoing contraction. These strictures are usually found in the lower or middle third of

the œsophagus, rarely in the upper third; they extend over a length of 5 to 10 centimetres. The inner surface is in general ulcerated.

Spasmodic or spastic stenosis is due to a painful contraction of the muscular coats. It is transient but apt to recur, especially in hysterical patients. As a rule no appreciable anatomical lesion of the œsophagus can be made out *post mortem*; though sometimes inflammation or ulceration of the mucous membrane exists and may induce abnormal irritability and spasm.

The channel may, on the other hand, be abnormally wide, either from dilatation or from the presence of diverticula.

Simple **dilatation** is generally the result of stenosis of the lower part of the tube or of the cardiac orifice of the stomach. In this case the muscular walls yield and become distended as the ingested food gathers above the contracted portion. The dilatation is generally uniform, but occasionally it is unilateral and in this way diverticula are sometimes produced. The various coats are often thickened in the dilated portion.

But dilatation may take place without stenosis; and in this case the œsophagus assumes the form of a fusiform sac, the walls of which (and especially the muscular and epithelial coats) are more or less thickened. The apparent cause of the dilatation is a diminution of the contractile power of the walls, due to injuries of various kinds or to inflammatory change. Localized dilatations above the diaphragm occur as congenital malformations (ZENKER).

Diverticula occur as localized sacculations at some part of the wall of the pharynx or œsophagus. They are due to pressure from within, or traction from without.

Diverticula of the former class are rare. They occur at the lower end of the pharynx, and appear either as small sacculations of the size of a hazel-nut or less and directed posteriorly, or as large globular, cylindrical, or pyriform sacs hanging down between the tube and the spine. The walls of such a sac are moderately thick and consist of the mucosa and submucosa with an external adventitious layer of fibrous tissue; the muscular coat is absent or persists only around the neck of the sac. The diverticulum is in fact a hernia (pharyngocele) of the mucous membrane through the muscular bundles of the inferior constrictor of the pharynx. ZENKER accounts for its existence by supposing that some localized weakening of the posterior wall of the pharynx takes place, and that then the inner layers are pushed through the outer by pressure from within exerted in the act of swallowing. The weakening may be due to mechanical injury, such as that caused by the lodgment of a foreign body. As food sometimes lodges in a diverticulum and remains there decomposing for a time, it may act as an irritant to the mucous membrane and give rise to inflammatory thickening of the wall, or occasionally to mucous papillary growths from its inner surface.

Diverticula due to traction occur on the anterior aspect of the œsophagus, and most commonly at the level of the bifurcation of the trachea. They are usually narrow and funnel-shaped, varying in depth from 2 to 17 mm., the apex pointing directly forwards or a little to one side. Simple shallow bulgings are more rare. The funnel consists of mucosa and submucosa, which may be wholly or partially or not at all covered with a muscular layer. The apex almost invariably runs out into a band of dense fibrous tissue, generally containing a shrunken bronchial gland and connected with the trachea or one of the bronchi. The diverticulum thus appears to be ultimately due to an inflammatory process starting in some lymphatic gland and involving the wall of the œsophagus: the contraction of the inflammatory or cicatricial tissue gives rise to the traction upon the œsophagus-wall. The diverticulum has no tendency to enlarge, but it may be perforated by a foreign body which becomes wedged in it.

Rupture of the healthy œsophagus is rare, if we leave out of account the cases in which it is directly wounded from without. There are however some instances on record in which strangulation or violent vomiting have led to longitudinal or transverse rents of the wall. It may be that in the latter cases the tissues were to some extent softened by the action of the regurgitated gastric juice. This digestive softening is not uncommon as a post-mortem phenomenon: the affected tissue appears gray or yellow and sodden, and is readily torn. According to ZENKER it may occur *in articulo mortis*; but the instances must be very rare in which it occurs in a healthy patient.

Perfora ion of the œsophagus is due to disease in the tube itself or in the adjoining parts. Cancerous ulceration and the lodgment of foreign bodies are the commonest causes of the former; corrosion by various liquids and simple ulceration come next in point of frequency. Perforation from without may be due to suppurating lymphatic glands, abscesses, gangrene of a goitrous tumor, or aneurysm of the transverse or descending aorta. Perforation is always followed by more or less extensive inflammation. This is least marked when the tissue around the ruptured spot is already thickened by chronic inflammation. When there is no such thickening, widespread purulent or gangrenous inflammation may be set up in the neighboring parts.

ZENKER and VON ZIEMSEN (*Ziemssen's Cyclopædia* VIII.) give a very minute and accurate account (with full references to the literature) of the morbid changes to which the œsophagus is liable. The above account is based upon theirs.

450. **Catarrhal inflammation** of the œsophagus is marked chiefly by epithelial desquamation; but little mucus is poured out in the chronic forms, and in the acute forms it is absent. The desquamated cells give the mucous surface a dull whitish or yellowish tint. Sometimes minute superficial ulcerations occur. When the inflammation is caused

by the presence of a foreign body, a deep ulcer is often formed at the spot where it is in contact with the wall.

In chronic catarrh the mucous membrane may become hypertrophied, and papillary or polypous outgrowths are apt to arise from its surface: the muscular coat may also show signs of hypertrophy. If the mucous glands become obstructed they give rise to granular prominences which are liable to break down and leave minute ulcers. Varicose veins are not infrequently met with in the œsophagus in elderly patients. They lie in the submucosa, and give rise to small livid prominences of the mucous membrane. When these become eroded minute ulcers exactly resembling the ulcers of chronic catarrh are formed, and are described as varicose ulcers. Serious hæmorrhage sometimes occurs when a varicose vein gives way.

Croupous and diphtheritic inflammations are rare. They occur most frequently in connection with typhoid, cholera, measles, scarlatina, small-pox, pulmonary tuberculosis, and pyæmia: they very seldom indeed accompany ordinary diphtheria. Sometimes in the course of small-pox regular variolous pustules appear in the œsophagus.

Phlegmonous inflammation occurs either localized or diffused over a considerable area: it is however an extremely rare affection. If the collection of pus which forms in the submucous tissue breaks through the surface, complete repair and recovery may ensue. When the phlegmonous abscess is larger, undermining a considerable portion of the mucous layer and breaking through it at several points, some part of the cavity of the abscess may persist unhealed after its evacuation: it becomes gradually covered over with epithelium growing in from the sites of perforation. This variety of inflammation is due to wounds or corrosions, or to the extension upwards of a phlegmonous inflammation of the stomach, or to purulent inflammation extending inwards from the surrounding tissues.

Corrosive substances like sulphuric, nitric, hydrochloric, or carbonic acids, caustic potash or soda, blue vitriol, etc., give rise to more or less wide-spread destruction of the œsophageal tissues. If the acids are dilute the epithelium alone may be destroyed, becoming white and turbid and falling away from the mucosa. If the corrosive action goes further, the mucous membrane in its whole thickness is transformed into a gray or brown or black slough traversed by blackened blood-vessels, and sometimes the muscular coat is destroyed likewise. If the patient survives violent inflammation results, which is usually suppurative and now and then leads to perforation. When however the suppuration causes the necrosed tissue to separate, the wound may become scarred over; if the muscular coat has been destroyed the scar invariably contracts and gives rise to extreme constriction of the tube.

Patients who are much emaciated and bedridden sometimes suffer from gangrenous ulceration of the pharynx. Gray or black sloughs form

on the anterior and posterior wall at the level of the cricoid cartilage, which are presently cast off leaving ulcers behind them. The affection is due to the continuous compression of the tube between the larynx and the spine, the extreme relaxation of the muscles permitting the larynx to sink down on the yielding pharynx. It is therefore of the nature of a bed-sore or **decubital necrosis** (Art. 33).

Syphilitic inflammation and ulceration of the oesophagus are extremely rare.

451. **Connective-tissue growths** are not common in this region, though fibroma, lipoma, myxoma, and sarcoma are sometimes met with. As a rule they form globular polypous-looking tumors. This is especially true of fibroma, which occasionally develops in the lower part of the pharynx behind the larynx and hangs pendulous within the tube.

Papillary outgrowths from the mucous membrane are more common; they somewhat resemble warts in general structure.

Carcinoma is however by far the most important of the neoplasms affecting the oesophagus. It may appear at any point of the tube, though it is most frequently met with in the lower third. It gives rise to isolated or annular infiltrations, which speedily break down into ulcers. Sometimes the protuberant parts of the growth are entirely removed by ulceration, while the base and margins of the sore continue to be infiltrated with cancer-tissue. The disease extends in the first instance to the muscular coat, and then to the adjacent tissues and organs. The connective tissue surrounding the oesophagus becomes indurated and beset with nests of cancer-cells; then the trachea, bronchi, pericardium, heart, pleura, lungs, etc., may be successively invaded. Perforation may result from the ulceration, and then ulcerative disintegration spreads rapidly through the previously infiltrated organs. The neighboring parts are always more or less inflamed. Primary cancer of the oesophagus is a squamous epithelial carcinoma (Art. 173).

With regard to **thrush** see Arts. 436 and 449.

CHAPTER LIII.

THE STOMACH.

452. **Introductory.** With the **stomach** begins the portion of the alimentary tract whose special function is the digestion and absorption of the ingested food. In accordance with this function we find the mucous membrane of the stomach furnished with numerous blood-vessels and lymphatics, a very thin epithelial covering, and an extraordinary number of glands yielding the juices necessary for digestion.

The ingesta linger in the stomach for a considerable time; part is directly absorbed by the gastric mucous membrane, part is altered by the gastric digestion, and part passes on unaltered.

It is easy to understand that—owing to the length of time during which the ingesta remain in the stomach, and the intimate nature of the relations between them and the mucous membrane—the latter is very liable to be injuriously affected by any noxious substance which may be swallowed. Thus the acids and alkalies which give rise to swelling and corrosion in the mouth, throat, and œsophagus (Art. 450) will in general act still more destructively on the walls of the stomach. And other substances (like phosphorus, salicylic acid, etc.), which may pass through the upper parts of the tract without doing any harm, will be able in the stomach, where they lie for an appreciable time, to set up local or general inflammatory mischief. An excessive meal of ordinary food may have the latter effect, and of course substances in themselves noxious or irritating will act more intensely. And although the stomach has the power of as it were protecting itself by the secretion of a thick coating of inert mucus, still this power has its limits and often enough is inadequate.

The gastric mucous membrane is likewise exposed to danger from the side of the circulation. Apart from local or general disturbances of the blood-supply leading to anæmic necrosis and hæmorrhage, to abnormal secretion, or to œdema, we may have noxious matters conveyed by the blood to the membrane, and setting up in it degenerative changes of various kinds. Thus cloudy swelling and fatty degeneration (Arts. 48, 50) of the gland-cells are met with in connection with many infective and toxic affections, such as small-pox, typhoid, septicæmia, and phosphorus-poisoning. Often the degeneration is so marked as to give rise to obvious macroscopic change, the mucous surface taking on a turbid grayish or yellowish tint. The stomach suffers also in connection with other

general diseases. Thus in cases of generalized amyloid disease the fibrous structures of the gastric blood-vessels are often affected by amyloid degeneration.

453. Morbid changes in the walls of the stomach involve more or less grave disturbance of its digestive functions. This disturbance again may set up others, and these may give rise to further morbid changes of a secondary kind.

The gastric secretion in health is such as to induce in the ingested food certain definite chemical changes. If the secretion is from any cause deficient or morbidly altered, the ingesta may undergo abnormal decompositions. These are very often of the nature of fermentations set up by fungi of various kinds. These fungi or their germs are swallowed with the food; but in health they do not develop or multiply within the stomach, the gastric secretion being unfavorable to their growth. When however this property of the secretion is altered or inactive, the fungi are free to flourish.

Over-distention of the stomach and stagnation of its contents favor the growth of fungi in it. Permanent dilatation may be induced by too frequent or too abundant meals; but it is more commonly due to some obstruction or to atony of the muscular coat. These again may depend on very various causes. In the first place the free passage onwards of the food may be interfered with by such causes as habitual stooping, tight-lacing, the pressure of abdominal tumors, etc. The same effect is produced, but in a much higher degree, by textural changes in the stomach itself—especially by stenosis of the pylorus, inflammatory infiltration and induration of the walls, gastric ulcers and cancers, adhesions to contiguous organs, degeneration and other affections of the muscular coat, etc. And when from any cause the digestive function is disordered, the onward movement of the food may be hindered by the pyloric sphincter refusing to relax, the usual stimulus of the normally-digested chyme being absent (BRÜCKE, *Physiologie* I.).

When any of these conditions give rise to considerable accumulation of undigested food in the stomach, the fungi grow and multiply, sometimes to an enormous extent. Micrococci, microbacteria, bacilli of the most various forms, sarcinæ, yeast-fungi, all flourish luxuriantly. In the contents of an atonic and chronically dilated stomach we may often find specimens of almost every type of these organisms. Sometimes we may also meet with spores of filamentous fungi or moulds, such as *Mucor*.

In consequence of the growth of these fungi fermentations of various kinds are set up. The chief of these are the lactic, butyric, acetic, alcoholic, and certain varieties of septic or putrefactive fermentations.

These abnormal fermentations naturally react injuriously on the stomach and on its power of secretion. They keep up an abiding irritation of its mucous membrane, and often seriously hinder the repair of

the original lesion, which may be in itself but slight and transient. In some cases the bacteria attack the mucous membrane directly. Thus according to VON RECKLINGHAUSEN (*Virch. Arch.* vol. 30) and VON WAHL (*Virch. Arch.* vol. 41) certain kinds may penetrate the glands and the underlying tissue, and give rise to pustule-like nodules protruding above the surface. In the case of a man who died after two days' illness with choleraic symptoms, the author found the stomach beset with small whitish patches of necrosis and minute ulcers with whitish floors; and on examination these were seen to contain multitudes of bacilli. Mould-fungi and yeast-fungi are unable to penetrate the mucous membrane.

When the contents of the stomach are highly acid while the circulation within its walls is somehow weakened, the walls may become softened or macerated, or in a certain sense digested. According to the amount of blood it contains the mucous membrane is transformed into a brown or black pulpy or jelly-like friable mass. This 'softening of the stomach' (**gastromalacia**) is generally met with in cases of brain disease, especially in tuberculous meningitis where it may set in during the last hours of life. LEUBE is of opinion that it may occur in persons previously in good health, but his instances are by no means conclusive.

Gastromalacia is in the great majority of cases a post-mortem phenomenon. After death the mucous membrane of the stomach alters very quickly, especially when it contains an excess of gastric juice or of acid products of decomposition.

The first alteration consists in solution of the blood-corpuscles and diffusion of their coloring-matter through the tissues. If sulphuretted hydrogen is evolved from the contents of the stomach, the red coloring-matter is changed to greenish-black. Brown pigmentations, such as occur in cases of chronic gastritis, take on a gray or black tint.

Self-digestion very frequently follows. The mucous membrane and then the muscular and serous coats are transformed into a soft friable mass, white or gray or black in color. When the stomach is lifted out its contents sometimes break through the softened tissue and escape. Occasionally the walls are thus macerated over their entire extent; and when the fundus has been lying in contact with the diaphragm, the process may extend to the latter and so break it down that the contents of the stomach escape into the thorax. The most marked instances of self-digestion of the stomach occur in young children, whose stomachs contain a large quantity of undigested milk; and the characteristic appearances are more frequently seen in hot weather than in cold.

References on mechanical dilatation and fermentation within the stomach:—KUSSMAUL, *Deut. Arch. f. klin. Med.* VI.; JÜRGENSEN, *ibid.* VII.; PENZOLDT, *Die Magenerweiterung* Erlangen 1875 (with full references); LEUBE, *Ziemssen's Cyclop.* VII., *Deut. Arch. f. klin. Med.* XXIII.; NAUNYN, *ibid.* XXXI.; POENSGEN, *Die motor. Verrichtungen d. menschlichen Magens* Strasburg 1882; BUDD, *Organic diseases of the stomach* London 1855; FENWICK, *The stomach and duodenum* London 1868; EWALD, *Die Lehre von d. Verdauung* Berlin 1879; ROSENBAACH, *Samml. klin. Vorträge* no. 153.

On gastromalacia see ELSASSER, *Die Magenerweichung der Säuglinge* Stuttgart 1846; LEUBE, *Ziemssen's Cyclop.* VII.; KUNDRAT and WIEDERHÖFER, *Ger-*

hardt's Handb. d. Kinderkrankh. IV.; THORSPECKEN, *Deut. Arch. f. klin. Med.* XXIII.; W. MAYER, *Gastromalacia ante mortem, ibid.* IX., In. Diss. Leipzig 1871.

454. Congenital anomalies. The stomach is occasionally absent in acephalic monsters. More rarely it is found to be abnormally small, in fœtuses which are otherwise well-developed. Complete atresia of the pylorus is very rare, but stenosis or abnormal contraction is more frequent (R. MAIER).

Of congenital anomalies of form we may mention abnormal constrictions of the body of the stomach, giving it an hour-glass shape; and the occurrence of partitions abnormally subdividing it.

In cases of *Situs transversus* or lateral transposition of the viscera (Art. 11), in persistent fissure of the abdomen and thorax (Art. 9), and in congenital deficiency of the diaphragm, the stomach is as a rule misplaced. Sometimes the vertical position of fœtal life persists in the adult.

Acquired anomalies of form and position are more common. Dilatation may be due to congenital or acquired stenosis of the pylorus. But it may occur independently of pyloric obstruction, as a result of abnormal position or adhesions, of distention from excess of ingesta, or from textural changes in the walls (Art. 453).

In extreme dilatation the stomach occupies a large extent of the abdominal cavity, extending backwards rather than forwards. It may reach from the left side of the diaphragm to the symphysis pubis, compressing the bladder and covering over almost the whole of the intestinal convolutions. The left half of the lesser curvature runs parallel to the spine, in continuation of the line of the œsophagus: the pyloric half bends up at a sharp angle towards the liver. The greater curvature lies along the left side of the abdomen, the pylorus being dragged downwards and backwards and the hepatico-duodenal ligament stretched. The coats of the stomach may be thinned in every part or, according to the cause of the dilatation, may be thickened at various spots, especially in the neighborhood of the pyloric end.

Acquired contraction or constriction of the stomach is due either to functional inactivity of the organ as in prolonged starvation, or to inflammatory or ulcerative disease leading to cicatricial contraction. Peritonitis, followed by adhesions and contraction of the serous membrane (*peritonitis deformans*), may give rise to shrinking or other deformity of the stomach. Partial alterations of form are due to local disease. Ulcers (chiefly along the lesser curvature) which heal and become cicatrized lead to retractions and constrictions, which may be so extreme as to give the stomach the form of an hour-glass, or to bring the cardiac and pyloric ends into contact. New growths in the stomach-wall may have like effects. Gastric diverticula are very rare.

Displacements of the stomach as a whole may be caused either by changes in the surrounding parts or by disorders of the organ itself.

References:—PENZOLDT, *Die Magenerweiterung* Erlangen 1875; LANDERER, *Die angeborene Stenose des Pylorus* Tübingen 1879; DEMME, *Die Magenerweiterung beim Kinde, Jahresbericht d. Kinderspitals* Berne 1882.

455. **Hypertrophy** of the muscular coat is observed in like conditions to those which are associated with dilatation, namely in cases of pyloric obstruction. It is rarely met with unaccompanied by such obvious anatomical lesions as explain its development; when these are absent we are driven to refer it to functional disturbance of some kind (NAUWERCK, *Deutsches Archiv f. klin. Med.* XXI.). The hypertrophy is most marked near the pylorus, less so about the fundus; it may be very considerable.

Notable thickening of the walls of the stomach may follow upon chronic inflammation (Art. 456), and is common in carcinomatous disease (Art. 461). In both cases the thickening is mainly due to fibrous hyperplasia, though the mucous and serous coats and at times the muscular coat partake in the change: cases are however not rare in which the muscular coat is decidedly hypertrophied. The fibrous thickening which accompanies carcinomatous disease is often very great.

Gastric polypi are papillary outgrowths from the mucous membrane of an inflammatory kind (Art. 456). They vary from the size of a pea to that of a hazel-nut or more, and very frequently enclose small cyst-like cavities. No new glands are formed in them, although by the overgrowth of the interglandular tissue single glands here and there may seem enlarged. Such inflammatory polypi are to be distinguished from the villous or papillomatous neoplastic growths or true tumors which may occur in the stomach.

Atrophy of the coats is met with in conditions of general cachexia, and in cases of dilatation. Fatty degeneration of the muscular fibres takes place, and according to R. MAIER colloid degeneration also occurs. When the fibrous elements become hyperplastic the muscle-cells may be compressed and undergo atrophy, while the glandular structures also dwindle and degenerate (Art. 456).

456. **Inflammation of the stomach or gastritis.** In recent acute catarrh (acute gastritis) the mucous membrane of the stomach appears dark-red and swollen, and beset with small hæmorrhagic patches. The surface is covered with a film consisting of mucus, mucoid epithelium, and extravasated leucocytes. The cylindrical epithelial cells of the gland-ducts, which in normal conditions manufacture large quantities of mucus from their protoplasm, are seen to have passed into an extreme stage of mucoid change, and many are in process of desquamation. The epithelial cells of the peptic glands lie loosely in the lumen, and seem more granular than usual. The vessels of the interglandular connective tissue are distended, and their course is marked by cellular infiltration of the tissue, especially along the small veins. The subglandular tissue, and in some cases the submucosa, are here and there infiltrated; the endothelium of the lymphatics is swollen and desquamating, and some

of the cells are multinuclear. These signs of inflammation may appear over the whole extent of the mucous membrane, or may be confined to a few patches; very often the pyloric end alone is affected. Acute catarrhal gastritis is in most cases a transient affection, resulting in resolution and recovery; but it may pass into the chronic form and so lead to permanent changes.

Thus the infiltration and the epithelial desquamation may become extreme; part of the epithelium is thus permanently lost, and as the desquamation extends the glandular structures gradually perish. In other words, atrophy of the mucous membrane takes place. In rare cases this is accompanied by disintegration of the fibrous sub-structures. Where the infiltration has been greatest, perhaps where hæmorrhagic extravasation has occurred, both epithelium and fibrous tissue perish, and are cast off in larger or smaller fragments (see Art. 421). In this way more or less extensive **ulceration** is set up, and may spread over a large part of the mucous membrane.

The individual ulcers are of various sizes. The floor is usually irregular and beset with low ridges or with small warty elevations; they may be pale or red, and are sometimes indurated. The margins pass gradually into the thinned and atrophied membrane around, or are sharply defined and marked by the presence of excrescences in the form of small polypi or raised borders. Whenever the ulcer is large enough to be easily visible, the glandular structures of the mucosa are found to be almost wholly destroyed. The muscularis mucosæ usually persists, but is thickly beset with infiltrated cells. The submucosa is thickened, indurated, and infiltrated, its fibrous elements being hyperplastic and abnormally coarse in texture. The glandular structures, where they remain, are infiltrated with leucocytes; the infiltration being most marked in the neighborhood of the thickenings and polypous excrescences. Some of the glands undergo cystic degeneration. The lymphadenoid follicles are fuller of lymphoid cells than in normal conditions, and are somewhat enlarged.

Ulcers of this extent are rare as a consequence of simple inflammation. Like the round or perforating gastric ulcer (Art. 459) they may give rise to serious hæmorrhage.

A more common result is pigmentary change in the mucous membrane, with glandular atrophy and fibrous hyperplasia (**atrophic pigmentary induration**). The pigmentation is usually gray, and is due to the presence of minute black granules derived from small extravasations of blood. The atrophy appears in the thinning of the mucous membrane, which may be marked enough to be visible by the unaided eye; in slighter cases it can be demonstrated under the microscope.

When the fibrous hyperplasia is on the whole but slight, it seems to be confined to the interglandular connective tissue (Fig. 175 a). In more advanced cases the mucous membrane is increased in its entire

thickness, and rises in folds (*d*) and warty or polypous excrescences. The surface thus becomes rough and corrugated, and the condition is known as the *état mamelonné*, or *polyposis ventriculi* (Art. 422).

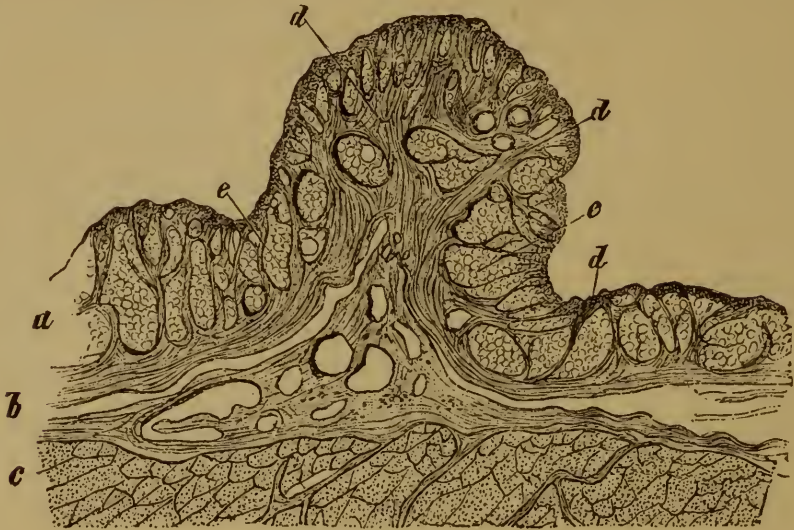


FIG. 175. FIBROID FOLD (*ÉTAT MAMELONNÉ*) IN THE GASTRIC MUCOUS MEMBRANE.

(*Hæmatoxylin staining*. $\times 10$.)

a, mucosa, with atrophied glands.
b, submucosa.
c, muscular coat.

d, hyperplastic fibrous tissue of the mucosa.
e, gastric glands.

The hyperplastic fibrous tissue (*d*) may be dense and coarse-fibred, or soft and cellular. Some of the glands lose their epithelium and disappear, others take the form of cysts.

These cysts, which vary in size from that of a small pea to that of a bean, contain a clear viscid liquid mingled with granular detritus and sometimes transparent spherules of colloid substance. The epithelium of the cysts is cylindrical (Fig. 176 *c*), and many of the cells have the appearance of typical goblet-cells. The larger cysts are occasionally beset with papillary ingrowths from their walls (Fig. 176 *c*).

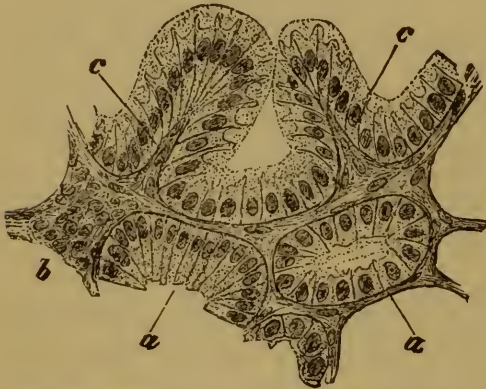


FIG. 176. SECTION THROUGH A GASTRIC POLY-
PUS.

(*Hæmatoxylin staining*: $\times 300$.)

a, tubular gland with cylindrical epithelium.
b, fibrous stroma infiltrated with leucocytes.
c, papillary growths into the lumen of a glandular cyst.

In all forms of chronic inflammation, but especially in the ulcerative forms, the overgrowth of fibrous tissue may extend to the submucous,

muscular, and even to the serous coats.

The wall of the stomach is thus thickened and indurated, while the muscular fibres are more or less compressed and atrophied. In other instances, however, the muscular coat becomes hypertrophied.

457. **Phlegmonous inflammation** of the stomach is rare; it may be general or circumscribed, the latter being the commoner form. The seat of the inflammation is essentially the submucosa (compare Arts. 390, 427).

In the circumscribed form, more or less extensive **abscesses** may be formed and break into the cavity of the stomach. In the diffuse form the submucosa is at first greatly swollen and thickened, while the mucosa is unaffected or occasionally somewhat swollen. The exudation in the submucosa is sero-purulent, and the mucosa is infiltrated with round-cells. Sometimes the infiltration extends to the muscular coat, passing chiefly along the intermuscular septa. In this way the serous coat may come to be affected in like manner. Both muscular and serous coats then become swollen, and the serous surface may be covered with purulent or fibrino-purulent deposits.

After a time the submucous tissue appears to break up and dissolve, and the exuded pus breaks at various points through the mucosa. The latter becomes in some cases almost riddled such perforations. The muscular coat may likewise suppurate. If the patient survive, the smaller openings may cicatrize over and so heal, but the larger frequently remain as cavities extending into the submucosa and ultimately become covered internally with a stratum of epithelial cells; such cavities may communicate with the cavity of the stomach by one or more openings through the mucosa.

Croupous and diphtheritic inflammations of the gastric mucous membrane are rare. They are generally met with in connection with diphtheritic pharyngitis in cases of scarlatina or small-pox, and in infants who die of septic inflammation of the umbilicus.

The croupous exudation takes the form of more or less extensive grayish-yellow false membranes; but these very rarely extend over any large part of the gastric surface. In diphtheritic inflammation the necrotic membrane may consist only of the superficial epithelial cells (and then appears as a small grayish patch); or it may include the whole thickness of the mucosa, which is then transformed into a gray or black slough. Ulcerations due to small-pox, tuberculosis, typhoid, or syphilis, are very rarely met with in the stomach.

Corrosion of the stomach by caustic poisons is comparatively common. It is always associated with like changes in other parts of the alimentary canal above and below the stomach. In the latter case the changes may extend to the ileo-cæcal valve, owing to the fact that the small intestine is much more easily affected by such poisons, even when much diluted, than the stomach.

All corrosive poisons, whether acids or alkalies, when concentrated give rise to sloughing and separation of the superficial layers of the mucous membrane (A. LESSER). The sloughs or eschars caused by sulphuric acid are grayish-white or ashy-gray, dry and coarse in appearance, and

brittle. In extreme cases the entire surface may be transformed into a charred-looking blackened mass. When recent the several elements of the tissue are still recognizable in the slough, though they are turbid and shrunken. The sloughs due to hydrochloric acid are similar. Nitric acid produces a yellow or orange slough. The color of the less affected parts is pale purple or grayish. Oxalic acid gives rise to slight and superficial sloughs, which are white or grayish in color. A concentrated solution of caustic potash acts like sulphuric acid, but the sloughs are less brittle. Parts that have been for some time in contact with the alkali become semi-transparent. Corrosive sublimate, carbolic acid, and arsenious acid, give rise to white sloughs.

The mineral acids and alkalies are the most powerfully corrosive. Not only may all the coats of the stomach be destroyed by their action, but the neighboring organs may be similarly corroded and discolored. The liver and spleen are especially liable to be attacked, and then look almost as if they had been boiled.

In the parts surrounding the sloughs, and in other places where the poison has been somewhat diluted, a more or less intense hæmorrhagic inflammation is set up. The parts thus affected presently take on a brownish, greenish, or grayish-black tint, and are traversed by blackened vessels; the slough at the same time softens or breaks down, and this more readily in the case of acids than of alkalies. By and by the dead tissue is cast off and liquefies.

The most intense inflammation is that set up by the strong mineral acids; oxalic acid, corrosive sublimate, carbolic acid, and arsenious acid, are much less active in this respect.

If the patient does not straightway die, the corrosion-wounds may heal by cicatrization. Where the corrosion has been extensive, very great contraction and deformity of the stomach and intestine may result.

References on corrosion of the alimentary tract:—CASPAR and LIMAN, *Handb. d. gerichtlichen Medicin* Berlin 1881; BÖHM, *Ziemssen's Cyclop.* XVII.; BIRCH-HIRSCHFELD, *Lehrb. d. path. Anat.* 1877; VIRCHOW, *Charité-Annalen* VI., 1881; A. LESSER, *Virch. Arch.* vol. 83; FILEHNE, *ibid.* vol. 83; TAYLOR, *Medical Jurisprudence* London 1883.

458. The gastric mucous membrane is very liable to **hæmorrhage**. Hæmorrhage may be caused by traumatic injury through the swallowing of solid bodies or corrosive poisons, by inflammatory changes in the blood-vessels, by ulceration, by venous engorgement such as accompanies portal obstruction in various hepatic disorders, scurvy, yellow fever, acute yellow atrophy of the liver, typhoid, etc.; in fact by local lesions and by general infective disease, by constitutional disorder and by changes in the composition of the blood as a whole. In rare cases hæmorrhage may be due to primary alterations, such as atheroma and aneurysm, in the large vessels of the stomach and the neighboring organs.

The effused blood, which may be small or large in quantity, becomes rapidly brown or black as the gastric acids transform its hæmoglobin into hæmatin.

When the bleeding is due to the erosion or rupture of a small blood-vessel, the fact can in general be easily verified on opening the stomach. When the bleeding is 'capillary' or parenchymatous the tissue is infiltrated with blood and red, brown, or black in color. Such infiltrated tissue is of course more or less completely deprived of circulating blood, and is consequently exposed to the digestive action of the gastric juice. It is therefore attacked and in part dissolved, and in this way an ulcer or 'hæmorrhagic erosion' is produced.

Hæmorrhagic erosions of the stomach heal in the same way as those of other mucous membranes, unless some special obstacle stands in the way. If the loss of substance is at all considerable a reactive inflammation is set up, in consequence of which the surrounding parts become infiltrated with cells. Granulation-tissue and a cicatrix are produced, and presently become clothed with epithelium. The same process takes place in the healing of other lesions unaccompanied by notable hæmorrhages, such as those caused by traumatic injury, corrosive poisons, etc.

The result is different in certain conditions unfavorable for repair, as when the gastric acids are present in excessive quantity, or when the circulation in the parts around the erosion is interfered with for any reason, local or general (*e.g.* anæmia). In such cases the circulation in the floor and margins of the erosion may be insufficient to protect the parts from digestion. The exposed strata of the tissue are dissolved one after another, and an ever-enlarging ulcer is produced, the so-called *ulcus ex digestionem* (Art. 459). When thrombosis occurs in the vessels exposed by an erosion such an ulcer is very apt to be produced.

Melæna neonatorum is a peculiar form of hæmorrhage from engorgement. It is a gastro-enterorrhagia, or bleeding from stomach and intestine simultaneously, which appears in the first week or two of life, most commonly in the first to the third day. It occurs in strong healthy infants as well as in those who are born semi-asphyxiated; and is probably due to some disorder or defect of the circulation after birth, such as often leads to temporary engorgement or congestion. If the mucous membrane be thus at any point infiltrated with blood, an ulcer may afterwards be readily formed. The stomach and duodenum are the commonest seats. According to LANDAU the arteries of the stomach and intestine are liable to embolism from fragments of thrombi forming in the umbilical vein and ductus arteriosus; and the embolism may give rise to hæmorrhagic infarction, hæmorrhage, and ulceration. See BUHL (*Klinik f. Geburtskunde* 1864), SPIEGELBERG (*Jahrb. f. Kinderheilk.* II. (new series) 1869), LANDAU (*Ueber Melæna d. Neugebor.* Breslau 1874), REHN (*Centralzeitung f. Kinderh.* I.); WIEDERHÖFER *Gerhardt's Handb. f. Kin. erkr.* IV.).

459. **Round or perforating gastric ulcer** (*ulcus rotundum, ulcus perforans, ulcus simplex, or ulcus ex digestionem*). 'Round' ulcer occurs in the stomach or duodenum, and very rarely in the lower part of the

oesophagus. As we have said in Art. 458, it is due to the digestive action of the gastric juice, and takes the form of a circumscribed progressive necrosis with solution of the necrosed tissue.

A typical perforating ulcer measures from one to six centimetres across, and in form resembles a flat funnel or saucer, inasmuch as the loss of substance in the mucosa or surface layer is greater than that in the other layers. Where the submucosa rests on the muscular coat a slight ledge or terrace can generally be made out. In ulcers that are not recent these relations often disappear, the loss of substance in the deeper layers (muscular and serous) becoming as great as in the more superficial ones. Such ulcers may be as much as eight to twelve centimetres in diameter.

When the ulcer extends through all the coats, as it not infrequently does, the adjacent organs, like the pancreas and liver, are usually found to be bound to the stomach by firm adhesions and so come at length to constitute the floor of the ulcer. In such cases the cavity may become flask-shaped, the hole in the stomach-wall leading into a larger excavation in or bounded by the underlying viscera.

The margins of the ulcer are usually smooth, and not thickened; at most they are slightly swollen. On microscopic examination it appears that no appreciable amount of cellular infiltration precedes or accompanies the disintegration of the tissue. The inflammatory processes which give rise to the adhesions between the stomach and the adjacent organs, and to the thickening of the serous coat, are secondary to the progressive destruction by the gastric juice.

Any kind of injury which causes a localized textural lesion of the mucous surface of the stomach, and so expose it to the unchecked action of the gastric juice, may be the originating cause of a gastric ulcer. Probably the commonest of such causes are venous engorgement, hæmorrhage, and arterial anæmia (ischæmia) due to embolism, spasmodic contraction, or sclerosis. In other cases mechanical injury, or corrosion by caustic substances, may afford a starting-point. AUFRECHT has succeeded in producing typical gastric ulcers in rabbits by injecting cantharidin under the skin (*Cent. f. d. med. Wiss.* 31, 1882). He regards these ulcers as depending primarily on an intense hæmorrhagic inflammation of single gastric glands (gastradenitis).

Gastric ulcer runs a chronic course, but the first stages of its development are often somewhat rapid. After severe burns of the skin, for example, ulcers of the stomach and duodenum are sometimes very rapidly induced, probably in consequence of some vascular obstruction or thrombosis due to disintegrated blood-corpuscles (Art. 262). Round ulcers are most frequently met with in the neighborhood of the lesser curvature, then near the pylorus, and least frequently in the duodenum.

Dangers in gastric ulcer. When an ulcer has once formed it may heal up, provided it is not too large. For this it is necessary that a good

circulation should be established in the structures of the floor and margins; the tissue thus becomes alkalized and fortified against the action of the gastric juice, and the formation of granulations and cicatricial tissue becomes possible.

Small ulcers may heal without leaving any marked scar. Ulcers of any size give rise to dense puckered scars, which by their **contraction** may cause considerable deformity of the stomach. An ulcer near the pylorus may lead to dangerous stricture of the orifice.

One great danger in gastric ulcer arises from the risk of **hæmorrhage** from small or large arteries, which become eroded in the course of the ulcerative process. The hæmorrhage may recur again and again and lead to extreme anæmia, or a single great hæmorrhage may bring about death directly. On post-mortem examination it is not rare to find in the floor of the ulcer the eroded vessels, either patent or closed by thrombi, from which the bleeding has taken place. Occasionally one of the larger vessels, such as a main branch of the coronary or splenic artery, is found to have given way.

A still greater danger is that of **perforation** into the peritoneal cavity. This may happen whether adhesions have been set up between the stomach and neighboring organs, or not. In the former case the adhesions are torn asunder and the contents of the stomach escape. Fatal peritonitis is the usual result.

The organs which adhere to the floor of the ulcer, such as the pancreas or liver, usually exhibit fibrous thickening and hyperplasia at the surface of adhesion. Notwithstanding this the contents of the stomach may break through into the substance of the organs, and give rise to abscesses in their parenchyma. Sometimes adhesions occur between the stomach and the duodenum or transverse colon. When perforation takes place in such a case a fistulous communication may be opened between the intestine and the stomach. In like manner rupture into the pleural or pericardial sac may occur, and in the latter case may lead to erosion and perforation of the heart-wall itself (BRENNER, *Wien. med. Woch.* 48, 1881).

References on simple gastric ulcer (*ulcus rotundum*):—VIRCHOW, *Virch. Arch.* vol. 5; KLEBS, *Handb. d. path. Anat.* I.; BUDD, *Organic diseases of the stomach* London 1855; BRINTON, *Ulcer of the stomach* London 1857, *Diseases of the stomach* London 1864; FENWICK, *The stomach and duodenum* London 1868; VON ZIEMSEN, *Sammlung klin. Vorträge* no. 15; GERHARDT, *Wiener med. Presse* 1867; GÜNSBURG, *Arch. f. physiol. Heilk.* XI.; KEY, *Hygeia* 1870; WILSON FOX, *The diseases of the stomach* London 1872, with reference to English papers; PANUM, *Virch. Arch.* vol. 25; COHNHEIM, *Allg. Path.* II. Berlin 1882; KÖRTE, *Zur Lehre vom rund. Magengeschwür* In. Diss. Strasburg 1875; LEUBE, *Deut. Arch. f. klin. Med.* XVIII., *Ziemssen's Cyclop.* VII., with references; L. MÜLLER, *Das corrosive Geschwür des Magens* Erlangen 1880, with full references; BÖTTCHER, *Dorpat. med. Zeitschr.* 1874; HAUSER, *Das chronische Magengeschwür* Leipzig 1883; WIKTOROWSKY, *Virch. Arch.* vol. 94. QUINCKE and DÄTTWYLER (*Mittheil. d. Vereins Schleswig-Holsteinscher Aerzte* 1880, *Deut. med. Woch.* 6, 1882) have produced gastric ulcers

in dogs by various methods, and find that in normal conditions repair is very rapid; whereas in anæmic or debilitated animals it is delayed. This observation entirely accords with clinical experience. Lesions of the gastric mucous membrane usually heal readily and rapidly; it is only when some local or constitutional condition impedes the process of repair that progressive digestion or solution of the injured tissue is set up, and the gastric ulcer assumes its typically chronic and intractable character.

461. Tumors of the Stomach. Carcinoma is by far the commonest and most important of the new growths affecting the stomach.

All cancers start in the mucosa, but very quickly extend to the submucosa (Art. 431); in this way it is frequently found that the main mass of the growth lies beneath the mucosa in the submucous stratum. Thence the disease invades the muscular and serous coats (Art. 431, Fig. 174 *A*). In the latter it usually spreads in the form of discrete nodules and nodes, which are perceptible from without, and follow the course of the lymphatic vessels. At a later stage it may invade the veins, giving rise to carcinomatous thromboses, which take the form of long flat elevations of the serous surface, lying chiefly about the pyloric end of the stomach.

The lymphatic glands situated behind the lesser curvature soon become enlarged, and are often transformed into huge cancerous nodes. The disease may likewise extend to the omentum and give rise to a general thickening of its tissue or to irregular tuberous growths. In other cases metastases occur in the peritoneum generally, and in the liver, lungs, etc. The liver is the commonest seat of the metastatic growths, the germinal elements being conveyed by the portal vein.

Gastric carcinoma most frequently takes the form of soft fungous tumors arising from the pyloric end and along the lesser curvature; tumors arising from the fundus and general or diffuse cancerous infiltration are more rare. When the tumor projecting into the cavity of the stomach has attained a certain size, its central parts usually break down and a carcinomatous ulcer is produced. Such an ulcer is distinguished by its raised rampart-like borders. Its floor is generally formed by the submucosa, which is thickened by fibrous hyperplasia or cancerous infiltration. The former is a result of chronic irritative inflammation.

The fibrous tissue of the muscular and serous coats is often the seat of extensive hyperplasia, causing the whole of the affected region of the stomach to appear thickened and indurated. A very similar appearance may be due simply to cancerous infiltration.

Occasionally the neoplastic tissue within the cavity of the stomach becomes entirely disintegrated, so that the surface of the ulcer appears smooth and level. When in such a case the stomach-wall is not visibly beset with nests and clusters of cancer-cells, but is simply indurated in consequence of fibrous hyperplasia, the affected region may wear the look of a simple non-malignant or fibroid induration. Cases occur in which no cell-nests are to be made out even when the tissue is micro-

scopically examined: and then the only evidence forthcoming as to the cancerous nature of the disease may be the metastatic growths to which it has given rise.

462. Five chief forms of gastric cancer are distinguished according to their histological structure.

(1) **Medullary carcinoma** (Art. 173) takes the form of soft fungous excrescences or low rounded swellings, chiefly about the pyloric end of the stomach. As the central parts break down these growths give place to ulcers with raised borders, white and pulpy in appearance. The new growth starts in the gastric glands. Structurally it is distinguished by the presence of an extraordinary number of cell-nests or loculi, while the stroma is but slightly developed. Beneath the ulcer the wall of the stomach is nearly always indurated or infiltrated. This form produces numerous metastases.

(2) **Destructive adenoma** (adenocarcinoma, Art. 169) also gives rise to soft nodular growths, which presently break down and ulcerate. The neoplasm is distinguished by the presence of tubular gland-like structures, which often possess a simple cylindrical epithelium (Fig. 174 A, Art. 431), and thus closely resemble normal glands; hence the term adenoma. This close resemblance is however generally lost as the disease advances, and large cell-nests arise from the tubular structures, which are merely covered over with cylindrical epithelium, the interior consisting mainly of polymorphous cancer-cells. The stroma is not abundant, and is often infiltrated with small leucocytes. As the growth ulcerates its base almost always become indurated and thickened by fibrous hyperplasia or cancerous infiltration.

(3) **Scirrhus cancer** appears in the form of diffuse thickening and induration of the stomach-wall, especially the pyloric part of it. The pylorus itself is usually more or less constricted. The inner surface of the diseased region is covered partly with thickened mucous membrane, partly with the exposed and indurated fibrous tissue belonging to the submucosa. On section the various coats are distinguishable, but each is more or less thickened by fibrous hyperplasia. The author is of opinion that so-called scirrhus is often nothing but induration of the stomach-wall, partly cancerous and partly fibroid, left as a secondary result of the ulcerative disintegration of a soft cancer (Art. 173).

(4) **Colloid or gelatinous cancer** takes the form both of nodular swellings and of diffuse and wide-spread infiltration of the stomach-wall. In each form the neoplasm contains patches of transparent jelly-like appearance, or consists almost entirely of colloid substance. The growth often spreads to the peritoneum, and there speedily gives rise to large semi-transparent colloid growths, which are more or less richly supplied with blood-vessels. On microscopic examination it appears that the colloid masses are partly derived from the cancer-cells, partly from the fibrous stroma of the growth (Art. 173, Figs. 69 and 70). Colloid can-

cer may appear in very young patients, while the other forms are almost entirely confined to persons in the decline of life.

(5) **Squamous epithelial cancer** is rarely met with in the stomach. It affects the cardiac end and the neighboring parts of the œsophagus.

The **connective-tissue growths** of the stomach have very little pathological interest. A few cases of nodular sarcoma, fibroma, and myoma, have been recorded.

CHAPTER LIV.

THE INTESTINE.

463. **Introductory.** The intestinal part of the alimentary canal is that within which especially the assimilable parts of the food are absorbed, and so reach the lymphatics and blood-vessels. The intestine (according to some authorities) contains no new or specifically distinct variety of secreting glands, and its mucous membrane yields no specific secretions. On the other hand its absorbing surface is greatly increased by being thrown into a multitude of villi and valvular folds and tube-like crypts or pits.

The **epithelium** consists throughout of a single layer of cylindrical cells, the blood-vessels and lymphatics extending up to the lower surface of the epithelium.

The loose-textured connective tissue of the mucosa and submucosa expands at many points into a still looser reticulum, which contains lymphoid cells in abundance and so constitutes lymphadenoid tissue. This is aggregated into single nodules, the so-called **solitary glands** or follicles, or groups of these are agminated to form **Peyer's patches**.

It is scarcely needful to point out that it is from the mucous surface that the intestine is most exposed to injury. Matters constantly pass into it from the stomach which react harmfully on its tissues, and the mucous membrane is the first part to be attacked. The normal contents, if they stagnate and so become altered in their physical or chemical characters, may give rise to various morbid conditions. In other cases we must assume that specifically noxious matters enter the canal from the mouth, and that these may be the cause of certain intestinal disorders. Many such disorders are probably due to specific bacteria, and in some of them these have been actually demonstrated.

As regards the affections of the intestine which are traceable to the circulation, we need only remark that the intestinal mucous membrane like others is liable to œdema and hæmorrhage in the mucosa and submucosa, to fatty and mucoid degeneration of its epithelium, and to amyloid degeneration of its connective tissue.

There are however disorders of the intestine other than those connected with the mucous membrane, and affecting the viscus as a whole. The intestine forms a freely movable tube lying in the abdominal cavity; it is therefore subject to misplacements and displacements of the

whole (or of its parts in relation to each other) which may give rise to serious disturbances of its function and may even imperil the integrity of its structure. Disease or injury may also affect the intestine from its serous or peritoneal surface.

464. **Congenital defects and misplacements.** Absence of the whole or of a large portion of the intestine is met with only in very ill-developed acardiac monsters. Minor deficiencies, constrictions, and occlusions, are somewhat commoner. The anal region is that which is oftenest imperfectly developed. The allantoid cloaca may persist, that is to say the intestine and the bladder open into a common chamber or orifice. In such cases the bladder is frequently unclosed and the lower bowel absent, so that the ileum communicates directly with the cloaca. In less-marked cases there is merely an imperfect separation of the rectum from the urogenital sinus, into which latter the genital and urinary canals open in the foetus. The anus itself, which is developed from an invagination of the external skin, is wanting, and the condition is described as *atresia ani* or **imperforate anus**: and according as the lower end of the bowel is connected with the bladder, the urethra, or the vagina, the atresia is distinguished as vesical, urethral, or vaginal. When the rectum is completely separate from the urogenital sinus, although not in communication with the anal invagination, we have simple *atresia ani*: the rectum is usually ill-developed.

The formation of abnormal septa in the continuity of the intestine is much more rare than atresia of its anal extremity.

Abnormal shortness or length of the canal is on the other hand a much commoner anomaly.

As common perhaps is the existence of what is called **Meckel's diverticulum** (Art. 9). This is a cylindrical or flask-shaped appendage, attached to the ileum about a metre or more above the ileo-cæcal valve; it is a remnant of the omphalo-mesenteric duct. In rare cases it is connected by a cord with the umbilicus, and in still rarer cases it opens on the exterior just below the umbilicus. Its structure is the same as that of the small intestine.

When the abdominal wall is congenitally fissured or sacculated, coils of intestine may lodge in the openings so produced. A piece of intestine lodged in a sacculatation of the peritoneum is spoken of as a **hernia** (Art. 465), and a coil or other portion which escapes to the exterior through an opening is called a **prolapse**.

But apart from these protrusions the intestine is very frequently misplaced, especially when some segment of it is abnormally short or long. Owing to its normally fixed position displacements of the colon are the most easily recognized. The cæcum, for instance, varies much in position; it may lie either below or above the line joining the anterior superior spines of the ilia. The level of the hepatic and splenic flexures differs much in different persons. The length of the sigmoid flexure

and of the transverse colon is very variable. In some cases the latter may be absent altogether, the ascending and descending portions lying side by side on the right of the abdomen.

Enterocystomata (ROTH, *Virch. Arch.* vol. 86) are structures allied to the congenital diverticula of the intestine. They are closed sacs filled with liquid, and exhibiting the same structure as the walls of the bowel. Two forms may be distinguished—(1) cysts due to the sacculation and abstriction of portions of an otherwise normally developed intestine: (2) cysts due to some abnormality of development in the foetus. These latter may in reality be portions of the intestine of a rudimentary twin and therefore teratoid in character, or depend on the closure and separation of an anomalous diverticulum such as Meckel's. They may increase greatly in size from accumulated secretion, and then become displaced from their original site.

465. **Acquired deformities and displacements.** Abdominal hernia or 'rupture' in the stricter sense implies the escape from the abdominal cavity of some part of its normal contents either to the exterior or into some other cavity of the body.

In **external hernia** some viscus which is covered with peritoneum escapes outwards through a normal opening which has become abnormally dilated, pushing before it the subperitoneal structures and the skin. The protruded layer of the parietal peritoneum forms the **hernial sac**. It can be absent only when the peritoneum has been torn or when the displaced viscus is extraperitoneal (such as part of the bladder or cæcum) and protrudes directly through some opening in the fascia or muscles of the abdominal wall. The other tissues which are forced outwards with the hernia are spoken of as the **accessory coverings** of the hernial sac. The inner layer or covering consists of the subperitoneal cellular tissue, which is usually thickened and toughened (peritoneal fascia). In femoral and inguinal hernia the true fascia (fascia propria) comes next, and is continuous with the fibrous structures bounding the orifice in the abdominal wall through which the hernia has escaped. At first the hernial sac is simply globular or saucer-shaped; when fully developed it is in general flask-shaped. The narrower part of the sac where it is gripped by the structures of the orifice is called its **neck**. The peritoneum is drawn into radial folds as it passes towards the neck of the sac.

The **contents of a hernia** are very various. Most commonly they consist of a part of the omentum or small intestine, less commonly the cæcum or colon, and still less commonly other viscera such as the ovaries, bladder, stomach, liver, etc. Very large ruptures, such as occur in the inguinal region, may include the greater part of the contents of the abdomen, more especially the bowels. When a portion only of the intestinal wall or Meckel's diverticulum is included we have a case of what is called **Littré's hernia** (LITTRÉ, *Mémoires de l'acad. royale* 1700).

In a large number of hernias the sac is already formed before the viscera escape. Thus inguinal hernia may occur by the passage of the intestine into the persistent vaginal process of the peritoneum which is continuous with the tunica vaginalis of the testicle. This is usually the case in what is called infantile or congenital hernia.

Hernia may also arise in consequence of some external stretching force by which the peritoneum is dragged outwards. Thus a lipoma growing in the septum crurale, and pressing outwards as it increases in size, may drag upon and sacculate the peritoneum which is firmly attached to the septum. Something of the same kind takes place in umbilical hernia.

Lastly, some local diminution of the resistance of the abdominal wall, or the giving way of muscles or fasciæ and the relaxation of the peritoneum, may cause the latter to become sacculated under the pressure of the respiration.

The following varieties of external hernia may be distinguished.

(1) **Inguinal hernia.** This takes place in the groin, and is due either to the congenital patency of the vaginal process of the peritoneum after the descent of the testicle, or to a secondary protrusion of the peritoneum in the inguinal canal. In **oblique** or external inguinal hernia the neck of the sac passes down the canal from the internal to the external ring; in **direct** or internal inguinal hernia the peritoneum is pushed from within directly through the external ring. In oblique hernia the orifice of the sac lies to the outer side of the internal epigastric artery, in direct hernia the orifice lies to the inner side of the artery. Inguinal hernia may reach a large size and contain the greater part of the bowels. It is the commonest of all varieties, especially in men.

(2) **Femoral or crural hernia.** This is due to the protrusion of the peritoneum beneath Poupert's ligament through the opening closed by the septum crurale and traversed by the great femoral vessels. It is a common variety, especially in women.

(3) **Obturator hernia.** In this the sac passes with the obturator nerve and artery through the obturator or thyroid foramen of the innominate bone.

(4) **Ischiatic hernia.** Here the protrusion is through the ischiatic notch beneath the glutæus maximus: it is rare.

(5) **Perineal hernia.** Here the sac escapes between the anterior fibres of the levator ani: it is also rare.

(6) **Umbilical hernia.** This is either congenital, consisting of a protrusion through the unclosed umbilical ring into the root of the cord (Art. 9), or acquired, and is then due to the separation of the fibres of the linea alba at the umbilicus and dilatation of the orifice so formed. It may contain intestine or omentum only. The acquired form is most commonly met with in women who have borne children.

(7) **Ventral hernia.** This is due to the general relaxation or stretching of the fibrous structures of the front of the abdominal wall, so that the peritoneum protrudes between the muscles which are thrust asunder.

466. When a hernia is once established, further changes in the parts usually follow. The hernia may increase in size by the inclusion of more of the abdominal contents. The sac stretches and becomes thinner, or

new portions of the peritoneum are dragged into it. In consequence of the slight mechanical lesions to which the hernia is exposed a certain amount of inflammation is usually set up. The sac thereby thickens and the folds of peritoneum at the neck cohere so that the channel of communication between the sac and the abdominal cavity becomes thick-walled and inextensible. The serous covering of the included intestine, and its mesentery, and of the omentum, become thickened in like manner. Lastly, adhesions may be set up between different parts of the sac, or between different loops of intestine and the sac-wall. The omentum is very apt to adhere to the sac.

These changes very rarely indeed lead to cure by the closure and obliteration of the empty sac; on the contrary they usually make matters worse. The thickening and adhesions of the serous surfaces diminish by degrees the mobility of the included viscera. The neck of the sac becomes narrower, constricting its contents more and more. At length the contents can no longer be returned to the abdomen; the reducible hernia has become irreducible. When the contents of a hernia (reducible or not) are so constricted or compressed that the included intestine becomes impervious and its circulation seriously impaired, the hernia is said to be strangulated or incarcerated.

Strangulation or **incarceration** may be due to simple narrowing of the neck of the sac or of the orifice through which it passes; or it may arise from inflammatory constriction of the intestine within the sac; or a loop of intestine within the sac may slip between two edges or bands of false membrane or into a gap in an included piece of omentum; or a piece of omentum may be squeezed into the neck of the sac and so compress the intestine; and so on.

A narrow orifice, a band of false membrane, etc., may strangulate a loop of intestine without any abnormal distention of the latter by its contents. This may happen suddenly, for example, when the intestine is forced through a narrow orifice by an unusually deep respiration. This is sometimes referred to as 'elastic' strangulation. More often however the strangulation is dependent on some increase of the intestinal contents, the orifice of the sac being narrow; this may be called 'fæcal' strangulation. The fæces accumulating in one coil of the intestine within the sac compress the other included coils in such a way as to nip them; stoppage or stasis of the contents takes place and the peristaltic movements are interfered with (KOCHER). Presently the first coil is nipped in like manner, as the distended intestine presses up against the narrow neck of the sac.

When a coil of intestine or a part of the omentum is constricted and strangulated, disturbances of the circulation almost always take place. The venous efflux is impeded, and engorgement, transudation, and hæmorrhage result. The coil becomes purple and swollen, and liquid gathers in the sac; and these factors conspire to intensify the strangulation.

If nothing is done the intestine sooner or later becomes gangrenous, and violent inflammation of the hernial sac ensues. The intestine becomes discolored, turning brown or bluish-black; at the point of strangulation it is paler and somewhat grayish. Presently perforation takes place, and at the boundary between the living tissue and the dead, that is at the inner border of the strangulating constriction, definitive suppuration is set up.

467. Incarceration of the intestine, with obstruction and stasis of the fæces, may occur within the abdomen as well as in an external hernia. This has been called internal strangulation or **intestinal obstruction**.

In the first place it must be remembered that within the peritoneal cavity there are pouches or recesses of peritoneum not visible outwardly, which are either normal or dependent on congenital anomalies. In these pouches coils of intestine may become incarcerated as in external hernias, and they are sometimes spoken of as cases of **internal hernia**. Among such pouches we may mention the lesser or omental sac of the peritoneum bounded by the stomach, pancreas, liver, and spleen, and communicating with the greater sac through the foramen of Winslow; the duodeno-jejunal fossa, between the upper part of the mesentery and the spine; the subcæcal fossa, on the mesial side of the cæcum; and the intersigmoid fossa, beneath the mesocolon of the sigmoid flexure. Coils of intestine may slip into and be incarcerated in any of these pouches. The duodeno-jejunal fossa may indeed enclose the whole of the small intestine (retroperitoneal hernia).

In rare instances sacculations of the diaphragm may contain coils of intestine, giving rise to **diaphragmatic hernia**. Cases are more common in which abdominal viscera escape into the thorax through actual rents in the diaphragm (THOMA, *Virch. Arch.* vol. 88).

Sometimes in consequence of plastic inflammation false membranes and adhesions are formed within the abdomen, and if these enclose gaps or pouches, internal incarceration may occur. If the opening through which the coil of intestine slips is narrow, or if the coil is nipped, stasis and all the other symptoms of strangulation may be produced. The like may happen when the omentum or the mesentery contains abnormal perforations or gaps.

Another cause of intestinal obstruction is twisting of the bowel on itself, or **volvulus**. It can occur only in the more movable parts of the tract, and is due partly to peristaltic movements, especially when the tube is very unequally distended, and partly to external violence, such as a blow on the abdomen. The twist occurs at the mesenteric attachment, the two limbs of the coil crossing each other over the mesentery. The channel of the intestine is occluded and the mesenteric circulation stopped. Untwisting is prevented by the weight of the distended coil and the pressure of the rest of the abdominal contents.

Twisting of the sigmoid flexure or of the small intestine may result

in a kind of knotting between the two, the attached end of the twisted coil of one part becoming encircled by a loop of the other.

468. **Stenosis** and **atresia** are not infrequently the result of inflammation of the wall of the intestine itself. The serous coat may become inflamed, and so indurated, cicatrized, and contracted; or ulcerative inflammation of the mucous membrane may result in the formation of new fibrous tissue, which subsequently contracts. Carcinomatous ulcers, the floors of which tend to become indurated and contracted (Art. 478), may have the same effect; while tumors and other growths developing within the canal or pressing on it from without may obstruct and ultimately occlude it.

Dilatation of the intestine is most commonly due to retention of fæces, or other contents such as flatus. Tumors, and abnormal relaxation or softness of the wall, may also give rise to dilatation.

Usually all the coats are dilated together; sometimes, however, the muscular structures are here and there pushed aside, and the mucous and submucous coats bulge through, producing sacculations or **false diverticula** of various sizes. Sacculations may also be due to the bulging of the wall in its whole thickness.

Perforation of the bowel is in general due to some localized textural change, especially to ulceration of the mucous surface, necrosis, or softening occasioned by suppuration in the neighborhood of the part. Perforation may of course be caused by mechanical violence.

The result of perforation, unless the lips of the wound immediately close, is local or general peritonitis due to the escape of fæces. The peritonitis is localized when by previous inflammation adhesions have been set up around the point of perforation. If fæces escape into the portion of the peritoneum so circumscribed a fæcal abscess is produced; this may break either outwardly or into another part of the intestine.

469. A not uncommon kind of displacement or dislocation of the intestine is that known as **intussusception**. In this a higher part of the bowel slips into or is invaginated by a lower, rarely the reverse. Recent intussusceptions are most frequently met with in the small intestine in young children, especially in those who have died of cerebral or intestinal affections.

The extent of the invagination varies much. Where the intestine is very loose and movable a very considerable length of it may be involved. Thus, for example, the lower portion of the ileum with the cæcum may be thrust into the colon, and work downwards until the ileo-cæcal valve reaches the sigmoid flexure or even the rectum.

The mesentery being severely dragged upon and its vessels compressed, the invaginated portion of the bowel becomes highly hyperæmic and œdematous. Presently inflammation is set up, and this may lead to adhesions between the enclosed and enclosing segments; necrosis and gangrene usually ensue. It is a comparatively favorable issue when the

whole of the invaginated segment necroses and separates so as to be cast off completely; the upper portion becoming adherent and its channel continuous with that of the lower, recovery may and in some cases does take place.

The cause of intussusception is not certainly made out. According to LEICHTENSTERN it depends on paresis or partial paralysis of a limited portion of the bowel. When this occurs an energetic peristaltic movement of the portion immediately above may thrust the latter into the flaccid or paralyzed portion; and then continued peristalsis rapidly increases the invagination.

Prolapse of the bowel implies its escape through some normal or abnormal opening. The anus is the only possible normal opening, and through it the rectum may protrude.

Prolapsus recti (or *ani*) occurs during violent straining at stool, especially when the intestine is relaxed by chronic inflammation. The protruding bowel forms a kind of tumor covered with mucous membrane; it often becomes inflamed or gangrenous, particularly in cases where by adhesions or constriction the prolapse has become irreducible.

479. **Non-specific inflammations.** The varieties of inflammation described in Arts. 420-428 are all met with more or less frequently in the intestine. Catarrhal inflammation (**intestinal catarrh**) or enteritis is especially common. The catarrhal secretion may be serous, mucous, purulent, or of some intermediate kind. In the colon the amount of mucus secreted is sometimes enormous. Catarrhal enteritis is usually an acute disorder and ends in complete recovery. But in many cases the acute forms as well as the chronic leave behind them permanent structural change in the intestine.

Even in the milder forms the connective tissue lying between the crypts of Lieberkühn becomes infiltrated with liquid and extravasated cells. The epithelial cells pour out an excessive quantity of mucus, and become loosened from their sub-structures or fall away altogether. According to BÖHM desquamation of the epithelium is characteristic of poisoning with arsenic and with some substances of the muscarin-group. If this process goes too far or lasts too long, the lost epithelium fails to be reproduced and the intestinal wall becomes atrophied. When slight such atrophy is not apparent to the unaided eye, or at most it gives the wall an unusually smooth and level appearance. Under the microscope the glandular layer of the mucosa is seen to be thinned and wasted. The crypts may lose a half or two-thirds of their depth, and the villi of the small intestine are slender and stunted.

After an attack of ulcerative catarrh, in which not only the epithelium but the underlying connective tissue is injured or destroyed (Art. 421, Fig. 167), the atrophy is usually much more marked. The ulcerated portion of the bowel is covered with mucus, pus, and whitish granulations and shreds of tissue; these last are simply the necrosed remains.

of the glandular layer, which has become infiltrated and broken down. The ulceration is in fact associated with diphtheritic necrosis of the mucous membrane, and in such cases not only the upper layer but the whole of the glandular mucosa may perish, leaving the muscularis mucosæ covered with nothing but a film of nucleated connective tissue (Art. 417, Fig. 165).

The muscularis mucosæ as a rule is very slightly altered. Its unstriped fibres are only in rare cases found to be thinned, or atrophied, or fatty. The submucosa is generally unchanged; when the ulceration goes deep it may be infiltrated with leucocytes or thickened from subsequent fibrous hyperplasia.

The lymphadenoid follicles are in the slighter forms of catarrh but little affected; at most they are somewhat enlarged. Sometimes in suppurative or ulcerative inflammations they are more markedly altered, and may then perish by suppuration, giving rise to what is called follicular catarrh. They may leave behind small pitted ulcers known as **follicular ulcers**.

Catarrh ending in **atrophy** is commonest in the large intestine, and especially in the cæcum. NOTHNAGEL found that in 80 per cent of the adults he examined there were traces of atrophy in the large intestine, at times confined entirely to the cæcum. The ascending colon came next as regards frequency, and then in diminishing order the lower part of the ileum, the remainder of the colon, the upper part of the ileum, and the jejunum. In children intestinal atrophy is often met with, following on acute and subacute, as well as on chronic, catarrh.

The muscular coat is usually unaffected, but here and there it may be atrophied, or in catarrh from venous engorgement it may be hypertrophied (NOTHNAGEL). It is not very liable to degeneration, but sometimes as in phthisis it is found to be fatty (WAGNER). Lastly, there is a congenital form of atrophy, a hypoplasia of the muscularis which is not made up in later life (NOTHNAGEL).

In chronic catarrh atrophy is occasionally associated with the development of hyperplastic growths. They take the form of indurations of the submucosa or polypous excrescences rising from the mucosa. When fully developed these last consist of fibrous tissue enclosing a few remains of glandular structures, which here and there are degenerated into closed **cysts**.

Diphtheritic and **croupous inflammations** occur chiefly in the colon and in the lower part of the small intestine. The diphtheritic form closely resembles ulcerative catarrh, and is not easily distinguished from it. The intensely red and swollen membrane is covered with a thin but tough film or a broad continuous slough (Art. 472). This form is sometimes at least due to specific infection.

Croupous inflammation is rarely very extensive, though now and then considerable portions of the bowel are found to be red and highly

swollen and covered with a thin flaky fibrinous deposit. Small circumscribed croupous exudations are more frequently met with, associated with ulcerative catarrh and diphtheritic necrosis.

References:—WAGNER, *Arch. d. Heilk.* II. (1868); KUNDRAT, *Gerhardt's Handbuch. d. Kinderkr.* IV.; WHITEHEAD, *Brit. med. Journ.* 1, 1871; WOODWARD, *Med. and surg. history of the War of the Rebellion* Part II. vol. 1 (medical history) Philadelphia 1879 (with references); DAMASCHINO, *Maladies des voies digestives* Paris 1880; KUSSMAUL and MAIER, *Arch. f. klin. Med.* IV.; SCHWARCK, *Croup and Diphtheritis d. Darmcanals* In. Diss. Bonn 1880; LEUBE, *Ziemssen's Cyclop.* VII.; NOTHNAGEL, *Zeitschr. f. klin. Med.* IV. (1882).

471. Inflammations of the bowel have received various names according to the particular parts affected. Several of these local inflammations exhibit peculiarities depending on the anatomical relations of their respective seats. The chief of them are the following.

(1) **Duodenitis**, or inflammation of the duodenum, is usually associated with inflammation of the stomach. It not infrequently leads to obstruction at the mouth of the bile-duct, and thereby to retention of bile and jaundice (**catarrhal jaundice**).

The duodenum is also the seat of simple or perforating ulcer corresponding to perforating ulcer of the stomach, and like it dependent on digestive corrosion (KRAUS, *Das perforirende Geschwür im Duodenum* Berlin 1865).

(2) **Ileitis**, inflammation of the ileum, is often marked by the swelling and prominence of the solitary and agminated follicles. The former appear as reddish or grayish protuberant nodules, the agminated follicles as flat elevations, grayish-red or pink in color and pitted with numerous little depressions. When these follicles break down they leave behind them follicular ulcers.

(3) **Typhlitis** and **perityphlitis** imply inflammation of the vermiform appendage and the parts around it.

The vermiform appendage is peculiarly adapted to catch and retain substances passing through the cæcum. Matters which have been swallowed—such as grape-seeds, apple-pips, cherry-stones, and the like—and fæces, may accumulate in the appendage and set up inflammation. Sometimes these become crusted over with phosphates and carbonates and so form fæcal concretions or calculi (**entroliths**, Art. 479). The inflammation thus set up may extend to all the coats of the appendage and then attack the contiguous structures, and in this way necrosis and gangrene with perforation may be caused. The issue differs in different cases. It is comparatively favorable if the inflammation continues to be circumscribed, while the exudation is moderate in amount; protective adhesions and false membranes may thus be formed about the affected spot. It is very unfavorable when perforation takes place before adequate adhesions are formed; fatal peritonitis is nearly always induced. When perforation takes place into a part of the peritoneum shut off by

adhesions a burrowing fæcal abscess is produced, which may burst internally or externally. Sometimes the appendage is entirely obliterated by adhesive inflammation; but if the inner or intestinal end becomes closed while the remainder continues to be patent, the natural mucous secretion may collect in the latter and distended it into a **cyst**.

Typhlitis and perityphlitis are sometimes due to the extension by continuity of inflammation already existing in more distant parts of the cæcum or colon. Tuberculous and typhoid ulceration localized in the vermiform appendage may give rise to dangerous lesions.

(4) **Colitis**, or inflammation of the large intestine, is somewhat common. Its peculiarities have already been referred to (Art. 470). The exciting causes are very various. Sometimes it is due to the stoppage and accumulation of fæces forming hard masses or **scybala**, sometimes to septic infection, sometimes to a specific poison as in dysentery (Art. 472).

(5) **Proctitis** is an inflammation of the rectum. In many points it resembles inflammation of the vermiform appendage. Foreign matters and stagnating fæces are frequently the exciting agents; but disturbance of the circulation in the hæmorrhoidal veins may likewise end by inducing inflammatory change in the bowel.

Proctitis often results in the formation of ulcers, and of fibroid hyperplasia taking the form of induration of the rectal wall or of polypous excrescences. The inflamed surface is usually covered with a muco-purulent exudation. When the inflammation and ulceration extend deeply into the tissues of the wall of the bowel, the surrounding connective tissue becomes infiltrated and hyperplastic, or breaks down into abscesses containing fœtid pus (**periproctitis**). The ulcers of the mucosa and submucosa come in this way to communicate with burrowing sinuses and fistulous tracks extending into the surrounding parts, which are called incomplete or blind **internal fistulæ**. Circumscribed or enclosed periproctal abscesses may break outwardly, and then constitute blind **external fistulæ**. **Fistulæ** which communicate both with the rectum and with the exterior are called complete rectal fistulæ or **fistulæ in ano**. They become covered with a kind of factitious mucous membrane. **Fistulæ** occasionally communicate with the bladder or vagina.

Specific poisons like those of syphilis, tuberculosis, and dysentery, and cancer in the ulcerative stage, may give rise to morbid changes of a similar kind. There may even be periproctitis without any antecedent rectal ulceration, especially in connection with pyæmia, typhoid, acute rheumatism, and puerperal septicæmia.

References on typhlitis and perityphlitis:—MATTERSTOCK, *Gerhardt's Handb. d. Kinderkr.* VI.; BIERHOFF, *Arch. f. klin. Med.* XXXVII.; CORNIL, *Arch. de physiol.* 1873; WÖFLER, *Arch. f. klin. Chir.* XXI.; STEINER, *Zur path. Anat.*

d. Wurmfortsatzes Basle 1882 ; CRISP, *Trans. Path. Soc.* 1858 (foreign bodies in the appendage).

472. **Specific inflammations.** **Dysentery** is an inflammatory affection of the large intestine, due to the action of a specific virus. The exact nature of the virus is unknown, but it is probably bacterial. The affection is epidemic, endemic, or sporadic in its occurrence. The changes set up in the intestine closely resemble certain non-specific inflammations of the colon, especially such as depend on retention of fæces or accompany septic poisoning. For this reason the exact significance of the term dysentery is not easily fixed, inasmuch as it is often impossible to say from the post-mortem appearances whether these are the result of specific infection or not. Moreover it is not impossible that the so-called endemic dysentery of different countries may be really due to different specific poisons.

The intensity and extent of the dysenteric inflammation varies in different cases. It may be restricted to the rectum, sigmoid flexure, and descending colon, or it may reach up to or a little beyond the ileo-cæcal valve. Often too in the same case the various parts of the tract are variously affected.

In recent cases the mucous membrane is highly congested and swollen, and generally beset with minute extravasations of blood. The epithelial surface is overlaid with a glairy blood-streaked mucus. This presently becomes more slimy and blood-stained, and interspersed with the flaky fibrinous shreds and films (described in Art. 470) which indicate the beginning of superficial necrosis of the mucous membrane. Soon the necrosis is made sufficiently evident by the appearance of erosions and losses of substance.

We might perhaps distinguish a catarrhal and a diphtheritic form of dysenteric inflammation, but in practice the one passes insensibly into the other and the distinction is inappreciable. In slighter cases the necrosis and loss of substance are at first merely superficial (Fig. 177 *f*); but the deeper structures are successively attacked, and in severe cases the greater part or the whole of the glandular layer of the mucous membrane at particular spots may perish. The necrotic tissue is reduced to a turbid granular mass, in which the structural elements and the nuclei of the cells soon cease to be recognizable. The parts which undergo necrosis seldom cover any great extent of surface, and are often confined to the prominent ridges and folds of the mucous membrane; these look dirty-gray or black, while the intervening parts are still livid or dark-red. In other cases the necrotic tissue takes the form of a flaky more or less adherent coating, or more rarely of broad continuous sloughs. The underlying tissue is in all cases densely infiltrated with cells (d_1). The infiltration may extend through the entire thickness of the submucosa (e), and may at length invade the muscular layers.

The lymphadenoid follicles take part in the process, and frequently ulcerate. Occasionally the mucosa is undermined by suppuration beneath it, and in this way broad patches of the tissue are separated and cast off.

When the mucosa is removed, open ulcers are of course left behind. These vary much in their depth and extent; sometimes over a great part of the bowel the mucous membrane remains only in narrow strips and islands.

The affection may come to a standstill at various stages of its course, and repair then begins. The slighter cases, in which but little substance is lost, are naturally the readiest to heal; but a certain amount of atrophy of the mucosa always remains. When the ulcerative process has gone further, atrophic cicatrices are left to mark the site of the injury. In

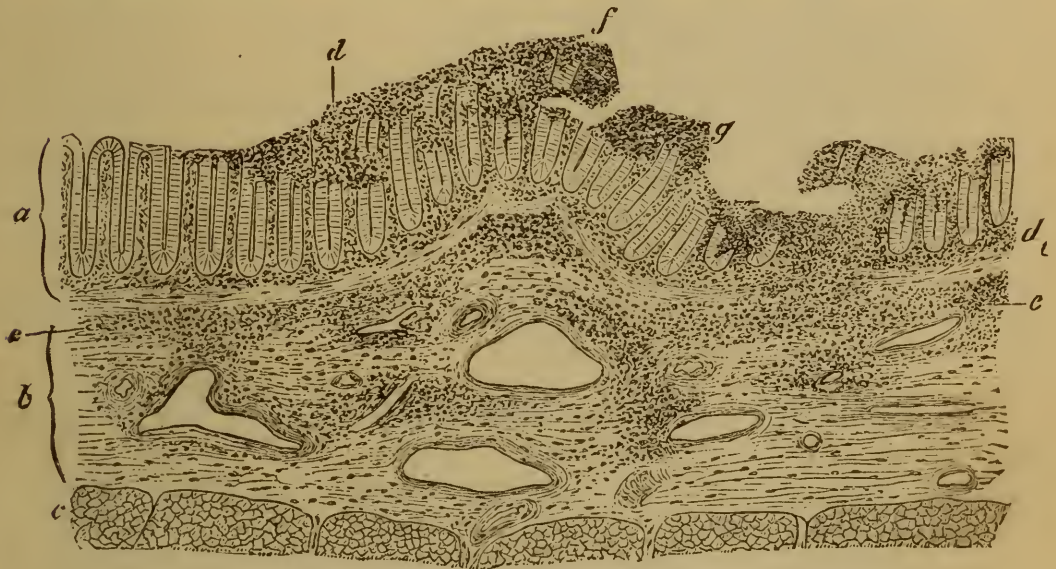

FIG. 177. SECTION THROUGH THE COLON FROM A CASE OF DYSENTERY.

(Hæmatoxylin staining: $\times 25$.)

- | | |
|---|---|
| a, mucosa. | e, infiltration of the submucosa. |
| b, submucosa. | f, superficial glandular layer, infiltrated and separating. |
| c, muscularis. | g, ulcer, the floor of which is infiltrated. |
| d, interglandular, and | |
| d ₁ , subglandular infiltration of the mucosa. | |

severe cases accompanied by great destruction of tissue, in which the acute specific inflammation is succeeded by chronic inflammation, the whole structure of the bowel is altered in a remarkable way. Over broad areas the glandular layer is almost or altogether absent; the deeper layers of the mucosa and submucosa look coarse and dense and indurated; the connective structures are hyperplastic; and the other coats are likewise tough, thickened, and unyielding. The channel of the intestine is usually narrowed, often so much so that a finger can hardly be introduced. The mucous membrane is only recognizable in isolated patches here and there, and these not infrequently assume the form of papillary or polypous outgrowths from the general surface.

In the scarred and indurated portions of the bowel the submucous connective tissue (and that of the mucosa if any remains) is thicker and denser than normal, and often shows signs of cellular infiltration. There may be no trace of the intestinal glands remaining, or only their lower parts; while in some places portions of the glandular layer which have been separated and abstricted by the invading fibrous tissue may become distended with secretion, and form small cysts lined within with cylindrical epithelium. The muscular coats are traversed by dense bands of coarse fibrous tissue. A certain amount of chronic inflammation, accompanied by muco-purulent discharge, is often kept up long after the acute disorder is at an end; this constitutes what is sometimes called chronic dysentery, or by the older authors **cœliac flux**.

The author had the opportunity of examining certain cases in which epidemic dysentery had proved fatal in an early stage, and was able to demonstrate the presence of multitudes of micrococci in the affected tissues. They were found not only in the necrotic patches, but also in the neighboring unattacked portions of the mucosa. They lay partly beneath the glands of the mucosa, partly in the lymphatics of the submucosa: that is to say in tissue which was still to all appearance sound. In these cases it would appear that the micrococci were concerned in the causation of the disease. PRIOR (*Cent. f. klin. Med.* 17, 1883) records similar observations. In other cases which seemed precisely similar no micrococci could be discovered. For example, none were found in the case of the five natives of Tierra del Fuego who died of dysentery at Zurich in March 1882 (compare SEITZ, *Virch. Arch.* vol. 91).

473. **Epidemic or Asiatic cholera** is characterized anatomically by the presence of an acute inflammation extending over the whole of the intestine, accompanied by an enormously copious transudation of liquid through the mucous membrane.

In cases which prove fatal in the first two or three days the bowel is found to contain a great quantity of a turbid grayish inodorous alkaline liquid, often mingled with minute shreds and flakes—the so-called ‘rice-water’ stools. The mucous membrane is moist, pink, injected, and swollen. Sometimes the serous surface is dull or opaque. The epithelium separates within a few hours after death. The follicles of the small intestine are swollen, and gray or bright pink in color. Apart from the epithelial desquamation which is mainly a post-mortem phenomenon, microscopic examination reveals only a somewhat intense cellular infiltration of the mucosa and submucosa, and sometimes even of the serous coat.

When death does not occur till a later stage of the disease, the appearance of the intestine is notably different. The contents are scanty and less liquid, and at the same time they show more signs of the presence of bile. The mucous membrane is pale or slate colored, or it may be injected and beset with minute hæmorrhages. Ulcers occur, especially in the colon and lower part of the ileum. Sometimes the large intestine has almost the same look as in dysentery (Art. 472).

The special virus of cholera is as yet unknown.

KOCH and others have found peculiar bacilli in the intestinal mucous membrane of the cholera patients, but they have failed to reproduce the disease in animals by inoculation or otherwise. The experiments and observations hitherto made leave the question of the genesis of the disease unsettled. For summaries of the reports of the French and German Commissioners sent to Egypt in 1883 see *Practitioner* (March 1884) and *Brit. med. Journ.* (2, 1883 and 1, 1884).

474. **Typhoid** (or enteric) **fever** is an infective disease, due (according to KLEBS, EBERT, and KOCH) to the invasion of a specific bacillus (Art. 206).

The morbid changes in typhoid appear chiefly in the lower part of the ileum and the upper part of the colon; they are seldom met with

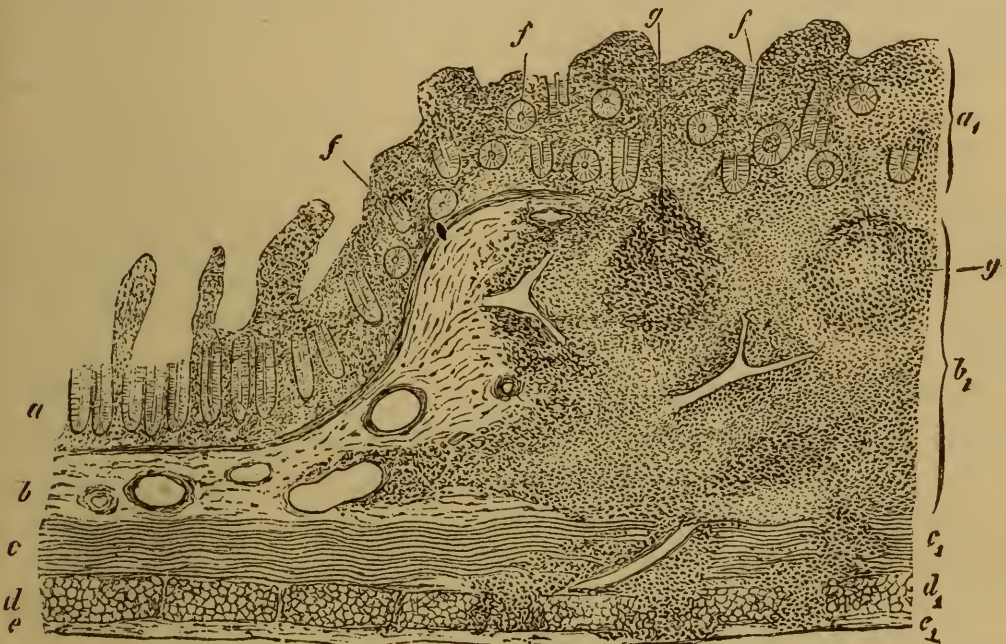


FIG. 178. SECTION THROUGH THE MARGIN OF A PEYER'S PATCH FROM A CASE OF TYPHOID FEVER.

(Aniline-brown staining: $\times 15$.)

a, mucosa.

b, submucosa.

c, internal muscular coat.

d, external muscular coat.

e, serous coat.

(a₁ b₁ c₁ d₁ e₁, the same layers infiltrated and swollen).

., crypts cut through transversely.

g, lymphadenoid follicles.

much higher or much lower in the intestine. The changes consist essentially of a necrotic inflammatory infiltration of the follicular structures and the parts around them, accompanied by a catarrhal inflammation of the rest of the mucous membrane.

In the first few days of the attack the mucous membrane of the lower part of the ileum and its agminated glands of Peyer's patches are intensely congested and uniformly swollen. Soon the swelling of the patches becomes more marked, raised and winding ridges not unlike the cerebral evolutions in miniature appearing on their surface. The swelling extends more or less quickly over the whole of each patch, so that it

has in general the look of a raised bed or garden-plot projecting above the general surface. When the swelling is at its height the ridges are generally levelled up as it were, and are no more distinguishable: the surface of the patch is then smooth or pitted with minute depressions corresponding to the sites of the individual follicles. The solitary follicles form rounded nodules by virtue of the same process.

When this stage (of swelling) is complete the patches and follicles, which at first were bright-red in color, become pale and creamy-white.

The swelling of the patches and follicles is chiefly due to the extreme cellular infiltration of the mucosa (Fig. 178 a_1) and submucosa (b_1). The glands (f) of the mucosa are thereby thrust assunder and displaced, and the villi are likewise infiltrated and swollen. The submucosa underlying the patches is uniformly infiltrated (b_1). In the earlier stages the several follicles (g) within the infiltrated region are still distinct and recognizable, but they are presently merged and lost in the general assemblage of lymphoid cells and leucocytes, extravasated and other.

The muscular and serous coats (c_1, d_1, e_1) are also invaded by the extravasated cells, though in a less marked degree.

The number of swollen patches and follicles varies much. Often but a small number or even a single one is markedly affected; while in other cases the affection extends upwards to the jejunum or downwards to the anus.

In the second week of the disease partial disintegration and necrosis of the swollen patches usually sets in. The disintegration attacks the whole of the central part of the patch, or two or more parts of it simultaneously. The surface quickly assumes a frayed or ragged appearance and becomes yellow or brown from the action of the bile. Gradually the disintegrated tissue or slough becomes loosened at its base and edges from the surviving structures, and in a few days is cast off.

After the separation of the sloughs, an erosion or **typhoid ulcer** is left, the floor of which generally looks smooth and clean. The borders of the ulcer are at this stage still swollen and infiltrated.

The ulcers usually remain coextensive with or very slightly overpass the area of the infiltrated patches and follicles; they rarely invade the tissue beyond. Cases however occur in which, especially around the ileo-cæcal valve, extensive tracts of mucous membrane are attacked and disintegrated by the advance of the ulcerative process. In the vertical direction it seldom goes beyond the mucosa and submucosa. It is only when the infiltration of the muscular coats has been extreme that they too break down and ulcerate. In exceptionally severe inflammation the serous coat also may be attacked, but never to the same extent as the overlying layers; perforation and fatal peritonitis may occur in such a case.

The processes of absorption and repair begin at various stages of the disease. If no necrosis takes place, the swelling of the patches goes

down as the infiltrated material is absorbed: the patches thereupon become less stiffly turgid, and once more hyperæmic. Red corpuscles escape from the damaged vessels, and the tissue takes on a red or blood-stained tint which presently turns to a slaty gray. The infiltrated borders of the typhoid ulcers become reduced and softened and hyperæmic by the same steps. Often enough considerable hæmorrhage ensues, leading not only to hæmorrhagic infiltration of the tissue but to actual escape of blood into the intestinal canal. As the healing process goes on the softened and overhanging borders of the ulcer become adherent to the floor; the latter is gradually covered over with delicate granulations, and soon receives an investment of epithelial cells.

The site of a former typhoid ulcer appears for a long time after as a smooth shallow depression, devoid of glands and follicles, slaty-gray in color, and situated in the midst of a Peyer's patch itself discolored in like manner.

The characteristic inflammation of the lymphadenoid structures of the intestine in typhoid is sometimes accompanied by an inflammation of the corresponding mesenteric glands. They are at first red, swollen, and œdematous (Art. 336); but as the accumulation in them of leucocytes and lymphoid elements becomes more marked they take on a light-gray tint. The swelling either subsides from re-absorption of the infiltrated matters, the gland becoming soft and hyperæmic; or it terminates in partial necrosis, and opaque grayish patches appear within the substance of the gland. These patches may likewise be absorbed at a later stage, but they often become caseous or calcified. The spleen is usually swollen, and inflammation of the throat, especially affecting the follicular structures of the pharynx, is not an uncommon accompaniment.

With regard to the bacillus of typhoid see the references in Art. 206; and also EBERTH, *Virch. Arch.* vol. 83, *Samml. klin. Vorträge* no. 226; KLEIN, *Report of Med. Off. Loc. Gov. Board* 1875; W. MEYER, *Untersuch. üb. d. Bacillen d. Abdominaltyphus* In. Diss. Berlin 1882; WERNICH, *Zeitschr. f. klin. Med.* IV., v.; FRIEDLÄNDER, *Sitzungsber. d. physiol. Gesell. zu Berlin* 1881; COATS, *Brit. Med. Journ.* 1, 1882; CROOKE, *ibid.* 2, 1882; LETZERICH, *Arch. f. exper. Path.* XIV., *Aetiologie d. Typhus abdominalis* Leipzig 1883; GAFFKY, *Mitth. a. d. k. Gesundheitsamte* Berlin 1884.

475. **Tuberculosis** of the intestine has already been considered in Art. 428, so far at least as the minuter tuberculous tissue-changes are concerned. It is one of the commonest of intestinal diseases, and chiefly attacks the lymphadenoid structures. The neighborhood of the ileo-cæcal valve is the region most frequently affected, but often enough the whole of the large intestine down to the anus becomes tuberculous.

At first a little nodule covered with epithelium protrudes from the surface of a Peyer's patch or over a solitary follicle. After a time the centre of the nodule becomes pale-yellow, indicating that necrosis and caseation have begun. The caseous parts break down and a **tuberculous ulcer** (Fig. 179 *h*) with infiltrated borders is formed. The ulcer is minute, but soon enlarges as it coalesces with others formed

in like manner, while new foci of disintegration appear in its gradually advancing borders.

Ulcers of any great size are usually very irregular in their outline. Some are rounded, but more are oval or at least elongated, the longer axis being transverse to the axis of the bowel: others again are sinuous and spreading.

The borders are infiltrated, but in the larger ulcers not uniformly so. The gray or reddish raised edge is here and there beset with yellow nodules, and characteristic gray and yellow nodules appear on the floor. The depth of the ulcer is irregular, and sometimes small islands of undestroyed mucous membrane rise as grayish-red protuberances from its floor.

Where the ulceration is extensive, not only are the mucosa and sub-

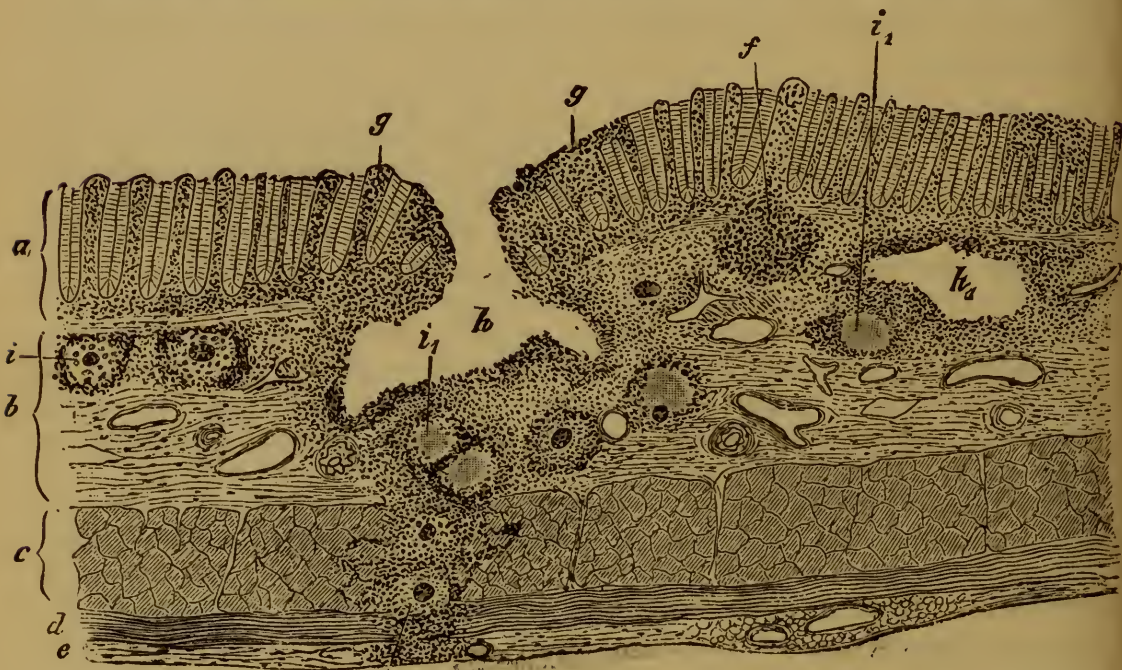


FIG. 179. TUBERCULOSIS OF THE LARGE INTESTINE.

(Bismark-brown staining: $\times 30$.)

- | | |
|----------------------------|--|
| a, mucosa. | g, cellular infiltration of the mucosa. |
| b, submucosa. | h, tuberculous ulcer. |
| c, internal muscular coat. | h ₁ , tuberculous abscess. |
| d, external muscular coat. | i, recent or gray tubercle. |
| e, serous coat. | i ₁ , caseous or yellow tubercle. |
| f, solitary follicle. | |

mucosa attacked but the muscular and at length the serous coats are invaded by the tuberculous infiltration. On the serous surface the gray tubercles appear in groups or beaded rows, the membrane in the neighborhood being red and injected.

Only in rare cases does tuberculous ulceration come to a stand-still and issue in cicatrization. As a rule it advances steadily, involving more and more of the bowel until the patient dies.

476. **Syphilis of the intestine.** Apart from the mucous patches frequently met with about the anus in syphilitic patients (Art. 379), there is a form of ulceration of the rectum also due to syphilis and occurring chiefly in women. It extends three or four inches up the bowel, and is usually separated by a distinct line from the healthy mucous membrane. The ulcerated surface is remarkably uneven and irregular, and is generally interspersed with strips and patches of more or less undermined epithelial tissue. The borders of the ulcer are undermined in like manner. This appearance is due to the fact that the inflammation attacks chiefly the submucosa, and destroys it more rapidly than the overlying strata.

The ulcer yields an abundant purulent secretion. As it is met with almost exclusively in women suffering from syphilitic disease of the genital organs, it is probably due to infection conveyed to the rectum by the secretions escaping from the vagina. Syphilitic ulceration of the colon or small intestine is extremely rare.

477. **Intestinal mycosis** (*enteromycosis bacteritica*) is a general term, including several distinct affections. Strictly speaking it is applicable to tuberculosis, to typhoid, and perhaps to some forms of dysentery. Usually however it is confined to intestinal anthrax, and to various forms of meat-poisoning (Arts. 204, 206) by which changes in the intestine not dissimilar to those of typhoid are sometimes produced.

In intestinal anthrax we have not only diffuse and wide-spread catarrh of the bowel, but also localized changes. These take the form of small circumscribed hæmorrhagic patches, with bluish-red or brownish-red borders and a grayish or greenish yellow slough in the centre. Sometimes the patch and the slough are larger. Bacilli abound in the patches and in the surrounding tissues, especially in the blood-vessels; and also in the swollen lymphatic glands corresponding to the affected parts.

An affection of the bowel having exactly the same microscopic appearance is met with in septicæmic affections. In the case of a patient with disease of the spinal cord, who died of blood-poisoning from gangrenous balanitis and cystitis, the author found the large and small intestines beset with a multitude of small hæmorrhagic patches, each with its central slough as above described.

478. **Tumors of the intestine.** The tumor-like inflammatory growths, papillary or polypous in form, have been referred to in Art. 470. Non-inflammatory polypi of the same type are also met with, both congenital and acquired. They closely imitate the normal mucous membrane in structure, though their glands are often more abundant and at the same time more branched and convoluted. These growths are known as glandular hyperplasias, and innocent or **non-malignant adenomata**. They are rare in the small intestine, but common enough in the rectum. When pressed or dragged upon the pedicle may become

so elongated that the polypus protrudes from the anus. Individual glands are sometimes occluded and distended, giving rise to small cysts within the growth.

Carcinoma is by far the most important of the neoplasms affecting the intestine. It is not very rare as an intestinal disease, though rarer than carcinoma of the stomach. The rectum, the sigmoid, splenic, and hepatic flexures of the colon, and the cæcum, are the commonest seats. Rectal cancer sometimes extends only to the parts about the anus, but in other cases it invades the pelvic and abdominal viscera.

Carcinoma of the small intestine is rare, but in the duodenum and especially in the neighborhood of the opening of the bile-duct it is somewhat more frequent.

Intestinal cancer takes the form of soft fungous tumors which are solitary and sharply circumscribed, or of papillary roughnesses and excrescences covering a considerable area. Infiltration of the intestinal wall with cancer-cells usually takes place at an early stage, and leads to thickening and induration. If this extends round the whole circumference of the bowel, it is transformed into a thick-walled rigid tube; the rectum is the commonest seat of this indurative change, and less frequently the colon.

In most post-mortem examinations of cases of this disease we find the surface of the neoplasm already broken down, leaving a cancerous ulcer with characteristically infiltrated borders. But sometimes the borders likewise are disintegrated and eroded, and then the ulcer has quite the appearance of an ordinary non-malignant inflammatory ulcer. In other cases the borders and floor of the ulcer become scarred over and shrunken, leading sometimes to extreme constriction of the bowel: this is particularly apt to occur when the ulceration extends in an annular form round the intestine.

Carcinomata of the intestine are of various histological types. One of the commonest is the so-called destructive adenoma or **adenocarcinoma** (Art. 169). It gives rise to fungous and papillary outgrowths from the mucous membrane, and speedily invades the submucous, muscular, and serous coats. The smaller tumors consist essentially of epithelial growths resembling tubular glands and clothed with cylindrical epithelium. At later stages the glandular type in part disappears, and large solid cell-nests are formed, with cylindrical epithelial cells at the periphery only.

Colloid carcinoma is the next in order of frequency, especially in the rectum. It takes the form of large gelatinous growths, covering a great extent of surface and infiltrating the intestinal wall. Simple carcinoma and scirrhus are rarer than either of the two just mentioned. Melano-carcinoma occurs almost exclusively in the rectum.

When a cancer of the intestine breaks down and ulcerates, at the same time invading the deeper layers of the wall, it generally induces

inflammatory changes in the serous coat. These lead to the formation of new vascular fibrous tissue, by which the affected part of the bowel is bound down to the structures around it. Perforation of the intestine occurs in some cases as a result of cancerous ulceration. Metastatic growths are usually met with, chiefly in the lymphatic glands, peritoneum, and liver.

Connective-tissue growths are rare in the intestine, and have much less significance than the carcinomata. Fibroma, lipoma, myoma, angioma, and sarcoma, have been observed.

These are developed from the mucosa and submucosa, and in part from the muscular and serous coats. When they protrude as polypi from the inner surface of the bowel they may obstruct the passage, or by their weight drag down and invaginate a portion of the wall. Pedunculated growths may be dragged upon and actually torn off by the peristaltic action of the bowel, and so be ejected with the fæces.

479. **Parasites and concretions.** The vegetable and animal parasites which infest the intestine have been described in detail in the General Pathological Anatomy (Arts. 182-250.)

Among the **vegetable parasites** the Schizomycetes or Bacteria are undoubtedly the most important. The bowel perpetually harbors a multitude of these fungi, of very various kinds. Hence it is difficult to say how far the various intestinal affections, and especially the inflammations, are due to the ordinary microparasites present in the fæces, and how far to distinct and specific forms. As we have indicated in the foregoing Articles, typhoid fever, tuberculosis, anthrax, and perhaps cholera and acute dysentery, are due to specific bacteria.

The Schizomycetes (Art. 183) met with in the intestine belong to the classes of Sphærobacteria (*Micrococci*), Microbacteria (*Bacterium termo*), and Desmobacteria (*Bacilli*, *Clostridium*). In rare cases the thrush-fungus attacks the mucous membrane, but in the intestine the conditions necessary for its development seldom occur.

Of **animal parasites** the following may be enumerated. They are described in the Articles referred to.

Cercomonas intestinalis, *Paramæcium coli* (Art. 250).

Tænia mediocanellata or *saginata* (Art. 244).

Tænia solium (Art. 241).

Tænia nana, *Tænia cucumerina* (Art. 244).

Bothriocephalus latus (Art. 249).

Ascaris lumbricoides, *Ascaris mystax* (Art. 228).

Trichina spiralis (Art. 232).

Trichocephalus dispar (Art. 230).

Oxyuris vermicularis (Art. 229).

Anchylostoma duodenale or *Dochmius duodenalis* (Art. 231).

Of loose or foreign bodies met with in the intestine, the only ones

which have any pathological interest are those which are produced
in

To say nothing of the hardened scybalous masses produced by retention of fæces, there are certain stony concretions which have received the name of **enteroliths**, or **intestinal calculi**. They are found chiefly in the cæcum, vermiform appendage, and colon, and more rarely in the small intestine; they usually lie in sacculations or diverticula of the wall. Three varieties have been distinguished (LEICHTENSTERN, *Ziemssen's Cyclop.* VII.).

(1) Heavy stony stratified concretions, the successive layers being white, yellow, and brown. These consist of magnesium phosphate, ammonio-magnesium phosphate, and organic matters. They are seldom larger than a chestnut, and are generally rounded in shape. They frequently contain some small foreign body as a nucleus.

(2) Enteroliths of low specific gravity and irregular form, porous and somewhat elastic in texture. They consist of a felted mass of indigestible husks and other vegetable refuse, intermingled with indurated fæces and earthy or chalky matters. They vary in size from that of a chestnut to that of an orange.

(3) Stones due to the long-continued use of certain mineral drugs, such as chalk, magnesia, and oxide of bismuth.

In addition to these, which are formed in the intestine itself, we find **gall-stones** which have escaped from the bile-duct (Art. 508).

Such concretions, and foreign bodies reaching the intestine from the exterior, may give rise to partial or complete obstruction of the bowel. Bodies lodging in the pouches of the rectum frequently do so. The result is of course stoppage of the fæces; and with this sometimes inflammation, ulceration, and perforation of the intestinal wall.

NOTHNAGEL (*Zeitschr. f. klin. Med.* III.) found that fæces frequently contain a peculiar kind of monad. When dead the organisms appear as round sharp-contoured spherules, with little refracting power. When alive they are pear-shaped, with an actively-moving flagellum at the pointed end. They change their form somewhat rapidly. In all probability they are quite harmless.

On enteroliths and intestinal concretions of all kinds see LEICHTENSTERN (*Ziemssen's Cyclopædia* VII.). In horses and horned cattle these are met with far more frequently than in human beings. The intestine of these animals always contains fragments of vegetable refuse and hairs which have been licked off and swallowed, and such matters form a nucleus for concretions to grow about. The true calculi, met with chiefly in horses, are hard stony balls consisting for the most part of magnesium phosphate. The spongy or false stones consist of felted hairs and fibres which are merely crusted over. Balls are sometimes found composed entirely or almost entirely of hairs; these go under the name of hair balls or **bezoars** or *ægagropili* (from *αἰξ* *αγριοῦ* a wild goat, *πίλος* felt). In ruminants they usually lie in the cæcum or colon, in swine they are more frequently found in the small intestine.

FRIEDLANDER (*Berl. med. Gesellschaft* 1882, *Lond. med. Record* 1881) recently reported the case of a joiner who was accustomed to suck shellac-varnish, and

whose intestine contained a concretion consisting almost wholly of shellac. ALEXANDER (*Liverpool Med.-chir. Journ.* 1882) removed from the intestine of a fowl-dealer a bezoar containing a felted mass of downy hairs which the man had licked from his fingers while engaged in plucking poultry.

The origin and composition of intestinal calculi and concretions have been recently studied by SCHUBERG (*Virch. Arch.* vol. 90). He asserts that the intestinal concretions of the herbivora consist chiefly of carbonates, while those of the carnivora are phosphatic. In man the composition of these stones varies with the food habitually used.

For cases see LEICHTENSTERN (*loc. cit.*); BROOKHOUSE, *Lancet* 2, 1882; FELTZ, *Bulletin Soc. clin. de Paris* 1881-82; KER, *Brit. Med. Journ.* 2, 1881.

According to BIENSTOCK (*Fortschritte d. Medicin* 1883) the fæces in health contain various forms of bacilli, of which three appear to have no effect on the contents of the intestine; while another induces the putrid decomposition of albuminoids studied by NENCKI, BRIEGER, SALKOWSKI, and BERGMANN (Art. 191), and another effects the decomposition of carbohydrates. Of the last two the former is absent in the fæces of suckling infants. Micrococci are absent or scanty in healthy fæces.

SECTION VIII.

THE LIVER AND PANCREAS.

CHAPTER LV.

PIGMENTARY INFILTRATION OF THE LIVER.

480. The **liver** is the largest gland in the body, and the due performance of its functions is of essential importance to health. Its large size brings it into anatomical relation with many and various organs, and as it is only in part shielded by the wall of the thorax it is exposed to direct injuries from without which modify its form and position, and it may be its structure and function also. Its peculiar relations to the vascular system expose it to injury from the side of the circulation, and that in a twofold manner. Noxious matters, in the first place, may be brought to it, as to other organs, by the blood of the general or systemic circulation; and, in the second, by the venous blood collected by the portal vessels from the alimentary canal and spleen.

The capillary system of the liver is remarkably elaborate and capacious. Moreover, the portal blood circulates under very low pressure. The circulation within the liver is therefore very slow. One consequence is—that foreign substances suspended in the blood are very apt to be deposited in the liver (Arts. 266–268), and this is true of the arterial blood (brought by the hepatic artery) as well as of the portal blood. Pigmentation or **pigmentary infiltration** of the liver-substance is the not uncommon result.

When the blood contains any considerable quantity of disintegrated red corpuscles, or of the colored iron-compounds referred to in Art. 266, and these are in part deposited in the liver, they at first lodge in the capillaries of the interlobular connective tissue (Fig. 180 *d*) or in the peripheral or portal zone of the lobules (*e*). Presently they escape from the vessels and appear in the interlobular connective tissue, and to some extent in the interior of the liver-cells (Art. 481). When the quantity of pigment in circulation is great the pigmentation may be so dense that the structure of the tissue is completely masked by it (*d*); the biliary capillaries, and the contours of the liver-cells at the periphery of the lobules, being no longer distinguishable.

The pigment derived from disintegrated blood-corpuscles is yellow, brown, or black, and the tint communicated to the infiltrated tissue varies accordingly. As the deposit occurs chiefly if not exclusively about the portal or interlobular vessels the pigmented patches follow their dis-

tribution (Fig. 180), and stand out in marked contrast to the pale or unpigmented central parts of the lobules.

If the blood contains, as in leukæmia, an excess of colorless corpuscles, these are in like manner deposited in large numbers in the liver and give rise to what is called **leukæmic infiltration**. The deposits are distributed in the way just described, and are sometimes enormous in amount. The liver as a whole becomes swollen, and on section the lobules appear separated from each other by a broad zone of grayish-white. Sometimes nodular aggregations of the same kind accompany the general diffuse infiltration; and the connective tissue being thereby distended and

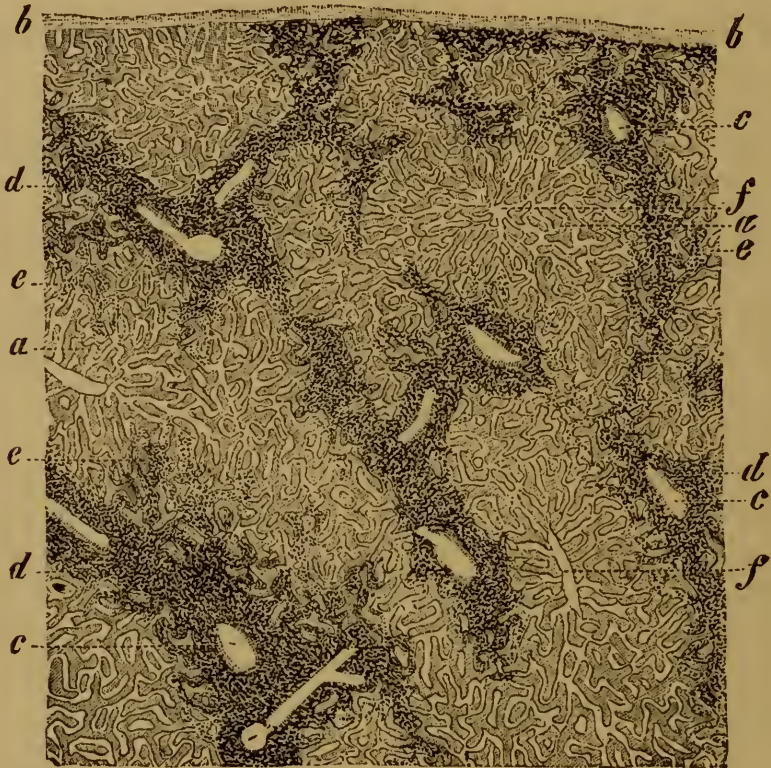


FIG. 180. PIGMENTARY INFILTRATION OF THE LIVER.

(After absorption of extravasated blood: carmine staining, mounted in Canada balsam: $\times 20$)

a, lobule or acinus.

b, serous covering (peritoneum).

c, portal vessels.

d, infiltrated interlobular connective tissue.

e, pigment in the lobular capillaries.

f, intralobular veins.

loosened into a sort of mesh-work, the nodules have exactly the look of lymphadenoid tissue.

Noxious as well as innocuous matters may in like manner be deposited in the liver from the blood. Of these microparasites are the most important, inasmuch as their settlement in the capillaries may give rise to inflammation and necrosis of the liver-substance (Arts. 493, 494).

Structure of the liver. To understand aright the morbid changes of the liver it is necessary to have a clear and accurate idea of its normal structure. The clue to this lies in the distribution of the blood-vessels within the organ.

The hepatic vein forms a kind of tree rising from the vena cava as a base; the terminal branches are all of nearly the same size and each is at nearly the same distance from its neighbors. To each terminal branch (Fig. 180 *f*) belongs a system of capillaries, which converge from all sides towards the branch. The system of capillaries belonging to each branch is of nearly the same extent, and is grouped about the branch like a globular fruit round the central stem. The group of capillaries corresponds to the structural unit of the liver, the lobule or acinus (Fig. 180 *a*); the terminal branch or stem is the intralobular or central vein (*f*).

The meshes of the group of lobular capillaries are occupied by liver-cells, in such a way that each cell is in relation to several capillaries, and each capillary is surrounded completely with liver-cells. When seen in section the liver-cells seem grouped in columns or series, alternating with the capillaries: these columns are sometimes spoken of as hepatic trabeculæ. Where two or more liver-cells are in contact the minute radicles of the bile-ducts take their rise. A fine groove runs along the surface of contact of each cell, and the grooves being apposed an intercellular canal is thus formed. The several canals intercommunicate and so give rise to a network of bile-capillaries. The number of lobules is very great. In the human liver they are in close contact with each other, and the lobular capillary-system of one in general communicates freely with that of its neighbor. This is however not always the case, for in many parts the lobules are separated by a space filled up with connective tissue. This interlobular connective tissue is called the 'capsule of Glisson,' and serves first of all as a connecting framework for the several lobules, and secondly as a supporting sheath for the vessels which bring blood (arterial and portal) to the lobules and carry bile away from them. The latter vessels or bile-ducts are tubes lined with cylindrical epithelium, and are connected with the intralobular bile-capillaries or interlobular bile-canals already described.

The blood-supply of the liver is twofold; there is an arterial system and a portal system of vessels. The portal vessels run between the lobules (and hence are called interlobular veins), and deliver their blood directly into the lobular capillaries. The arterial blood passes in the first instance into the capillaries which permeate the connective tissue of the capsule of Glisson (vaginal and interlobular capillaries), and thence passes with the portal blood into the lobular capillaries.

Very little connective tissue accompanies the capillaries as they pass into the lobules, and it can be made out at all only by special methods of examination. The larger lymphatics lie in the interlobular connective tissue and in the sheaths of the larger blood-vessels.

481. The liver is a secreting gland, in which chemical changes of a remarkable kind are carried out. The chief products of these are—the bile-acids (glycocholic and taurocholic), to some extent derivatives of albuminoid or proteid bodies—bile-pigments, whose source is the coloring-matter of the blood—and glycogen, elaborated from the carbohydrates which are brought to the liver. A series of interchanges are thus continually going on between the glandular substance of the liver and the blood which circulates through it. Matters of various kinds are taken up and transformed in manifold ways within the liver-cells; while some substances such as fat are simply deposited or stored in the cells, and may remain unchanged for a considerable time. As certain of the normal constituents of the blood are transformed and secreted by the

liver, so also abnormal substances circulating in the blood may be taken up from it and excreted by the same channel. In this way arsenic, antimony, lead, copper, mercury, and sodium indigosulphate, are separated from the blood and cast out of the body.

In consequence of the work thus thrown upon the liver, it not infrequently shows signs of degenerative change. This is most apparent when from any cause the physiological demands upon it become excessive. When for instance in pernicious anæmia (Art. 261) the disintegration of red blood-corpuscles is greatly increased, we have not only the accumulation of pigmentary detritus around and within the lobules (Art. 480), but also an actual infiltration of the liver-cells themselves (Fig. 181). Cases occur in which almost every cell contains yellow, brown, or orange granules of pigment containing iron, especially along the central parts of the trabeculæ where the intercellular bile-canals run. QUINCKE has shown that the liver-cells also enclose colorless

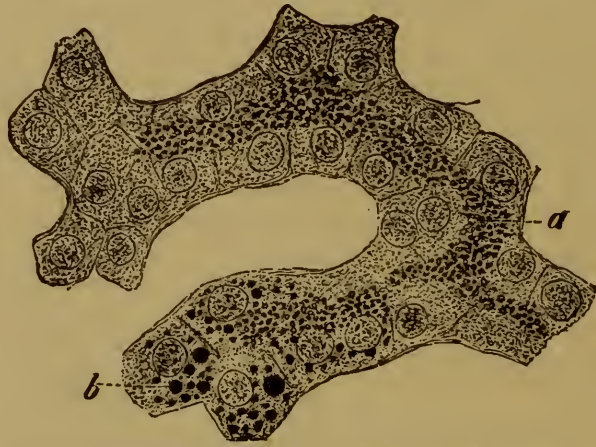


FIG. 181. LIVER-CELLS INFILTRATED WITH YELLOW PIGMENT FROM A CASE OF PERNICIOUS ANÆMIA.

(Stained with perosmic acid and carmine: $\times 350$.)

a, pigment-granules.

b, cells undergoing fatty degeneration (oil-globules stained black).

granules containing iron, as may be seen by the greenish-black tint they assume when treated with ammonium sulphide. The presence of the pigment-granules is generally made apparent to the naked eye by the pale brownish-red tint they impart to the liver-substance.

The presence of these iron-compounds in the liver can be explained only by supposing that the excretion of the products of blood-disintegration through the liver cannot keep pace with the supply. The accumulation is favored by the fact that the action of the liver itself is impaired in consequence of the general anæmia. In extreme cases the liver-cells become fatty as well as pigmented, and exhibit multitudes of very minute oil-globules interspersed through their substance (Fig. 181 b).

The liver-cells may be affected injuriously by alterations in the composition of the blood, other than those due to its pollution with the products of its own disintegration; and the connective tissue which sheathes

and supports the vessels may likewise suffer from the same cause. Simple disturbances of the hepatic circulation, also, may of course lead to disorders of the nutrition of the liver.

Lastly, morbid changes of some danger may arise from disorders primarily affecting the biliary channels and ducts. The mere stoppage of the outflow from the common bile-duct may affect the liver seriously, and inflammation of the bile-ducts themselves are obviously still more dangerous (Art. 512).

CHAPTER LVI.

MALFORMATIONS AND MALPOSITIONS OF THE LIVER.

482. **Malformations** of the liver are not common and have little clinical importance. Absence of the organ is very rare, at least in fœtuses not otherwise gravely malformed. Abnormalities in the number of the lobes, either by excess or defect, are commoner. In a few cases accessory livers have been noted, in the form of small nodules seated in the suspensory ligament. Absence of the gall-bladder has been several times observed, as also cases of abnormal narrowness or width of the bile-ducts and abnormalities in the opening of the common duct into the intestine.

Of **congenital malpositions** the most notable are the misplacement of the liver on the left side instead of the right in *Situs transversus viscerum* (Art. 11), and protrusion of the organ into the thorax when the diaphragm is defective, or to the exterior when the abdominal wall is cleft.

Acquired deformities are very frequently the result of textural changes in the parenchyma of the organ (see under hepatitis Art. 497, syphilis Art. 499, cancer Art. 503), or of changes in the surrounding parts. Thus tight-lacing, by which the lower part of the thorax is violently compressed, gives rise to a characteristic deformity of the liver. The surface in contact with the lower ribs is indented and its fibrous capsule is white and thickened, while the liver-tissue beneath is atrophied or gone altogether (Art. 485). When the indentation is deep the right lobe is completely divided into a larger upper lobe and a smaller lower one; and in extreme cases the lower lobe becomes freely movable on the upper, and sometimes turns upwards as on a hinge.

The outer surface of the right lobe is frequently marked with shallow grooves corresponding to the ribs. The upper surface also often shows antero-posterior grooves or furrows. According to LIEBERMEISTER these are due to wrinkles or folds into which the liver is thrown when expiration is somehow obstructed and the lower ribs dragged inwards by the abdominal muscles. ZAHN (*Rev. méd. de la Suisse romande* 1881) refers them to the pressure exerted by the hypertrophied muscular bundles of the diaphragm in cases of obstructed inspiration, and speaks of them therefore as diaphragmatic grooves. ORTH (*Pathol. Diagnostik* I.) has seen them well marked in a seven months' fœtus, and thinks they are at least in some cases congenital.

Exemption from pressure over a circumscribed area may also tend to deform the liver. This occurs for example when the diaphragm is ruptured. If the patient survives and the opening remains patent, a conical plug of liver-substance gradually protrudes into the thorax.

Displacements of the liver are very common. It turns readily on its transverse axis, so that the level of the anterior edge varies greatly with the fulness of the abdominal cavity. Actual dislocations are much rarer than such rotations; but sometimes the liver sinks abnormally owing among other things to the elongation of the suspensory ligament. This condition (*hepar mobile* or floating liver) is most marked in cases of extreme dilatation of the stomach, where the abdominal wall is at the same time much relaxed. The liver is of course forced down if the diaphragm is depressed; as in pleural effusion or pneumothorax.

Wounds and ruptures of the liver from mechanical injury are highly dangerous, and often lead to fatal hæmorrhage. Small wounds may heal in the same manner as wounds of other tissues, by the formation of granulations and a cicatrix.

CHAPTER LVII.

DISORDERS OF THE HEPATIC CIRCULATION.

483. **Anæmia** of the liver is either secondary to general anæmia, or the result of local causes. Thus pressure on the liver from without, or swelling of the liver-cells, may diminish the amount of blood present in the capillaries. The anæmic tissue is pale, and yellow or brown according to the amount of bile-pigment and of fat present in the cells. It must not be forgotten however that the distribution of the blood in the liver may be notably altered after death by the coagulation of the liver-cells and the pressure exerted on the organ by the neighboring parts; and the tint may thereby be affected in a marked degree.

Congestive hyperæmia is a very common condition of the liver, and may be either physiological (as after a meal) or pathological, as in the early stages of inflammation or in affections which determine an increased afflux of blood to the intestine. If the congestion is great the volume of the liver may be much increased, and its tissue assumes a livid or brownish-red hue.

Passive hyperæmia or **venous engorgement** of the liver gives rise to very characteristic changes, especially when it has lasted for some time.

As the liver lies very near to the right heart, every obstruction to the circulation (whether due to changes in the cardiac valves or in the lungs) which produces 'back-pressure' in the right auricle and descending vena cava, makes itself felt in the hepatic veins. The most usual causes of such obstruction are tricuspid disease, emphysema or cirrhosis of the lungs, and mitral disease.

When the engorgement is of recent standing the liver appears enlarged and full of blood, while the central parts of the lobules are dark or livid. When it is more advanced the liver usually diminishes in size, and its surface is often uneven, granular, or somewhat irregularly knobbed. On section it has a characteristic nutmeg-appearance (hence it is called '**nutmeg-liver**'), the dark centre of each lobule contrasting strongly with the pale periphery. The centre of the lobule is dark-brown and usually sinks a little below the general surface of the section while the periphery (according to the amount of fat present) is pale-brown or yellow or even yellowish-white and projects slightly above the surface. When the change has gone still further the darker portions

gradually overcome the paler, and here and there coalesce into continuous patches of brown, while the lobules generally are notably diminished in size.

On microscopic examination the intralobular veins and the neighboring capillaries are seen to be dilated or varicose; in extreme cases the dilatation affects all the capillaries of the lobule. The liver-cells which lie between the dilated capillaries are always more or less atrophied, and generally beset with yellow or brown pigment-granules. Similar granules lie around in the walls of the intralobular veins. The degeneration of the liver-cells is most marked in the central parts of the lobules, and in extreme cases some of the cells may perish outright, leaving nothing but a few granules and flakes of pigmentary detritus between the dilated capillaries. The interlobular connective tissue is usually unaltered, but now and then it appears to be hyperplastic and infiltrated with small cells.

From its chief seat and its mode of origin this affection has been described as central red atrophy (VIRCHOW), and also as cyanotic or varicose atrophy or **atrophy from engorgement**. The liver itself is described in the post-mortem room as atrophic nutmeg-liver.

484. **Occlusion of the blood-vessels** of the liver, by thrombosis, embolism, portal endophlebitis (sometimes called pylephlebitis), or endarteritis, induces certain morbid changes that are worthy of mention.

Sudden closure of the portal vein causes the secretion of bile to cease; but if the vessel is gradually obstructed and at length occluded, the secretion goes on. The nutrition of the liver itself is not endangered by the closure of the portal vein or of some of its chief branches, for the blood-supply brought by the hepatic artery suffices to maintain it in good condition.

When the portal vein or its chief branches are gradually occluded, the arterial channels gradually widen and supply the liver with blood sufficient not merely for its own nutrition but also for its functional needs. Only the obstruction of the smallest of the interlobular (portal) venules, into some of which the arterioles pour their contents before these reach the lobular capillaries, need affect seriously the corresponding lobules; and that only because the arterial circulation of the lobules is thereby at some points interrupted or diminished as well as the portal circulation, and the liver-cells being completely starved of blood perish.

The closure even of some of the branches of the hepatic artery has seldom any grave consequences, inasmuch as the branches anastomose freely and collateral circulation is readily set up. Only in somewhat rare instances, where the blood-pressure within the liver or generally through the body is low, are the propelling forces behind the point of obstruction insufficient to maintain the flow. In such a case the affected region may become engorged by reflux from the veins, and the blood escaping from the ill-nourished capillaries may give rise to **hæmorrhagic**

infiltration. Such an infiltration is however seldom so intense as to obscure altogether the outlines of the lobules. When the supply of arterial blood is entirely cut off, the liver-cells perish by necrosis (COHNHEIM and LITTEN, *Virch. Arch.* vol. 77). Hæmorrhage may likewise take place in consequence of changes in the vessel-walls (as in hæmorrhagic purpura, and in phosphorus-poisoning), or of obstruction (*e.g.* by thrombosis) of the hepatic veins.

CHAPTER LVIII.

ATROPHY AND DEGENERATION OF THE LIVER.

485. **Simple atrophy.** Starvation which has been rapidly fatal, and grave chronic disorders of nutrition of long standing, may equally induce extreme atrophy of the liver. The experiments of BIDDER, SCHMIDT, and VOIT have shown that in dogs and cats starvation may reduce the volume of the liver by two-thirds. The diminution is chiefly due to the dwindling of the liver-cells. In emaciated or marasmic patients, whether the wasting is due to senile decay or to organic disease, the liver is usually greatly diminished in size, and in some cases occupies only one-third of its original volume.

The atrophy is seldom uniform, the margins of the organ being usually the most wasted. The anterior margin of the right lobe and the whole margin of the left are often very markedly shrunken. In extreme cases the parts just mentioned, as well as other regions (notably along the line of the suspensory ligament), may be altogether devoid of liver-cells.

The atrophy in these cases is primarily due to loss of the liver-cells, which become steadily smaller (Fig. 183 *A*) and at length vanish outright. The trabeculæ and lobules dwindle, and the interlobular or portal sheaths of connective tissue (Fig. 182 *d*) approach each other. When the lobules have entirely disappeared, the meshes enclosed by the portal sheaths enclose mere shreds of loose fibrous tissue (*e*) composed of little else than collapsed capillaries. The bile-ducts within the portal sheaths (*f*) persist however, and in some parts seem even increased in number; at any rate a section through the interlobular structures often shows that at certain points whole clusters and groups of bile-ducts have been cut across (*f*).

The atrophic tissue is usually poor in cells; but if any obstruction to the outflow of bile has taken place, signs of inflammation and cellular infiltration may be seen (Art. 496).

The wasted borders of the lobes may be reduced to mere membranes, and look like thickenings of the serous coat. As the right lobe shrinks the gall-bladder is uncovered, and sometimes projects far beyond the wasted border.

Where the liver-substance still persists the remaining lobules are usually small, and often abnormally brown in color. This is due to the

fact that some of the liver cells are beset with pigment-granules (Fig. 183 A).

486. **Pigmentary atrophy.** The atrophy just considered (Art. 485) is a general affection extending over the whole of the liver, and depending on impairment of its nutrition. Localized atrophy affecting a few cells or lobules is a very common condition, and may be induced by a great variety of causes. Thus we have seen that long-standing venous engorgement of the liver constantly leads to atrophy of the central parts

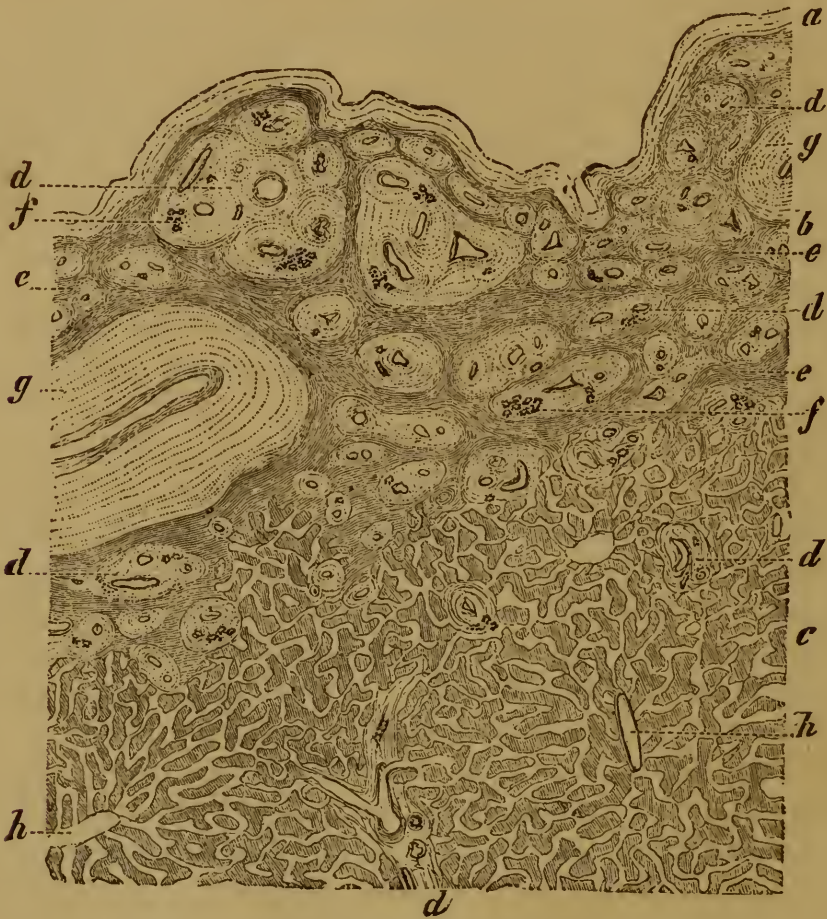


FIG. 182. SECTION FROM THE MARGIN OF A GREATLY ATROPHIED LIVER.

(Carminic staining: $\times 30$.)

- | | |
|---|---|
| a, serous membrane. | e, loose fibrous tissue taking the place of the lost liver-substance. |
| b, completely atrophied region. | f, bile-ducts. |
| c, normal lobules. | g, larger portal veins. |
| d, portal sheaths enclosing blood-vessels and bile-ducts f. | h, intralobular veins. |

of the lobules (Art. 483). So also where the fibrous framework of the organ becomes hypertrophied, as in indurative hepatitis (Art. 497), the liver-cells are usually compressed and atrophied. Mechanical pressure from without or within may have the like effect. The latter is observed in the neighborhood of tumors and other new-formations growing in the liver; amyloid disease (Art. 491) affords a good example. The liver-cells

are usually deformed and flattened (Fig. 183 *B*), or drawn out into long spindles.

The atrophied cells are usually beset with brown and yellow pigment-granules. These are probably due not so much to re-absorption of bile already elaborated and excreted as to some disturbance of the process of secretion itself. The ill-nourished cells are unable to perform their normal bile-producing function, and as the colored iron-compounds are no longer adequately separated and excreted, they perforce remain in the cells. In certain cases, however, the cause of the pigmentation may lie in some increase in the normal disintegration of the red corpuscles (Art. 81).

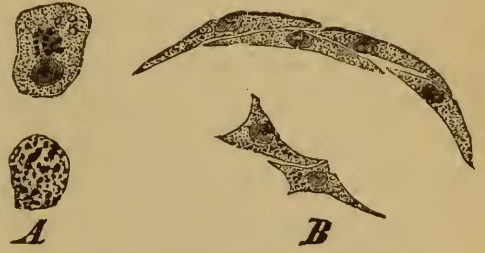


FIG. 183. ATROPHIED LIVER-CELLS
($\times 250$).

- A, simple atrophy with pigmentary deposits.
- B, liver-cells atrophied by compression.

487. Fatty infiltration. The liver in health always contains a certain amount of fat, which lies in the liver cells in the form of large and small globules (Fig. 184 *a b c*). This fat is partly brought to the liver ready-formed and there deposited, and partly elaborated from albuminoid substances *in situ*. The former fat is either derived directly from the food, or has been elaborated from albuminoids in some other part of the body.

In morbid conditions the fat contained in the liver may be enormously increased; the increase depending either on increased production or supply, or on diminished consumption, or on both.

When fat accumulates as a deposit in the liver, from increased supply or decreased consumption, we have what is called simply **fatty liver**, or fatty infiltration. When the accumulation is great the liver is large, and *post-mortem* feels firm to the touch, holds little blood, and has a uniform opaque pale-yellow tint. The individual lobules are somewhat enlarged.

When the quantity of fat present is not so great, it lodges chiefly in the peripheral parts of the lobules. These parts consequently look pale, while the central parts are brown or reddish; and the mottled appearance thus produced has led some to describe this variety as fatty nutmeg liver. If the fat be still less abundant the general brownish color of the lobule prevails.

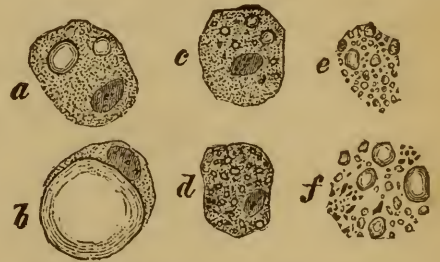


FIG. 184. FATTY LIVER-CELLS ($\times 400$).

- a, c*, cells with several oil-globules.
- b*, cell with one large drop.
- d*, cells with many minute globules.
- e, f*, cells completely disintegrated into fatty detritus.

Fatty livers are met with most commonly in corpulent patients; but they are not rare in cases of lung-disease associated with much ema-

ciation. In the latter we must suppose that the accumulation is due to defective consumption of the fat.

The fat usually takes the form of large drops which distend the cells (Fig. 184 *b*); though at first it is deposited in smaller globules (*a c*). As the fat is re-absorbed the large drops break up again into smaller ones.

488. When the disintegration of albumen within the liver becomes excessive, while the supply of albumen is not sufficiently maintained, the process assumes a degenerative character and is described as **fatty degeneration**. In slight cases the liver-cells are more or less thickly beset with oil-globules (Fig. 181 *b*), but are otherwise little changed; where the degeneration is advanced the cells break down altogether (Fig. 184 *f*).

Simple uncomplicated fatty degeneration is well observed in extreme anæmic conditions, such as that known as pernicious anæmia. Here the process is characterized throughout by the formation of very minute oil-globules, and is often accompanied by pigmentary infiltration.

Fatty degeneration frequently sets in with **cloudy swelling** (Art. 48) of the cells, which enlarge and become turbid and granular. The liver as a whole thereupon assumes a muddy grayish or grayish-yellow tint, and sometimes looks as if boiled. This stage of the degeneration is met with in many forms of infective disease, such as typhoid, relapsing fever, small-pox, scarlatina, septicæmia, erysipelas, yellow fever, etc., and in poisoning by antimony, arsenic, sulphuric ether, and phosphorus.

In most cases the turbidity and swelling disappear and the cells recover their normal aspect. In other cases the process passes into fatty degeneration and disintegration of the affected cells. These changes are most marked in phosphorus-poisoning and in acute yellow atrophy.

489. **Acute yellow atrophy**. The affection so named is characterized by a great and sudden diminution of the size of the liver. Within a few weeks or it may be days the liver loses as much as half its bulk. The shrunken organ is remarkably flaccid and soft, and here and there may even give the feeling of fluctuation. Sometimes however it is firmer, the surface being smooth or wrinkled in different cases.

The section is usually of an ochreous yellow, and the contours of the lobules are obscured. Or the yellow tint may appear only in some spots, while others are pale or dark red (so-called 'red atrophy'). The single lobules are uniform in color, or now and then show variously tinted zones. In the latter case the periphery is grayish and semi-translucent, while the central parts are of various shades of yellow, and now and then the very centre is red. The differences in size, consistence, and color are due partly to differences in the condition of the liver-cells, partly to the amount of blood present in the vessels.

As regards the liver-cells, they are found in the most diverse stages of degeneration, from mere dropsical and cloudy swelling to complete disintegration into masses of fatty and albuminous detritus. At the

same time the cohesion of the several cells is loosened. In the ochreous parts few if any cells remain unaltered. Those that are least altered are turbid and beset with granules and oil-globules; the most altered consist of little else than drops of oil of various sizes, while many are completely broken up or in process of solution (Fig. 184 *e f*). In the grayish semi-translucent parts a few normal cells remain, but the greater number are disintegrated and replaced by irregular clumps of colorless albuminous granules, grains of yellow pigment, and small and large drops of oil. At many points even these remains of cells have disappeared and the intercapillary spaces contain nothing but liquid. The detritus has been partly dissolved and partly removed by the lymphatics.

The amount of blood present in the vessels varies much: when present it gives to some parts the red tint to which we have alluded. What is called 'acute red atrophy' is in fact 'yellow atrophy' associated with a more than usually abundant supply of blood to the parts. Naturally the red appearance becomes more appreciable as the fatty detritus of the disintegrated tissue is dissolved away or otherwise removed. The brown or darker yellow tints are due to pigment-granules which lie in the tissues that remain.

In the later stages of the affection the periportal connective tissue is slightly infiltrated with lymphoid cells or leucocytes; in the earlier stages these are absent. When the process is still more advanced leucin and tyrosin accompany the oily deposits, or at least become apparent some hours after death.

490. Acute yellow atrophy is thus characterized texturally by a fatty degeneration of the liver depending on a rapid disintegration of the albuminoid constituents of the liver-cells. The ætiology of the process is not always the same. In a few cases it is an accompaniment of recognized infective disorders, especially of traumatic septicæmia. In other cases its causes are unknown, and then it would seem to be an idiopathic or at least a primary affection. Probably in these cases also it is due to some kind of microparasitic infection. In support of this view it is to be noted that KLEBS has on several occasions discovered micrococci crowding the hepatic vessels in cases of acute yellow atrophy unaccounted for by the presence of any other source of infection.

But apart from causes of the nature of infection, it is known that certain poisons, notably phosphorus, may give rise to degenerative changes closely resembling those we have just described. In **phosphorus-poisoning** we may have various degrees of change, from mere turbidity of some of the liver-cells and the formation of a few oil-globules to extreme and extensive fatty disintegration of the liver-substance generally. In a few days after a poisonous dose of phosphorus has been taken the greater part of the liver may be broken down into fatty detritus. The changes begin in from six to twenty-four hours, and first appear round the periphery of the lobules. The cells become turbid and swollen, then

oil-globules appear which as a rule soon run together into larger drops as the cell disintegrates.

The color of the liver in phosphorus-poisoning is grayish-yellow or yellow, and the organ feels greasy and doughy. In the early stages, that is before the liver-cells are entirely disintegrated and before their remains are absorbed, the liver is enlarged. Sometimes small hæmorrhages take place into the tissue. When these are confined to the portal areas peculiar rosette-like figures are produced by the extravasated blood. Now and then the liver looks as if bile-stained. As the degeneration advances the secretion of bile is more or less interfered with. In the later stages leucin and tyrosin are deposited, as in acute yellow atrophy.

After a time the tissue of the atrophied liver is seen to contain clusters and more and less cylindrical groups of large epithelial cells. These are considered to be gland-cells, and to indicate the beginning of a process of regeneration and repair. Some observers regard them as derived from the epithelium of the bile-ducts, others from the surviving liver-cells. The author's observations incline him to support the latter view; he believes that the surviving liver-cells may have the power to multiply and build up new liver-tissue. The longitudinal groups or cylinders sometimes include large cells with abundant protoplasm and very large nuclei (occasionally of double the normal size); and these at least would appear to be proliferous cells.

COHNHEIM (*Allg. Path.* II. Berlin 1882) and others distinguish the affection known as *icterus gravis* or **malignant jaundice** from acute yellow atrophy of the liver. The former is marked by complete suppression of the biliary secretion and by intense jaundice; both of these systems may be absent in typical cases of the latter.

References on acute yellow atrophy: FRERICHS, *Diseases of the liver* II. (trans. by MURCHISON, New Syd. Soc.) London 1862; KLEBS, *Handb. d. path. Anat.* I. Berlin 1869; ZENKER, *Deutsch. Arch. f. klin. Med.* X. (1872); VON WINIWARTER, *Wiener med. Jahrb.* 1872, LEWITZKY and BRODOWSKY, *Virch. Arch.* vol. 70; AFANASIEW, *Pflüger's Archiv* XXX.; MOXON, *Trans. Path. Soc.* XXIII. (1872); THIERFELDER, *Atlas d. path. Hist.* part 3, 1874, *Ziemssen's Cyclop.* IX., with full references; MURCHISON, *Diseases of the liver* London 1877; BIRCH-HIRSCHFELD, *Gerhardt's Handb. d. Kinderkr.* IV. Tübingen 1880; ZUNDER, *Virch. Arch.* vol. 59; LEGG, *Bilious Diseases* London 1880, with a very complete summary of the literature; HLAVA, *Prager med. Woch.* 1882; SALKOWSKI, *Virch. Arch.* vol. 88; NOMAN, *ibid.* vol. 91; GOODHART, *Atlas of Path.* (New Syd. Soc.) London 1883.

On the micro-organisms associated with the affection see WALDEYER (*Virch. Arch.* vol. 43), KLEBS and EPPINGER (*Prager Vierteljahrsschrift* 125, 1875), DRESCHFELD (*Brit. med. Journ.* 2, 1883).

On the liver in phosphorus-poisoning see LEYDEN and MUNK (*Die acute Phosphorvergiftung* Berlin 1865), KLEBS (*loc. cit.*), WEYL (*Arch. d. Heilk.* XIX.), LEBERT and WYSS (*Arch. gén. de méd.* 1868), SCHULTZEN and REISS (*Charité-Annalen* 1869), FRAENKEL (*Berl. klin. Woch.* 19, 1878), ERMAN (*Viertelj. f. gericht. Med.* XXXIII.), BINZ and SCHULZ (*Cent. f. d. med. Wiss.* 1879), CORNIL and BRAULT (*Journ. de l'anat. et de la phsiol.* 1882), WEGNER (*Virch. Arch.* vol. 59), VOIT and BAUER (*Journ. Chimical Soc.* XXIV.), LEGG (*Bilious diseases* London 1880),

OSSI KOVSZKY (*Wien. med. Wochenschrift* 31, 1881), THIERFELDER and NAUNYN (*Ziemssen's Cyclop.* IX., XVII., with references), TAYLOR (*Medical Jurisprudence* I. London 1883).

491. Amyloid degeneration. Amyloid change affects chiefly the lobular systems of blood-vessels. At first the capillaries of the lobules exhibit at various spots a kind of hyaline thickening or deposit in the endothelium; but as the change progresses they become completely enveloped by continuous hyaline masses (Fig. 185).

The liver-cells are usually passive throughout the process, or at least they rarely become amyloid themselves. In the early stages they are quite unaltered, but as the amyloid deposits around them increase in bulk they become compressed and generally atrophied. In advanced stages they here and there perish outright, or it may be that to some extent amyloid deposits take place in them. Where they persist they nearly always contain large or small globules of fat.

Amyloid change also, though to a less degree, affects the interlobular blood-vessels. In the case of the arteries the middle coat is the most affected.

The change usually extends over the whole of the liver, and when it is well-marked the section becomes pale grayish-brown or grayish-yellow in color, and it has a semi-translucent appearance like the fat of boiled bacon. The semi-translucent patches are chiefly found in the intermediate zone of the lobule, the neighborhood of the central or intralobular vein on the one hand and of the portal vein on the other being comparatively free from deposit. In other instances however there seems to be no special arrangement of the amyloid patches. Iodine gives the characteristic brown color, and methyl-aniline a pale ruby tint (Art. 58).

The unaltered tissue varies in appearance in different cases. When the liver-cells contain no fat, they are usually of a brown or reddish-brown color. The presence of fat makes them look yellowish-white.

Well-marked amyloid change is always associated with enlargement of the liver. The edges are thickened and rounded and the surface is smooth, but the serous covering is free from thickening. The tissue becomes firmer and much more elastic. The amount of blood contained in it varies but is generally small, at least in the more degenerate portions.

General amyloid disease of the liver occurs chiefly in connection with cachectic conditions, such as those depending on tuberculosis, chronic suppuration, syphilis, etc. Other organs are simultaneously affected in a similar manner, especially the spleen, intestine, and kidneys.

The liver may at the same time be diseased in other ways; thus in

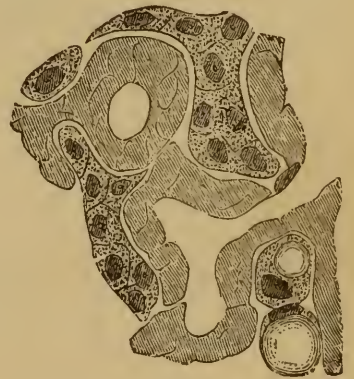

FIG. 185.—AMYLOID LOBULAR CAPILLARIES.

(Treated with *perosmic acid*:
× 300.)

tuberculosis it may contain tubercles, and in syphilis it may exhibit the characteristic hyperplasia of the periportal connective tissue (Art. 499) or gummatous foci in various stages.

Circumscribed amyloid change of the liver, limited to one or more spots, is much less common than the uniformly diffused or general affection; but it is occasionally met with. Cases are recorded in which the amyloid substance was aggregated into nodes or nodules, or confined to a few isolated blood-vessels. The latter is especially the case in the vessels of cicatricial tissue developed in consequence of syphilitic inflammation.

References:—Arts. 58, 59; WILKS, *Guy's Hosp. Rep.* 1856; WAGNER, *Arch. d. Heilk.* II. (1861); CORNIL, *Arch. de physiol. norm. et path.* II. (1875); HESCHL, *Wiener Sitzungsber.* LXXIV. (1876); SCHÜPPEL, *Ziemssen's Cyclop.* IX.; BÖTTCHER, *Virch. Arch.* vol. 72; SCHÜTTE, *Die amyloide Degen. d. Leber* In. Diss. Bonn 1877, with good figures.

CHAPTER LIX.

HYPERTROPHY AND REGENERATION OF LIVER-TISSUE.

492. When from any cause the glandular cells of the liver are destroyed, as in phosphorus-poisoning, the tissue may to a certain extent be repaired or renewed by regenerative multiplication of the remaining cells. How far the process of regeneration can go we do not as yet fully know; but we may well suppose that it is possible only when the loss of substance is small and the general structure of the lobule not gravely damaged. We suggested in Art. 490 that the process of regeneration starts from the liver-cells within the injured lobule, and it certainly seems highly improbable that an entire lobule or any part of one should be developed from the epithelium of the biliary ducts.

As to the histology of hypertrophy of the liver-tissue there is but little to say.

Enlargement of the liver is chiefly due to deposits of fat or of amyloid substance, to new-formed fibrous tissue, or to infiltration with leucocytes (as in leukæmia). In a few cases the enlargement of the liver has been found to be congenital, the structure being normal. Ricketty children not infrequently have remarkably large livers (BENEKE). And in adults abnormal size of the liver is now and then discovered, without any assignable cause for the enlargement. Inasmuch as the volume of the organ may vary in health within somewhat wide limits, it is difficult to say at what point an enlargement is to be regarded as morbid. The statement sometimes made—that the liver in diabetes is apt to be very much enlarged—cannot be corroborated by the author.

The lobules of an abnormally large liver are not usually enlarged, and hence one must assume that their number is increased. As regards the size of the liver-cells, it is known that this varies under physiological conditions; it is therefore difficult or impossible to detect what we may call cellular hypertrophy, if it exists. Sometimes when one part of the liver-substance perishes the remainder seems to enlarge; but on closer examination the local hypertrophy is seen to be more apparent than real, the appearance being mainly due to contraction, compression, and displacement of the several parts.

Circumscribed hypertrophies or hyperplasias of the liver-tissue do however occur in the form of nodules or larger nodes (FRIEDREICH, *Virch. Arch.* vol. 33; HOFFMANN, *ibid.* vol. 39; EBERTH, *ibid.* vol. 43).

These protuberant overgrowths consist of liver-tissue, the cells of which are abnormally large and arranged in somewhat irregular groups or trabeculæ.

References: TIZZONI, *Atti della r. acad. dei Lincei* 1883, *Arch. ital. de biol.* III. (1883); COLUCCI, *ibid.*, *Studj sull' anat. patol. d. fegato* Bologna 1883. These authors assert that in the lower animals at least wounds of the liver are partly repaired by new-formations of liver-tissue, and that these new formations may reach a considerable size.

CHAPTER LX.

INFLAMMATIONS OF THE LIVER.

Purulent hepatitis and Hepatic abscess.

493. **Purulent inflammation of the liver** depends on the invasion of the organ by some noxious or irritant body derived either from the exterior or from some other part of the system.

The information we now possess concerning the genesis of the suppurative process justifies us in believing that as a rule this irritant is a bacterium or is produced by the agency of bacteria. Only in very peculiar and unlikely conditions can any other agent (such as the *Actinomyces*) give rise to suppuration within the liver.

The avenues by which micro-organisms may enter the liver are numerous. They may enter directly from without in the case of a perforating wound of the liver through the belly-wall, and cause the wound to suppurate. A purulent inflammation of any of the neighboring organs or tissues may extend to the liver by continuity, or through the channel of the lymphatics. More commonly however the micro-organisms reach the liver through the blood. The portal vein is the most frequent channel, though the hepatic artery may also convey infection. Rarely, and only in very exceptional circumstances, can anything of the kind pass with the venous blood from the vena cava into the hepatic veins. Lastly, in infants the patent umbilical vein may convey infection to the liver.

Infection of the liver by these channels is commonly secondary; that is, it depends upon a preceding lodgment of bacteria somewhere within the territory supplied by the blood-vessels in question. Thus abscess of the liver is not infrequently the result of purulent inflammation (dysentery) of the intestine, infection being conveyed by the portal vein; or it may follow upon a suppurating wound of the head for example, the channel of infection being the hepatic artery. In the latter case the virulent material must have passed through the lungs, and may there also give rise to secondary suppuration.

Primary suppuration within the liver, that is to say suppuration unaccounted for by the existence of some focus of infection elsewhere in the body, is rare in temperate climates. In the torrid zone hepatic abscess ('**tropical abscess**') is a very common affection, and it is frequently impossible to detect a source of infection in any other organ or

part. In a large number of cases however the hepatic abscess is preceded by dysenteric disease of the bowel.

There is still another avenue by which an irritant capable of exciting inflammation may reach the liver, namely the common bile-duct. When the biliary channels are somehow diseased so that bile is retained and stagnates within them, concretions may be formed, and these appear to favor the entrance of noxious matters into the liver.

494. When a bacterium (such as the micrococcus of pyæmia, Art. 204) capable of giving rise to inflammatory change enters the liver through the blood, it lodges first in the capillaries (Figs. 186, 187 *c*) and afterwards in the smaller venules. Then it forms colonies or zooglœa, which presently fill up and it may be distend the vessels. After a short time the liver-cells become turbid and swollen, they lose their nuclei, and soon break up into fragments of various sizes (Fig. 186).

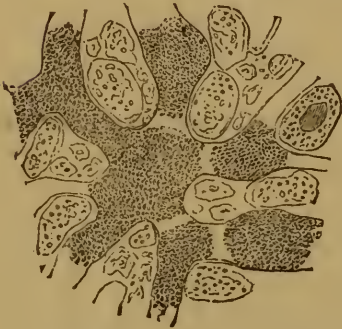

FIG. 186. *MICROCOCCUS SEPTICUS* IN HEPATIC CAPILLARIES.

(Forming zooglœa: aniline-brown staining: $\times 350$.)

As the colonies multiply they spread more and more widely through the vessels, so that soon a great number of affected lobules have their capillaries (Fig. 187 *c*), and often their intralobular veins (*c e*), crammed with bacteria.

The necrosis of the liver-cells (*b*) advances steadily with the advance of the invasion.

These changes are accompanied by intense inflammation of the interlobular tissue (*d*) and the veins (*e*), which gives rise to an abundant cellular infiltration of the tissue around. This is the first stage in the formation of an abscess. Soon the infiltration of cells and exuded liquid becomes more marked, and the necrotic cells break up and liquefy. A collection of pus is thus produced, and a **hepatic abscess** is formed.

This is in brief the course of the process; but of course it may be modified in numerous ways. Thus the micrococci may settle in the connective tissues, or a number of lobules may be simultaneously affected and break down, and so on. Abscesses starting in wounds or in the bile-ducts (Art. 512) will naturally exhibit peculiarities of their own. In the latter case, for instance, the irritant matters will first affect the walls of the ducts and their surroundings, and set up inflammation there.

495. The appearance presented by a hepatic abscess varies with its mode of origin and its age.

When infection is conveyed by the blood-vessels the affected lobules look gray or grayish-yellow. Then the parts that are on the point of suppurating become yellow or yellowish-white, and presently the whole of the affected patch breaks down into dirty yellowish pus, either liquid throughout or mingled with discolored shreds of necrotic tissue. The

surrounding parts are discolored, infiltrated with pus, and in process of liquefaction. The abscesses may be single or multiple. The remaining parts of the liver show a greater or less degree of turbid swelling, sometimes accompanied by extravasations of blood which become slaty-gray in color when putrefaction sets in.

In abscess from a suppurating wound of the liver some traces of the original injury are usually to be seen. In biliary abscess (if we may so

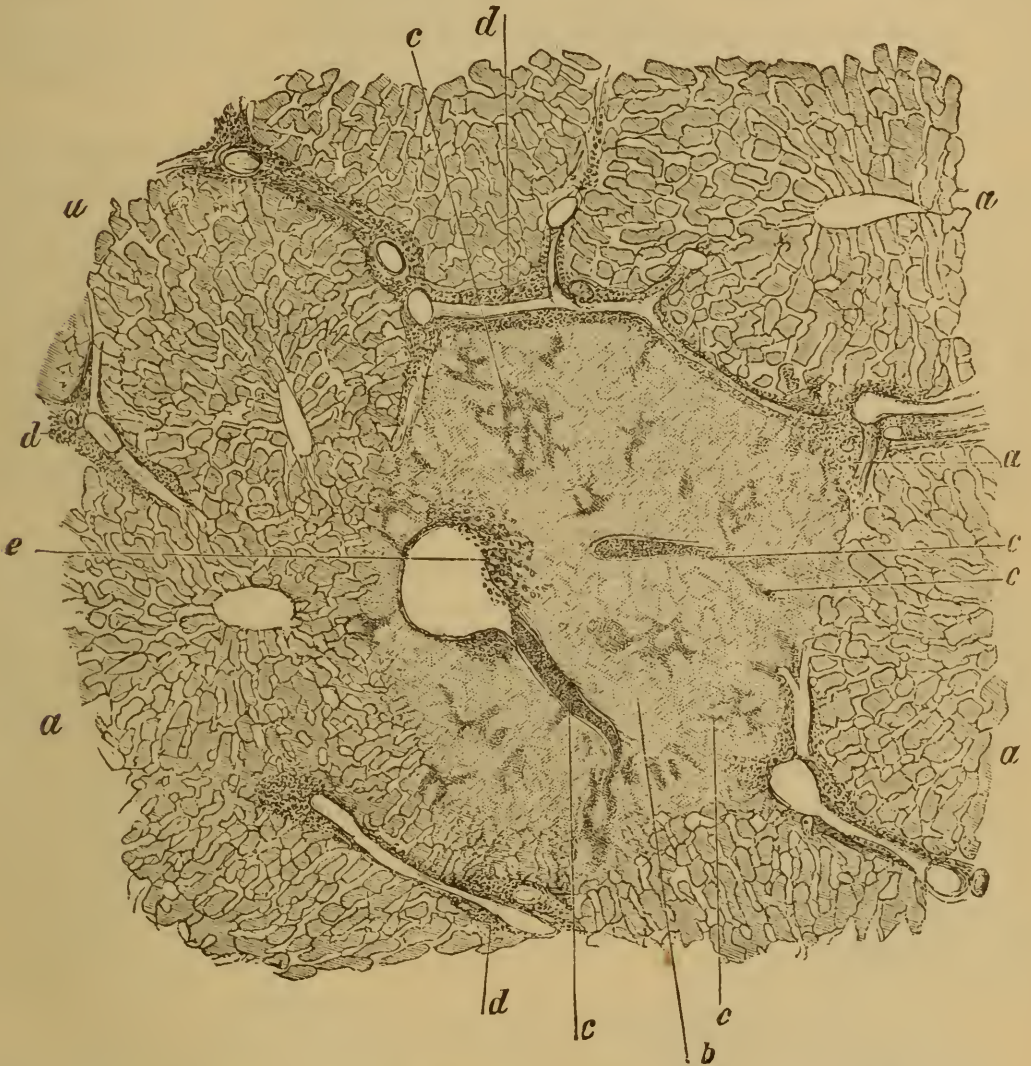


FIG. 187. HEPATIC ABSCESS: FIRST STAGE. (*Bismark-brown staining: $\times 40$.*)

a, normal lobules.

b, necrosed lobules.

c, capillaries and venules filled with micrococci.

d, small-celled infiltration of the interlobular tissue.

e, aggregation of small-round cells in a vein, into which opens an intralobular venule crammed with micrococci.

describe it) the pus is mingled with bile or with biliary concretions. When the abscess lies immediately beneath the serous membrane the latter is more or less intensely inflamed.

The size of hepatic abscesses varies; it may extend to almost an en-

tire lobe. Minute multiple abscesses sometimes coalesce into larger ones.

In very many cases abscess of the liver, or the injury to which it is secondary, brings about the death of the patient. But when death does not take place, granulation-tissue is developed around the abscess-cavity and forms for the rest of the tissue a kind of protecting membrane. Small abscesses may disappear, their contents being entirely absorbed; and a scar varying in size with the size of the abscess is left. Larger abscesses may become notably contracted by absorption and inspissation of the pus. The inspissated pus is always enclosed by a tough and thickened fibrous wall, and sometimes becomes calcified.

Abscesses frequently break into surrounding parts. This issue is the most favorable when adhesions have been set up between the liver and the wall of the abdomen or of the intestine, and the pus is then evacuated through the adherent parts to the outside of the body or into the bowel. Even rupture through the diaphragm into a bronchus is not entirely unfavorable; but rupture into the cavity of the pleura, pericardium, or peritoneum, is highly dangerous. General inflammation of the corresponding serous membrane is the result, unless the previous adhesions between the liver and other viscera are such as to limit the extension of the inflammatory process.

References:—FRERICHS, *Klinik d. Leberkrankheiten, Diseases of the liver* II. London 1862; VIRCHOW, *Virch. Arch.* vol. 4; TRAUBE, *Gesam. Abhandl.* II.; ROUIS, *Rech. sur les suppurations endém. du foie* Paris 1860; BAMBERGER, *Virchow's Handb. d. spec. Path.* 1864; BÜCKLING, 36 *Fälle v. Leberabscess* In. Diss. Berlin 1868; KLEBS, *Handb. d. Path. Anat.* II.; ACKERMANN, *Virch. Arch.* vol. 45; HEINEMANN, *ibid.* vol. 58; THIERFELDER, *Atlas d. path. Hist.* plate xv. *Ziemszen's Cyclop.* IX., with full references to the older papers; MCCONNELL, *Indian annals of med. sci.* 1873; many papers by MURCHISON, BRISTOWE, QUAIN, and others in the earlier vols. of the *Trans. Path. Soc.*; MURCHISON, *Diseases of the liver* London 1877; LEBERT, *Arch. f. klin. Med.* VI.; BIRCH-HIRSCHFELD, *Arch. f. Heilk.* XIV.; HIRSCH, *Handb. d. histor.-geog. Path.* II. (trans. by CREIGHTON, New. Syd. Soc.).

Chronic indurative hepatitis and Cirrhosis.

496. **Diffuse chronic indurative hepatitis**, like purulent hepatitis, depends on noxious influences which reach the liver by various channels. Of these channels the blood-vessels are the chief, though the bile-ducts also are very often at fault; in other words the disease is most frequently hæmatogenous, though instances of what we may call biliary hepatitis are by no means uncommon. As to the exact nature of the noxious influences or agents we know little. It is possible that in many or in most cases irritant matters absorbed from the alimentary canal are especially concerned. By many authorities alcohol is considered to be one of the most important of the exciting factors. In other cases syphilis is admittedly the cause.

Indurative inflammation of the liver is always a chronic and at the same time a very gradual and insidious affection. It is rare for an acute hepatitis to pass into a chronic one of this type.

The first stages of the affection are marked by the presence of a more or less obvious infiltration of the liver-tissue with leucocytes.

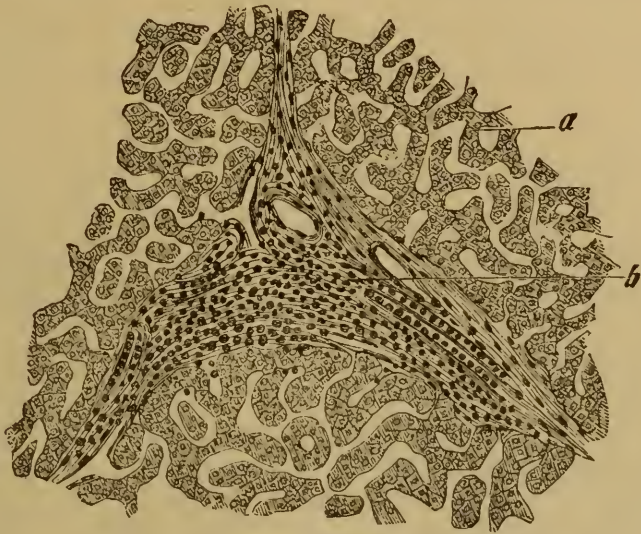

FIG. 188. RECENT INTERSTITIAL HEPATITIS.

(*Hæmatoxylin staining*: $\times 80$.)

a, normal liver-tissue.

b interlobular connective tissue infiltrated with leucocytes.

The infiltration is chiefly seen in the interlobular connective tissue (Fig. 188 *b*), and thence extends into the lobules. The infiltration is usually at first in the form of disconnected patches of various sizes. Less commonly it is uniformly diffused.

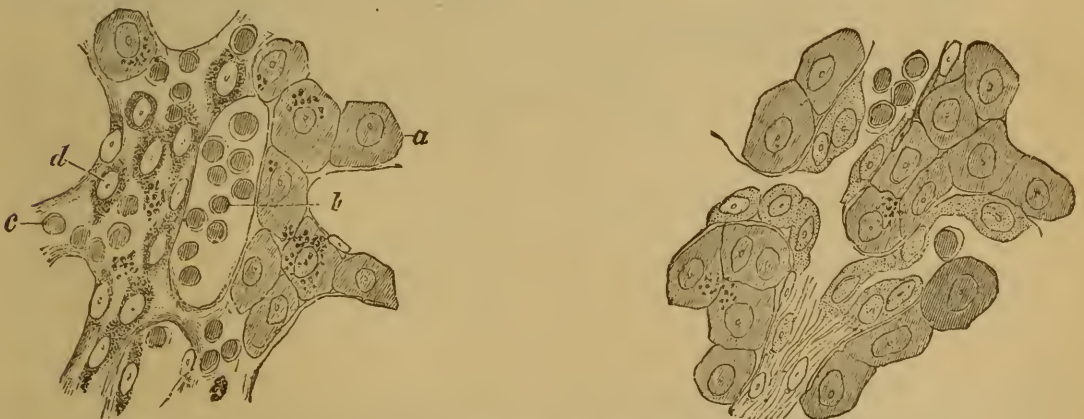


FIG. 189. EXTRAVASCULAR DEVELOPMENT OF NEW FIBROUS TISSUE IN THE LIVER.

(*Carmine staining*: $\times 300$.)

a, normal liver-cells.

b, accumulation of leucocytes within a capillary.

c, leucocytes in the place of the liver-cells.

d, formative cells or fibroblasts.

FIG. 190. INTRAVASCULAR DEVELOPMENT OF NEW FIBROUS TISSUE IN THE LIVER.

Fibroblasts and small leucocytes are seen lying within the capillaries.

From the extravasated cells new fibrous tissue is gradually elaborated by the development of fibroblasts, that is to say of large cells with clear

vesicular nuclei (Fig. 189 *d*). When the process extends to the lobules leucocytes accumulate within the lobular capillaries (Fig. 189 *b* and Fig. 190), and from them are developed fibroblasts (Fig. 190) and ultimately fibrous tissue.

The growth of fibrous tissue may be extravascular as well as intravascular, leucocytes and fibroblasts appearing between and among the liver-cells (Fig. 189 *c*) and presently compressing or displacing them. A certain number of the liver-cells consequently become atrophied and per-

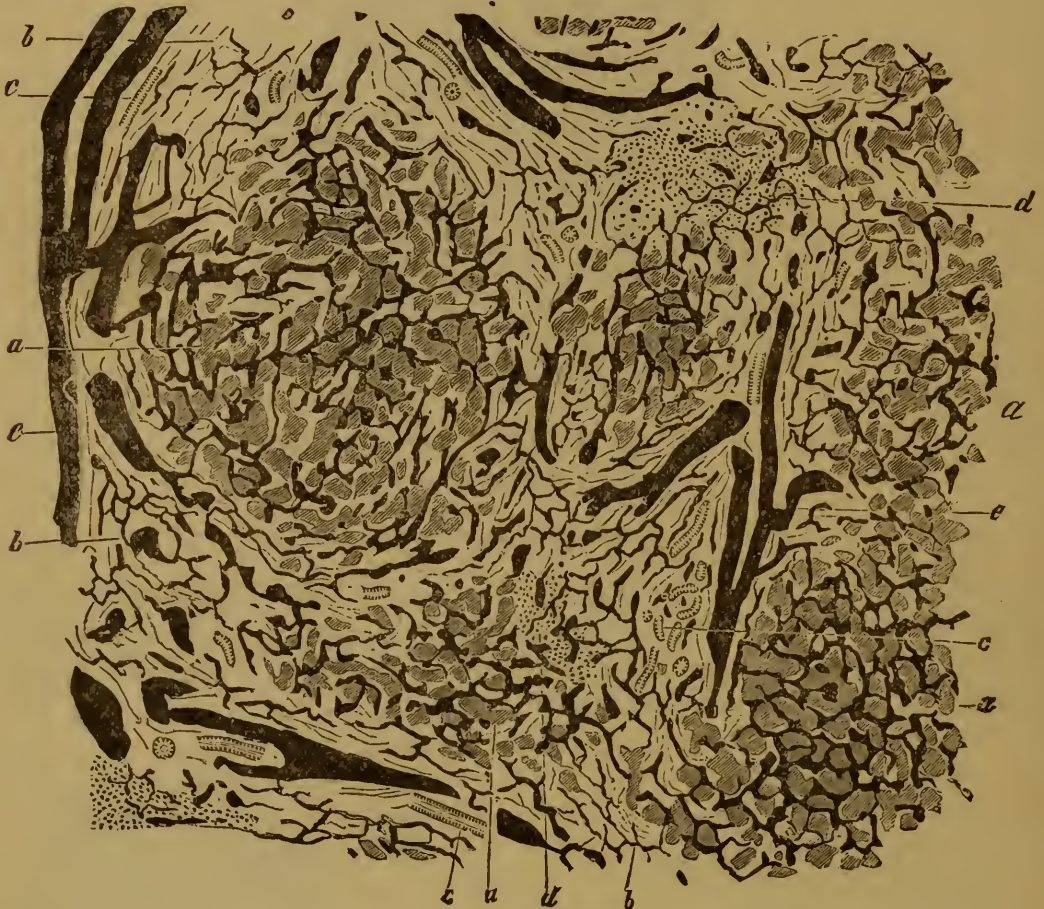


FIG. 191. GRANULAR ATROPHIC CIRRHOSIS OF THE LIVER.

(Arteries injected; carmine staining: $\times 25$.)

a, remains of normal lobule.
b, new-formed fibrous tissue.
c, bile-ducts.

d, infiltration of leucocytes.
e, interlobular (portal) veins.

ish. In some cases this atrophy by compression is very considerable, in other cases the cells persist in a remarkable way.

As a result of the destruction of liver-cells, which perish by fatty degeneration as well as by simple atrophy, deposits of yellow and brown pigment appear in the affected tissue. Part of this is derived from the coloring-matter of the blood, in consequence of the interference with the secretion of bile; part is probably derived from bile actually secreted, but retained in consequence of the blocking of the bile-channels. The new-formed fibrous tissue is frequently infiltrated with bile-pigment.

The bile-ducts are seldom greatly obstructed, or diminished either in size or number. Indeed in some forms of hepatitis they appear to be multiplied.

497. When indurative hepatitis has lasted for some weeks or months the connective tissues of the liver always exhibit a more or less marked hyperplasia.

This is chiefly shown in the fibrous portal sheaths (Fig. 191 *b*) which appear broadened and thickened. In some cases the fibrous overgrowth is almost entirely confined to the interlobular structures; but it often extends to the lobules, creeping along the lobular capillaries and intruding itself between the columns of liver-cells (*a*). In this way many groups of liver-cells become surrounded, and appear in the midst of the overgrown fibrous tissue; they are thus more or less separated and cut off from their capillaries. The result is that some of them perish, while others which survive give rise to clusters and strings of cells looking very like bile-ducts; these have indeed been regarded by some as new-formed bile-ducts. This view is certainly not correct, though the strings of cells do in fact act as channels for the bile between the isolated remnants of liver-tissue and the true bile-ducts. The latter are unaffected by the other changes in the organ and in some cases may actually be increased in number. ACKERMANN succeeded in injecting the new-formed channels from the hepatic duct. It is however to be noted that the multiplication is often only apparent. The ducts which enter the lobules, and they do so to a greater depth than the descriptions in the histological text-books would imply, are normally concealed by the overlying liver-cells; and as these latter shrink or disappear the ducts become much more distinctly visible.

The hyperplastic connective tissue when fully developed is dense and fibrous; it usually contains but few cells, though in parts the extravasated cells still remain (Fig. 191 *d* and Fig. 192 *c*) as evidence of the inflammatory infiltration. Sometimes indeed they are so abundant that the new fibrous tissue looks as if it were itself infiltrated.

The interlobular fibrous tissue is usually highly vascular. A certain portion of the portal vascular system is obstructed or obliterated by the inflammatory changes in the smaller vessels, but some of the interlobular veins always remain patent (Fig. 191 *e*).

As the portal capillaries are obliterated the circulation in the portal vein becomes obstructed. This leads to **portal engorgement**, to swelling of the spleen, to ascites, and frequently to hæmorrhage. The lobular circulation is however not entirely interrupted, for the hepatic artery partly takes on the functions of the portal vein. The main branches dilate, the smaller branches increase in number, and furnish blood to the thickened and overgrown capsule of Glisson as well as to the lobules. But it must be kept in mind that, in the varieties of hepatitis in which the liver becomes contracted, this blood-supply is manifestly insufficient

for the nutrition of all the liver-cells. The result is that the cells sometimes very rapidly undergo fatty and pigmentary degeneration and actual necrosis.

The gradual obstruction of the portal circulation within the liver leads to the opening up of the vascular connections between the tributaries of the portal vein and the veins of the abdominal wall, the diaphragm, the œsophagus, and the capsule of the kidney, the lumbar veins, and the spermatic veins. Now and then the subserous veins of the round (umbilical) ligament become dilated and continuous with the subcutaneous veins around the umbilicus, and so give rise to a tortuous plexus of dilated veins visible on the surface and known as a *caput medusæ*.

498. The extent of the inflammatory change depends in the first place on the mode of diffusion of the irritant through the liver. Inflammation starting from the portal vessels and inflammation starting from the hepatic artery differ notably in this respect. The inflammatory change may be limited to one or more branches of the respective vessels, or it may extend uniformly over the territory supplied by one or by the other. In the former cases the affected parts are scattered and isolated; in the latter the interlobular tissue throughout the liver is uniformly affected and altered. As the change extends from the interlobular tissue to the lobules and approaches the region of the intralobular vein, it of course tends to become more and more uniform and diffuse. Between the extremes of a few isolated patches and an alteration of the liver-tissue which is uniformly diffused there may be any number of intermediate grades.

The variety of inflammation which starts in the bile-ducts, or so-called **biliary hepatitis**, has certain peculiarities. It generally arises in connection with retention of bile, and engorgement of the biliary canals (Art. 512). The inflammation is at first confined to circumscribed patches, usually round in shape and infiltrated with bile-pigment. The patches lie either in the interlobular tissue or within the lobules. The inflammation is sometimes of the plastic or formative type and sometimes purulent.

Recent inflammation of the liver is always accompanied by swelling of the whole organ, which is more marked as the inflammation is more extensive. Minute patches of inflamed tissue may not be recognizable by the unaided eye, but when they reach any perceptible size they appear gray or grayish-red.

When fibrous tissue is developed in consequence of antecedent inflammation the enlargement of the liver becomes still more marked. This secondary enlargement is naturally greatest in cases where the affection extends over the entire intra-hepatic portal system, and thence spreads to the lobules.

The appearance of the liver at this stage exactly resembles that described in Art. 480 as the condition of infiltration, and represented in

Fig. 180. The difference is merely that in the interlobular tissue and in the lobules we have accumulations not only of pigment or of leucocytes but also of formative cells and fibrous tissue varying in tint from grayish or reddish to yellow or greenish according to the amount of blood and of bile-pigment present. The yellow or greenish staining is most marked when the outflow of bile is hindered by the development of fibrous tissue and the retained bile stagnates and forms concretions in the ducts.

The lobules themselves may appear brownish-red, brown, yellow, or gray according as they contain more or less of blood or bile.

The enlargement of the liver by the growth of new fibrous tissue is sometimes so great that the weight rises to three or four kilogrammes (seven to nine pounds) or more. The condition might be aptly termed hyperplastic fibroid induration, but it is usually spoken of as '**hypertrophic cirrhosis.**' The surface of the liver is smooth, the tissue

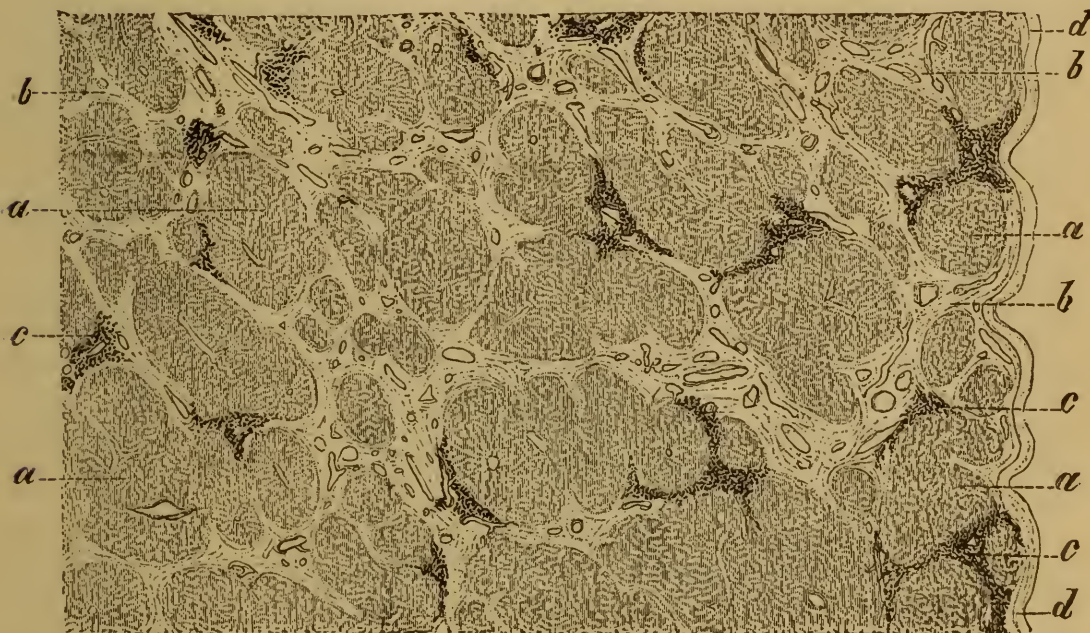


FIG. 192. ATROPHIC CIRRHOSIS OF THE LIVER.

a, isolated patches of liver-tissue.
b, bands of vascular fibrous tissue.

c, cellular infiltration.
d, peritoneum.

dense and tough. When the lobules are invaded by the growth of fibrous tissue their outlines are indistinct or entirely lost.

The liver can of course become larger in this way only when the new fibrous tissue which is added more than counterbalances the liver-cells which are atrophied or destroyed. In many cases this is actually the case throughout, that is to say up to the death of the patient. But in other cases the progressive atrophy of the parenchyma is so great that the volume of the liver as a whole diminishes again.

'When the fibrous overgrowth is at all extensive the diminution of volume is not so great as to reduce the size of the liver much below the

normal. This last is much more likely to happen when the change is from the beginning somewhat limited, affecting the interlobular tissue only, and not the whole of that.

In such a case the section of the liver shows at first nothing more than a number of bands or strands of fibrous tissue (Fig. 192 *b*) running through it; these are grayish-red or yellow or greenish, and enclose isolated patches of liver tissue that look yellow or gray or brownish as the case may be.

As the fibrous tissue shrinks and the liver-cells become atrophied, the liver at first more or less enlarged begins to contract. At the same time it becomes uneven and its surface is roughened, from the unequal shrinking of the fibrous bands (*b*) and of the remaining patches of liver-tissue. When these latter are small the section appears granular; when they are larger it is rather to be described as nodular or tuberculated or 'hob-nailed.' When the fibrous overgrowth (and thus the contraction) is confined to a part only of the portal territory, the inequalities are of larger size and the liver may thus become lobulated. In extreme cases the volume of the shrunken organ is reduced by a half or two-thirds, and its form is at the same time gravely altered so that it becomes rolled up into a cylinder or flattened and tongue-shaped.

Interstitial hepatitis leading to contraction of the liver is described as **atrophic** or **Laennec's cirrhosis** (Fig. 191).

Chronic interstitial hepatitis has been much investigated during the last twenty or thirty years, and attempts have been made to distinguish various forms. SURRE for example describes eight of these. Such classifications have no great scientific value, as the forms constantly pass one into another. It is enough to distinguish the hypertrophic conditions from the atrophic; and even then it must be borne in mind that these conditions merely represent different degrees or different stages of what is essentially one and the same process.

CHARCOT and GOMBAULT have contended that biliary hepatitis (Art. 498) always corresponds to the hypertrophic form; but this is incorrect, for inflammations starting from the bile-ducts do not always lead to hypertrophic induration (Art. 512), while the latter is often a result of inflammations starting from the portal vein or hepatic artery.

Jaundice, which may present or absent in cases of cirrhosis, does not by itself indicate either one form or the other; for both may in certain cases lead to retention of bile by obstruction of the smaller ducts.

References:—BRIGHT, *Medical Cases* London 1827, *Guy's Hosp. Rep.* 1836; BUDD, *Diseases of the liver* London 1857; FRERICHS, *Klinik d. Leberkrankheiten, Diseases of the liver* (New Syd. Soc. trans. by MURCHISON) London 1862; E. WAGNER, *Arch. d. Heilkunde* III.; LIEBERMEISTER, *Beiträge zur path. Anat. u. Klinik d. Leberkrankheiten* Tübingen 1864; HABERSHON, *Guy's Hosp. Rep.* 1871; LAENNEC, *Traité de l'auscultation médiate* Paris 1826; CHARCOT, *Leçons sur les malad. du foie et des reins* Paris 1877; ZENKER, *Deutsch. Arch. f. klin. Med.* X.; CORNIL, *Arch. de physiol.* 1874; HAYEM, *ibid.* 1874; THIERFELDER, *Ziemssen's Cyclop.* IX., *Atlas d. path. Histologie*; JACCOUD, *Traité de path.* II.; BRIEGER, *Virch. Arch.* vol. 75; KÜSSNER, *Sammlung klin. Vorträge* no. 141; NICATI and RICHAUD, *Travaux du laboratoire de la rue des Fabres à Marseille* 1881; HAMILTON, *Journ. of anat. and physiol.* XIV.; CHARCOT and GOMBAULT, *Arch. de physiol.* 1876, *Leçons sur les*

maladies du foie, *Progrès médical* 1876, *Leçons sur diverses formes de sclérose hépatique* Paris 1879; SCHMIDT, *Zur path. Anat. d. Lebercirrhose* In. Diss. Bonn 1880; ACKERMANN, *Virch. Arch.* vol. 80; WYSS, *Virch. Arch.* vol. 35; HANOT, *Arch. générales de méd.* 1876; SURRE, *Etude sur diverses formes de sclérose hépatique* Paris 1879; POPOFF, *Virch. Arch.* vol. 81; POSNER, *ibid.* vol. 79; SIMONS, *Deutsch. Arch. f. klin. Med.* XXVII.; MANGELSDORF, *ibid.* XXXI.; BELOUSSOW, *Arch. f. exp. Path.* XIV.; LITTEN, *Charité-Annalen* v. (1878); FOÀ and SALVIOLI, *Arch. per le scienze med.* 1877; TEUFFEL, *Ueber hepatitis sequestrans* In. Diss. Tübingen 1878; CARL, *Ueber hepatitis sequestrans* In. Diss. Tübingen 1880; SABOURIN, *Revue de méd.* 1882 (finds that the intralobular veins are frequently occluded in cirrhosis); AUFRECHT, *Pathol. Mittheil.* II. (1883).

FOÀ, SALVIOLI, LITTEN, LEG, POPOFF, BELOUSSOW, and others have produced artificial hepatitis by ligation of the common bile-duct in dogs, rabbits, and guinea-pigs (Art. 512).

Syphilitic hepatitis.

498. **Acquired syphilis** may give rise to certain diffuse inflammatory changes in the liver, which from an anatomical point of view closely resemble the forms of cirrhosis we have just considered. The syphilitic nature of the lesions can therefore be determined only when other affections more characteristic of the disease are present.

But diffuse change of this kind is less common as a result of syphilis than are certain circumscribed and localized lesions, of which we seldom see anything but the terminal stages in the post-mortem room.

At various points, but chiefly in the neighborhood of the suspensory

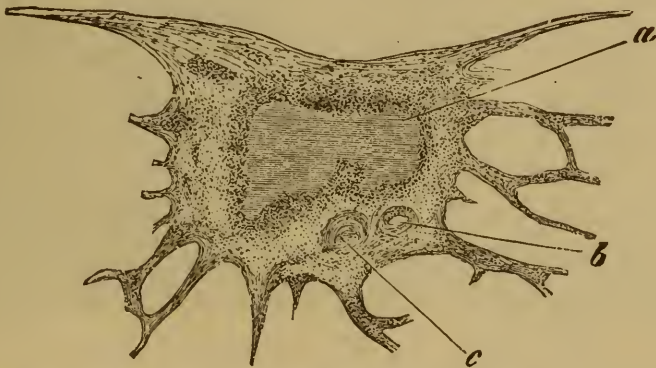

FIG. 193. GUMMA OF THE LIVER UNDERGOING CASEATION. (X 25.)

a, gumma enclosed in a capsule of scar-tissue.

b, artery with thickened wall.

c, obliterated portal vein.

ligament, the surface of the liver is scarred and contracted or puckered, the peritoneal covering being thickened. If a section is made through one of these scars, we come upon a knot of dense fibrous tissue which sends radiating bands or branches into the surrounding liver-substance (Fig. 193).

The lobules included between these fibrous bands are brown and atrophied. As the centre of the node is approached the liver-tissue becomes less and less visible, being reduced to mere isolated patches and fragments (Fig. 194 c) and at length in the fibrous zone disappearing altogether. Sometimes this is all that is found, but in other cases the fibrous node

contains within it a caseous patch from the size of a pin's head to that of a cherry or larger. The patch if recent is surrounded by a gray semi-translucent areola of cellular tissue (Fig. 193). In the later stages it is directly enclosed by the fibrous zone, though isolated cellular foci may persist for a long time in the neighborhood of the node. Such a node is referred to as a gumma or gummatous node (Art. 130).

In rare cases two or more gummata are included in the same scar, and occasionally there is none at all. Similar gummata are met with also in the deeper parts of the liver; there may be as many as thirty or more of them. When the scars are numerous the liver becomes lobulated by their contraction.

As described in Art. 130 the centre of the node consists of homoge-

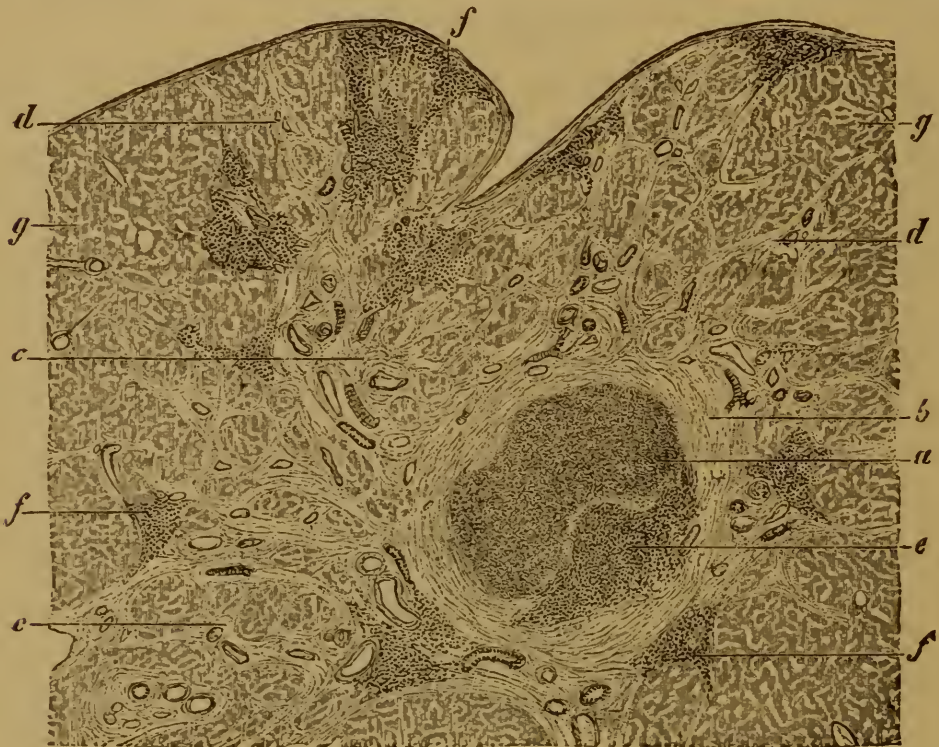

FIG. 194. SYPHILITIC SCAR AND GUMMA OF THE LIVER.

(Hardened in alcohol, stained with alum carmine, mounted in Canada balsam: $\times 12$.)

- | | |
|--|---|
| a, caseous centre. | d, ramifying bands of fibrous tissue. |
| b, zone of dense fibrous tissue. | e, patch of semi-translucent cellular tissue. |
| c, fibrous tissue enclosing fragments of liver-tissue. | f, cellular foci outside the fibrous zone. |
| | g, normal liver-tissue. |

neous denucleated necrotic tissue, or of granular detritus; the gray areola and the cellular foci are made up of granulomatous tissue. The materials in the centre are the remains of the liver-tissue infiltrated and destroyed in consequence of the syphilitic inflammation. The inflammatory process resulted primarily in the formation of a kind of granulation-tissue; but this was not completely transformed into new fibrous tissue, part of it becoming necrotic and ultimately caseous. The non-formative or rather destructive character of the syphilitic inflammation is due either

to some peculiar property of the syphilitic virus, or to the rapid occlusion of the smaller blood-vessels (portal and arterial) by specific endophlebitis and endarteritis.

500. **Congenital syphilis** also leads to hepatic disease. The affection takes the form either of cellular infiltration with more or less extensive fibroid induration, or of gummatous growths. These forms are met with not only in fœtuses and in infants who have died soon after birth, but also in young patients who in their infancy have not shown the signs of the disease.

When the cellular infiltration is slight the liver is not visibly altered, so far as can be made out by the naked eye. The microscope however readily proves the presence of extravasated leucocytes or granulation-cells. The interlobular tissue is usually the most affected, though infiltrated patches lying within the lobules are not uncommon. The leucocytes are often aggregated in greater numbers within the capillaries than outside them.

In marked contrast to this, the mildest variety of the affection, we occasionally meet with cases in which the whole liver is beset with new fibrous tissue, and thereby remarkably altered, enlarged, and indurated. The liver-substance is either uniformly pale or grayish-yellow, or of the color of flint (GUBLER) mottled with yellow, brown, and gray. The lobular structure is more or less indistinct, the cut surface having an even uniform structure.

The induration and enlargement are due to an abundant overgrowth of fibrous tissue, which extends with more or less uniformity not only along the portal sheaths but through the entire capillary network of the lobules.

The result is that the liver-cells, where they still survive, are for the most part shut off from their capillaries (Fig. 195) by a stratum of fibrous tissue either homogeneous and containing few cells or fibrillated and cellular. The liver-cells thus surrounded and enclosed are more or less atrophied and distorted; in some places they disappear altogether. At the same time the configuration of the capillary network is remarkably altered.

This form of diffuse fibrous overgrowth leads to a hypertrophic cirrhosis of the liver in the manner already described; but certain other forms of induration occur in patients suffering from congenital syphilis which belong rather to the class of atrophic cirrhoses.

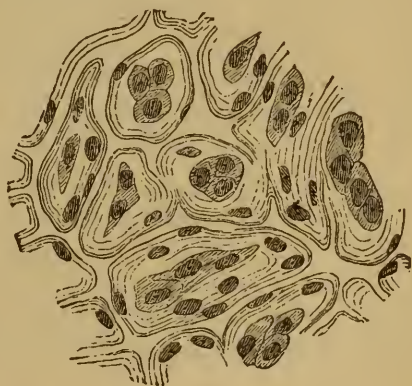


FIG. 195. DIFFUSE FIBROID INDURATION OF THE LIVER IN CONGENITAL SYPHILIS.

(From an injected preparation: $\times 150$.)

The atrophied liver-cells are everywhere separated from the capillaries by a stratum of fibrous tissue.

There are also cases in which

the fibrous overgrowth is confined to the sheaths of the larger branches of the portal vein, and often reaches an extraordinary development. The fibrous tissue is sometimes highly cellular, sometimes not.

Gummatous hepatitis is another variety of syphilitic inflammation. It occurs in two forms, the miliary and the nodose.

Miliary gummata or syphilomata are simply small circumscribed foci of inflammatory infiltration, seated partly in the interlobular tissue, partly in the lobules. The affection is thus a special modification of the syphilitic hepatitis already described. The nodules are scattered through the entire liver, or confined to particular regions; in the latter case they are usually aggregated into groups and clusters. The single foci are punctiform, or it may be as large as a pin's head; when recent they are gray, but afterwards they turn yellowish-white or yellow. The intervening liver-tissue is either unaltered or affected with diffuse interstitial inflammation. Some of the liver-cells within the inflamed area are broken down or necrotic.

Nodose gummata are most frequently met with in patients who survive birth some months or years. When recent they form rounded or elongated and branched white patches with serrated or irregular margins. After a time the centre becomes caseous, and coarse cicatricial tissue forms about the periphery: as this contracts the surface of the liver is usually drawn in and puckered. The gummata of congenital syphilis are thus very similar to those of the acquired disease. When the liver is at all gravely affected by syphilitic hepatitis, inflammatory changes are induced in the capsule or serous covering (perihepatitis), which take the form either of simple exudations or of membranous adhesions to the surrounding parts.

References:—FRERICHS, *Klinik d. Leberkrankheiten, Diseases of the liver* II. London 1862; VIRCHOW, *Die krankh. Geschwülste* II.; GUBLER, *Gazette méd. de Paris* 1852, 1854; BUDD, *Diseases of the liver* London 1857; WILKS, *Guy's Hosp. Rep.* 1863, *Trans. Path. Soc.* 1866; BÄRENSPRUNG, *Die hereditäre Syphilis* Berlin 1864; WEBER, *Trans. Path. Soc.* 1866; MOXON, *ibid.* 1871, 1872; LANCEREAUX, *Traité de la syphilis* Paris 1873 (trans. by WHITLEY, *New Syd. Soc. London* 1869), with references; SCHÜPPEL, *Arch. d. Heilk.* XI.; HINTZEN, *Beiträge z. Lehre von d. congenitalen Syphilis* In. Diss. Tübingen 1869; E. WAGNER, *Arch. d. Heilk.* V.; FREUND, *Jahrb. d. Kinderheilk.* IX. (1875); BIRCH-HIRSCHFELD, *Gerhardt's Handb. d. Kinderkr.* IV.; CHVOSTEK, *Viertelj. f. Derm. u. Syph.* VIII. (1881); CAILLÉ, *Zur path. Anat. d. congen. Lebersyphilis* In. Diss. Würzburg 1877; CORNIL and RANVIER, *Man. Path. Hist.* I. London 1882.

Tuberculosis of the liver.

501. **Tuberculosis** of the liver appears in two chief forms, namely as miliary tuberculosis and as tuberculous hepatitis.

The former is much more common than the latter, and is usually but a part of a general tuberculosis involving several organs or the entire body. The liver is beset with minute nodules, often so small as to be

scarcely perceptible, and gray, yellow, or bile-stained, as the case may be. The nodules lie either in the interlobular tissue or in the lobules or in both.

The nodules when recent consist of simple aggregations of small cells (Fig. 196 *b*); when more advanced they contain giant-cells; when 'mature' the central cells are denudeated and necrotic.

The most recent tubercles exactly resemble foci of simple inflammatory infiltration. The eruption of nodules is not infrequently accompanied by a diffuse and somewhat extensive cellular infiltration of the liver generally. Nodules of larger size are as a rule manifestly made up of smaller nodules.

As the tubercles become mature the infiltrated liver-tissue in which they are seated becomes necrosed and the cells are transformed into shapeless denudeated blocks. The bile-ducts sometimes perish in like manner. When they are surrounded or enclosed by tubercles the epithe-

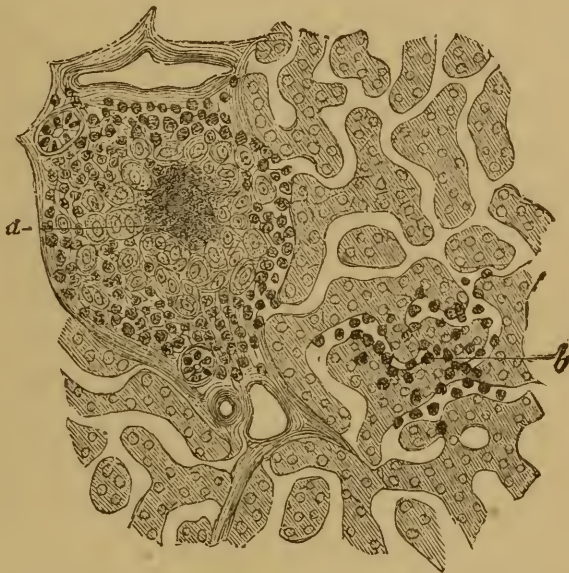

FIG. 196. MILIARY TUBERCULOSIS OF THE LIVER.

(Carmin staining: $\times 150$.)

a, mature tubercle.

b, crude or recent tubercle.

lial cells, especially when they coalesce or fuse together, may simulate giant-cells. According to ARNOLD new bile-ducts may be formed in the midst of a tuberculous nodule, as in non-tuberculous interstitial hepatitis (Art. 497).

In the second form of tuberculosis, or chronic tuberculous hepatitis, there is not only an eruption of nodules but also a diffuse fibrous hyperplasia of the liver. Its tissue is traversed by more or less dense bands of fibrous tissue, containing small gray tubercles or larger yellow or bile-stained caseous patches. When these reach a considerable size they break down and cavities are formed, which enclose liquid or pulpy bile-stained

detritus. Cases occur in which the entire organ is honeycombed with innumerable cavities varying in size from that of a pea to that of a walnut; but such cases are rare. Large caseous nodes, resembling the solitary tubercles of the brain, are also rare.

References:—J. ARNOLD, *Virch. Arch.* vol. 80; ORTH, *ibid.* vol. 60.

CHAPTER LXI.

TUMORS AND PARASITES OF THE LIVER.

Primary Tumors.

502. Both epithelial and connective-tissue tumors occur in the liver, but rarely as primary growths.

Of the epithelial tumors **adenoma** must first be considered, though it is a decidedly rare affection. It takes the form of multiple nodules, from the size of a millet-seed to that of a cherry, and grayish or yellowish or reddish on section. The smallest nodules are continuous with the surrounding liver-tissue, the larger ones are enclosed in a fibrous capsule and frequently undergo a process of internal softening.

When the adenomatous nodules are numerous the liver becomes greatly enlarged, and its surface is beset with rounded protuberances. Only one case is recorded (GREENFIELD) in which the tumor had given rise to metastatic growths.

The nodules consist of convoluted and anastomosing glandular tubes resembling the convoluted tubules of the kidney, and embedded in a framework of vascular fibrous tissue. According to RINDFLEISCH these tubes are developed from the cylindrical columns or trabeculæ of the liver-cells; the cells being supposed to multiply abnormally and to group themselves into tubular clusters. As the smaller nodules increase in size, fresh liver-cells are drawn into the growth, and the tubes already developed throw out fresh off-shots and branches.

References:—GRIESINGER, *Arch. d. Heilk.* v. (1864); RINDFLEISCH, *ibidem*; *Path. Histol.* vol. I.; GREENFIELD, *Trans. Path. Soc.* 1874; KELSCH and KIENER, *Arch. de physiol.* III. 1876 (with good figures); BIRCH-HIRSCHFELD, *Lehrb. d. path. Anat.* Leipzig 1877.

503. **Carcinoma** of the liver, as a primary growth, occurs in three chief forms.

In the first or nodose form, one or more nodes are formed, which may be seated in any part of the liver, but occur most commonly in the right lobe. The nodes are often of great size and cause the affected lobe to be much enlarged, the normal tissue being for the most part replaced by tumor-tissue. The nodes are usually globular and consist of soft or hard, white or slightly reddened tissue; the amount of cancer-juice which can be scraped from the cut surface varies much, and is sometimes very small indeed. At some points the tumor-tissue is sharply marked off from

the liver-tissue, the latter being manifestly compressed and distorted. At other points the tumor is continuous with the liver-tissue. The larger nodes are frequently softened or necrotic in the centre, or contain extravasated blood.

The second form has been well described as diffuse cancerous infiltration (or degeneration) of the liver. The organ is more or less enlarged, sometimes greatly enlarged, the serous capsule is thickened and tuberculated, much as in atrophic cirrhosis. On section also there is a resemblance to the cirrhotic liver, inasmuch as the whole organ is traversed and beset with anastomosing fibrous bands enclosing prominent islands of pale or reddish or bile-stained tissue. On examination these islands are seen to be carcinomatous in structure, and so the affection is distinguished from ordinary cirrhosis.

In the third form the cancerous growths are seated in the interlobular connective tissue. Wherever the portal vessels run they are seen to be

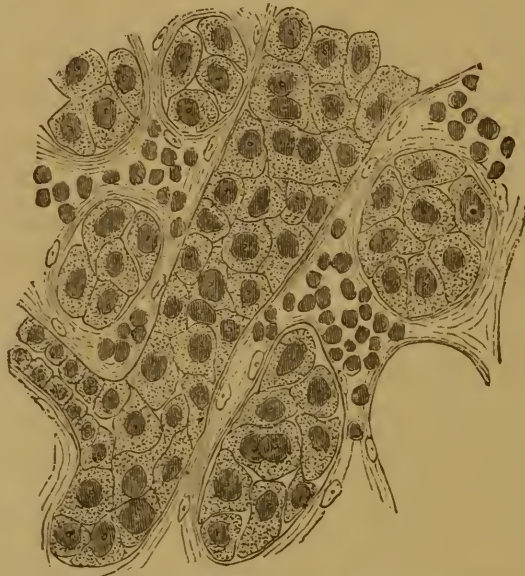

FIG. 197. CANCER OF THE BILE DUCTS.
(*Hamatoxylin* staining: $\times 200$.)

At the left side below a cancerous cell-nest is seen in communication with a bile-duct.

accompanied by white tumid nodules, in close mutual contact or actually coalescent, and varying in size with the size of the vessels. The smallest nodules are about the size of a millet-seed, the largest may be three to four centimetres across. The liver as a whole is of course greatly enlarged. The surface is smooth, as the nodules generally lie deep, only appearing (as white uneven protuberances) about the portal fissure.

None of the various forms of hepatic cancer show any marked peculiarity of structure (Fig. 197). The epithelial cells often form mere atypical clumps or nests; but cases occur in which they are arranged somewhat after the glandular type, the periphery of the nests being clothed with a layer of cylindrical cells. Sometimes too the alveoli of the fibrous stroma are simply lined with epithelial cells, without other

contents. So far as can be made out by examination of sections, it appears that the neoplastic epithelial growth may start either from the epithelium of the bile-ducts or from the liver-cells themselves. It is sometimes possible to make out an actual communication between the cell-nests and the unaltered bile-ducts (Fig. 197).

References:—PERLS, *Virch. Arch.* vol. 56; WEIGERT, *ibid.* vol. 67; SCHÜPPEL, *Arch. d. Heilk.* 1868, *Ziemssen's Cyclop.* IX.; NAUNYN, *Du Bois-Reymond's Arch.* 1866; WALDEYER, *Virch. Arch.* vol. 55; BIRCH-HIRSCHFELD, *Gerhardt's Handb. d. Kinderkr.* VIII.; WULFF, *Der prim. Leberkrebs* In. Diss. Tübingen 1876.

504. Primary connective-tissue growths are very rarely met with in the liver; but cavernous angioma or erectile tumor is not so uncommon.

Cavernous angiomata (Art. 150) form tumors as small as a millet-seed or as large as the fist, taking the place of a corresponding amount of liver-tissue. The liver is therefore not necessarily enlarged.

Angiomata lying close beneath the capsule appear as dark or livid spots; on section they are dark-red. In the larger tumors the cavernous

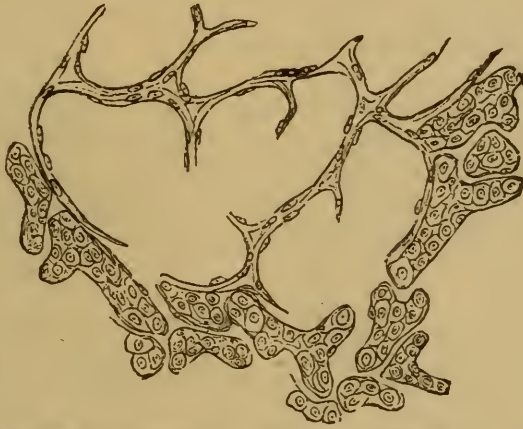

FIG. 198. SECTION FROM THE ADVANCING BORDER OF A VERY SMALL CAVERNOUS ANGIOMA OF THE LIVER. ($\times 150$.)

or spongy texture is easily recognized, the pale fibrous septa contrasting with the blood contained in the meshes and cavities. The larger tumors again are bounded by a fibrous capsule, while the smaller are continuous with the liver-tissue.

As we have pointed out in Art. 150, the cavernous growth arises from a varicose dilatation of the capillaries of a lobule (Fig. 198), accompanied by the disappearance of the liver-cells. Proliferation of the intervascular connective tissue is a secondary phenomenon. The capsule of the larger tumors is formed essentially of the interlobular fibrous tissue surrounding the lobules. The intercavernous septa vary in thickness, but are usually thin and delicate.

Cavernous angioma is thus strictly speaking no true neoplasm; it is due primarily to a localized atrophy of the liver-cells. Accordingly we find it most frequently in the atrophied livers of aged patients. Not infrequently the tumors are multiple, the liver being beset with a multitude of cavernous patches of the most various sizes.

True connective-tissue tumors of the liver are as we have said very rare. Various forms have however been described, notably fibroma and sarcoma.

Some years ago the author met with a case in which the liver was beset, along the course of the sympathetic nerves, with a multitude of small firm **fibroneuromata**, from the size of a millet-seed to that of a bean. The patient in question had like fibroneuromata seated on all his nerves, except the olfactory and the optic.

Melanosarcoma (endothelioma melanodes, Art. 162) has also been observed. In a case recently examined the liver was greatly enlarged and thickly interspersed with grayish-brown and black growths of the most diverse forms and varying in size from that of a millet-seed to that of a walnut. To judge from the appearances presented by the smallest, the neoplastic growth started from the endothelium of the lobular capillaries, and gave rise to gradual atrophy of the liver-cells. The pigment lay chiefly within the tumor-cells, which were curiously irregular in shape. In some cases the pigment is scanty or absent in parts, and the tumor has there a whitish or grayish tint.

References:—On angioma: Art. 150; PAYNE, *Trans. Path. Soc.* 1869; STEFFEN, *Jahrb. d. Kinderheilk.* 1882. On lymphangioma: KLEBS, *Handb. d. path. Anat.* I. On primary sarcoma and melanosarcoma; ROKITANSKY, *Path. Anat.* III. FÖRSTER, *Illustr. med. Zeitung* III.; FRERICHS, *Klinik d. Leberkrankh., Diseases of the liver* II. London 1862; BLOCK, *Arch. d. Heilk.* XVI. (1875).

Secondary tumors.

505. Secondary or metastatic growths, especially the cancerous, are very common in the liver. Carcinoma of the stomach, intestine, or pancreas is particularly apt to give rise to them, though they are not infrequent as a consequence of carcinoma of the œsophagus, uterus, or breast.

Cancerous metastases usually take the form of nodes, which vary much in number and sometimes pervade the entire liver. According to their stage of development they may be small, measuring only 11–20 mm., or so large as to measure 2–10 cm. in diameter.

The smaller growths when they lie beneath the capsule appear as whitish patches, the larger project above the surface and are sometimes umbilicated. The overlying part of the capsule is usually congested and injected. When the nodes are both large and numerous the liver is enlarged, often enormously so, and its surface is uneven and tuberos. The nodes on the anterior edge can often be felt through the relaxed abdominal wall. On section the tumors appear white or yellowish-white with perhaps a tinge of red.

The centre of a large node is not uncommonly found to be opaque, fatty, and softened, so that scraping yields a pulpy mass rather than a juice. Caseous and hæmorrhagic patches are also met with.

The form of the primary carcinoma determines to a great extent the characters of the secondary growths. When the primary tumor (as in the stomach or intestine) is soft and medullary, the secondary tumors are also soft: they are hard and firm when the primary tumor (as in the pancreas or breast) is firm or scirrhus. Melanotic cancers give rise to brown or black metastases in the liver.

The surrounding liver-tissue is visibly compressed, and it may or may not be sharply marked off from the tumor-tissue. The smaller nodes are usually ill-defined, the larger ones are more distinctly circumscribed. But in this respect something depends on the structure of the tumor: the softer varieties are more apt to thrust back the surrounding tissue, the firmer usually infiltrate it.

The liver-tissue itself is brown, yellow, or yellowish-green, the last being a sign of retention or stagnation of bile. When the cancerous

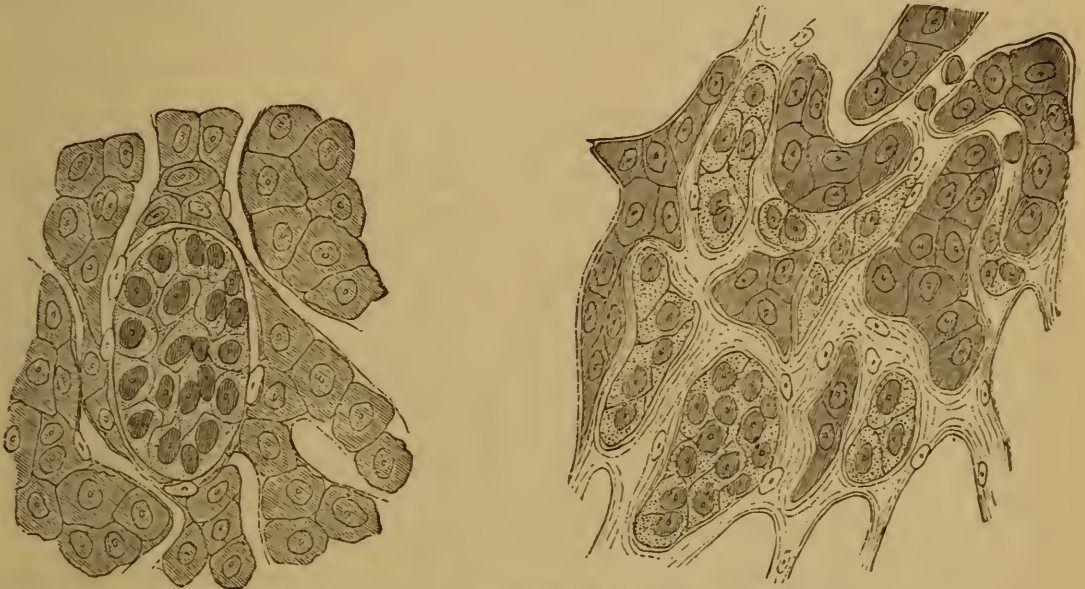

FIG. 199. CANCEROUS EMBOLUS IN A HEPATIC CAPILLARY.

(From a primary adenocarcinoma of the stomach: hæmatoxylin staining: $\times 300$.)

FIG. 200. METASTATIC GROWTH OF CANCER IN A HEPATIC CAPILLARY.

(From a primary cancer of the pancreas: fibrous tissue is developing in the capillary; hæmatoxylin staining: $\times 250$).

growths are numerous, the liver-tissue remains only in islands or narrow bands surrounded or encroached on by the advancing neoplastic tissue.

506. The **formation of these metastatic growths** is due to the invasion of the liver by germinal cancer-cells, which are brought to it by the blood-vessels, and (very rarely) by the lymphatics.

In by far the greater number of cases the germinal cells reach the liver by the portal vein. The places where the cells lodge and develop are in the smaller branches of the interlobular veins or in the capillaries of the lobules.

The first stage in the development that can be made out is the multiplication of the imported cells within the capillary where they have

lodged (Fig. 199). Then the capillary becomes distended by them, and the surrounding liver-tissue is compressed or thrust aside. As the nodule grows a new-formed fibrous stroma grows up among and between the cancer-cells, and separates them off into large and small clusters or nests, whose general grouping recalls the type of the mother-tumor. This fibrous stroma, which is vascular, is derived from the interlobular connective tissue of the liver. The liver-tissue either continues to be thrust aside, or is invaded, infiltrated, or permeated by the new growth.

The infiltration depends on the fact that fibrous tissue as well as cell-nests are developed within the capillaries (Fig. 200). The liver-cells surrounded and clasped by the new tissue presently become atrophied and disappear; before the last stage they often appear crammed with pigment granules.

Metastases derived from tumors not carcinomatous are rarely met with in the liver. Even sarcomatous nodules are not common, though they are occasionally found in children.

Animal parasites.

507. But few animal parasites take up their permanent abode in the human liver. The species which do so are—*Tænia echinococcus* (Arts. 245–248), *Distoma hepaticum* (Art. 237), *Distoma lanceolatum* (Art. 238), *Distoma hæmatobium* (Art. 239), *Pentastoma denticulatum* (Art. 225), and the *Psorospermia* (Art. 250). These have been fully described in the General Pathological Anatomy; here we propose merely to add something concerning the echinococcus or hydatid of the liver.

A **hydatid** has usually the form of a simple cyst, of the size of a walnut or larger. The wall is composed of an inner chitinous layer and an outer fibrous one, the latter being sometimes remarkably thickened.

If the echinococcus is alive the cyst contains a clear liquid, and the inner surface is covered with a whitish parenchymatous layer, on which are seated small white brood-capsules containing scolices (Art. 245).

Cases in which the mother-cyst is accompanied by internal or external daughter-cysts are less common.

By the time the liver comes to be examined the hydatid is usually dead, and the liquid wholly or partially absorbed. In this case the chitinous capsule is shrunken and folded, and contains a white cheesy, pulpy, or mortar-like and calcareous mass. In this the characteristic hooklets can often be discovered lying loosely. When the cysts reach a large size they may burst into the neighboring parts, for example, into the peritoneum or intestine, or externally; sometimes inflammation is set up around the cysts.

Echinococcus multilocularis, giving rise to what was formerly described as 'alveolar colloid' of the liver, is a peculiar variety described in Art. 247.

CHAPTER LXII.

THE GALL-BLADDER AND BILIARY DUCTS.

508. **Biliary concretions** and **gall-stones** are by far the commonest abnormalities in the contents of the gall-bladder and biliary ducts (hepatic, cystic, and common). They occur as a rule in elderly persons, more particularly in the gall-bladder. The concretions are friable granular yellow masses. The gall-stones or biliary calculi, which may be as small as a millet-seed or as large as a hen's egg, are rounded or ovoid, or angular and faceted. The latter is the case when several gall-stones have lain together in contact within the gall-bladder, the former when they have lain singly in the bladder or in one of the ducts.

The color, consistence, and density of the stones vary with their composition. As a rule they are somewhat soft, the surface pale grayish-white, yellowish, or brown deepening to black, and either smooth or rough as the case may be.

On section there is usually a dark-colored nucleus consisting of a combination of bile-pigment (bilirubin) and calcium-salts, surrounded by a lighter shell or crust containing crystalline plates of cholesterin radially disposed. The different species are distinguished according to the constituent which is most abundant.

(1) Stones consisting of **cholesterin**. These usually contain a pigmented nucleus, are single or multiple, grayish-white or yellowish-white in color, smooth or rough on the surface, slightly translucent, with sometimes a kind of pearly lustre. The fractured surface has a radiate crystalline appearance, and often shows traces of stratification. The stones are soft in texture. When stained with bile they are sometimes yellow or greenish or brown. When mixed with calcium-salts they are friable and chalky.

(2) Stones consisting of **cholesterin** and **pigment** are the commonest of all. According to the proportion of pigment they contain they are yellow, brown, black, or brownish-green. They are frequently present in enormous numbers and distend the bladder or ducts to a remarkable extent. They often contain a considerable amount of calcium carbonate and of magnesium-salts.

(3) Stones consisting of **bilirubin** and **calcium-salts**, or of biliverdin and calcium-salts, are rare and usually small.

(4) Stones consisting of **calcium carbonate** are very rare.

509. The exact way in which gall-stones are formed is not fully understood. In many cases foreign bodies are found within them, and we know that such bodies introduced into the biliary passages become crusted over. For example, a round-worm, which has crept into the common duct and there died, becomes covered with a coating of granular matters precipitated from the bile.

When the calcium-compounds and the cholesterin are dissolved out from a gall-stone, the insoluble residue is a nitrogenous body (HOPPE-SEYLER). It is probably derived from the remains of cast-off epithelium. No mucin can be detected, at least by chemical means.

Stagnation and decomposition of the bile seem to favor the formation of gall-stones. Certain conditions of the general nutrition are probably not without influence, seeing that the stones are much more common in patients of mature age than in younger patients.

Cholesterin is soluble in the sodium-compounds of the bile-acids, and thus a cholesterin-stone may be redissolved if the bile with which it comes in contact is not already saturated with cholesterin. The combinations of calcium-salts with the bile-pigments, on the other hand, are not soluble without actual decomposition (HOPPE-SEYLER).

510. The **effects** of the formation of **gall-stones** vary greatly in different cases. Often the wall of the gall-bladder is affected very slightly even when it contains a large number of stones.

Gall-stones give rise to very painful attacks (gall-stone or biliary **colic**) when they become impacted in the common or the cystic duct. Stones formed in the gall-bladder and in the ducts themselves are frequently discharged into the intestine through the common duct. But if one of these lodges or lingers in the duct, retention of the bile ensues; and this may give rise to dilatation of the ducts and to infiltration of the liver with bile. The liver-tissue may thereupon become degenerate or inflamed (Art. 512), while the parts around the impacted stone become also inflamed or even ulcerated. If the stone is near the mouth of the common duct the inflammation and ulceration may extend to the papilla at its mouth, and in this way set the stone free. Stones may escape from the gall-bladder into the intestine (duodenum or colon) directly: this of course can happen only when inflammatory adhesions have already been set up between the intestine and the gall-bladder. In unfavorable cases the stones break through into the peritoneal cavity or into the retroperitoneal tissue, or inflammation of the wall of the gall-bladder extends to the serous surface and peritonitis is induced.

When concretions form in the ducts within the liver, more or less intense inflammatory change is frequently set up around them. This change may be limited to an abundant cellular infiltration of the duct-wall and the adjoining tissue, which after a time leads to the formation of new fibrous tissue (Art. 496). Or when the retained bile becomes decomposed the inflammation often takes on a destructive character and

ends in an abscess; this again may break and lead to local or general peritonitis.

References :—BENEKE, *Deutsches Arch. f. klin. Med.* 1876; FIEDLER, *Jahresber. d. Gesell. f. Nat. und Heilk. zu Dresden* 1879; SCHÜPPEL, *Ziemssen's Cyclop.* IX., with full references; FRERICHS, *Leberkrankheiten, Diseases of the liver* II. London 1862; ROTH, *Correspondenzblatt f. Schweizer Aerzte* XI. (1881); PETERSSEN-BORSTEL, *Gallensteinbildung in ihrer Beziehung zu Krebs und Endarteritis chron.* In. Diss. Kiel 1883.

511. We said in the last Article that the bile-ducts sometimes become dilated behind an obstructing concretion. The seat and extent of the dilatation depend of course on the seat of obstruction. Closure of the common ducts leads to accumulation and stagnation of the bile in the gall-bladder as well as in the hepatic duct and its branches. Closure of one of these branches naturally affects the bile and the smaller ducts of the corresponding region and no other. A duct may be closed either by concretions forming within it, or by inflammatory growths or tumors in or near its wall. Parasites, such as the round-worm or the *Distoma*, sometimes creep into the ducts from the intestine, and occlude them.

The secretion which accumulates behind an obstruction is not always simply bile. When the cystic duct is occluded it is plain that no bile can collect in the gall-bladder. When therefore this becomes distended it is owing to the secretion of a mucous liquid from the mucus-glands in its lining membrane. This condition is described as **dropsy of the gall-bladder**. Something similar takes place in the ducts. When a portion of a duct containing mucus glands becomes abstricted, a mucous secretion may be poured out and distend it. **Cysts** of various sizes, and having smooth slimy walls, are thus formed within the liver. According to VON RECKLINGHAUSEN (*Virch. Arch.* vol. 84) this is the usual mode of origin of the small cysts which are found lying just beneath the serous membrane of the liver. In these cases there has at no time been any retention of bile; the *vasa aberrantia* of the biliary ducts (FERREIN) have simply become distended by the mucous secretion of their own glands. Some cysts of the liver are due to the distention of the lymphatics with accumulated lymph.

When no secretion is poured into a gall-bladder whose duct is obstructed, the normal contents sometimes become inspissated or even calcified. The bladder itself usually shrinks; while if inflammation is set up within it its walls may become notably thickened or in some parts ulcerated.

512. **Inflammation of the gall-bladder** (cholecystitis) and of the ducts has already been referred to in treating of interstitial hepatitis (Art. 498), and of the effects of biliary concretions. It is not an uncommon affection, and may be set up by the extension of an intestinal inflammation to the common duct and its branches, by stagnation or

decomposition of the bile, or by irritant matters brought to the mucous membrane by the blood.

Even the slighter forms may lead to obstruction of the ducts, retention of the bile, and **jaundice**; the obstruction being due to excessive mucous secretion or to swelling of the mucous membrane. In more intense or more chronic inflammations the exudation from the ducts and gall-bladder may be purulent. The connective tissues are thickly infiltrated; and not infrequently the capsule of Glisson round the hepatic duct, or the peritoneum round the gall-bladder, are likewise intensely inflamed. This last is especially the case when the primary inflammation is of a necrotic character accompanied by diphtheritic excoriation and ulceration. Within the liver purulent inflammations of this kind give rise to small abscesses containing liquid bile and biliary concretions. When such abscesses are formed in the gall-bladder or in the larger ducts outside the liver, or when they lie close beneath the capsule on its surface, they are very apt to cause peritonitis.

Chronic inflammation of the gall-bladder leads in general to thickening of its walls and to adhesions with the surrounding parts. The bladder frequently shrinks in consequence. The fibrous capsule around the ducts becomes in the like circumstances notably hyperplastic. Now and then the bladder and larger ducts appear beset with papillary outgrowths from the same cause.

When such an inflammation of the ducts persists for a long time, or leads to persistent retention of the bile, the inflammatory changes extend to other parts of the liver. Brown or yellow granular biliary concretions appear in the interlobular tissue and within the lobules. The liver cells perish at various points; and inflammatory infiltrations appear within the lobules and terminate in abscess or in fibroid induration (Arts. 496-498).

Some authorities (SCHÜPPEL, TEUFFEL) have described the form of biliary hepatitis which terminates in abscess as *hepatitis sequestrans* (see Art. 498 for references).

Tumors of the gall-bladder and ducts are rare, **carcinoma** being the commonest form. As we have already pointed out (Art. 503) many cancers of the liver start in the smaller bile-ducts. Cancers of the gall-bladder begin as soft growths arising from the inner surface, which as they develop may extend to and invade the liver.

Destructive **adenoma** (adenocarcinoma) of the duodenum sometimes develops at or near the opening of the common duct, and may obstruct or altogether occlude the passage.

CHAPTER LXIII.

THE PANCREAS.

513. The **pancreas** is an acinous or tubulo-acinous gland, whose duct (canal of Wirsung) passes into the wall of the duodenum and there joins the common bile-duct, opening with it through a common orifice into the bowel. Only in rare cases has it a distinct orifice. The secretion of the pancreas, which is in effect an abdominal salivary gland, acts powerfully in promoting the digestion not only of starchy matters but also of albuminoids and of fat.

The morbid changes of the pancreas are seldom very marked; though it is liable to various affections both primary and secondary.

Of **anomalies** of development the presence of an accessory pancreas is the most noteworthy. This is a discoid structure, from the size of a lentil to that of a crown-piece, made up of glandular lobules, and seated on the wall of the upper part of the small intestine or of the stomach. It lies either close beneath the peritoneum, or more deeply embedded in the muscular or submucous layers. Its minute structure is exactly similar to that of the pancreas itself, and it communicates with the alimentary canal by a duct of its own.

The division of the pancreas into two equal or unequal lobes is much less common. The gland is entirely absent in various cases of imperfect development, where the whole body of the foetus or the alimentary canal in particular is gravely malformed.

Hæmorrhage (pancreatic apoplexy) is not an infrequent occurrence in connection with the pancreas. When it occurs shortly before death the fibrous structures of the gland, and the neighboring parts, are found soaked with dark blood. More rarely a typical **hæmatoma** or blood-cyst is formed. When the hæmorrhage is less recent the infiltrated tissue has a brown or slaty tint.

These hæmorrhages are usually due to affections of the heart, lungs, or liver which give rise to engorgement of the abdominal veins. Cases however occur in which no such cause can be assigned, and in which we are constrained to assume that the cause is local; but it should be said that it is seldom possible to demonstrate this *post mortem*. Pancreatic hæmorrhage may prove fatal, probably from some depressant or other action upon the semilunar ganglia or solar plexus of sympathetic nerves.

Details of the morbid changes affecting the pancreas will be found in KLEBS'S *Handb. d. path. Anat.* I., in FRIEDREICH'S Article in *Ziemssen's Cyclop.* VIII., and in ROBERTS'S Article in *Quain's Dict. of Med.* London 1882. KLEBS and FRIEDREICH give full references to the older and the more recent papers on the subject.

Pancreatic hæmorrhage is discussed by KLEBS (*op. cit.*), ZENKER (*Naturforscherversammlung in Breslau* 1874), CHALLAND and RUBONI (*Bull. de la soc. med. de la Suisse romande* 1877), PRINCE (*Boston med. and surg. Journ.* 1882), GUSSENBAUER (*Wiener med. Woch.* 13, 1883, *Medical Times* I. 1883). ZENKER describes three cases in which the hæmorrhage occurred in strong healthy men and speedily prove fatal.

514. **Atrophy** of the pancreas is met with in cases of general marasmus, and not infrequently in patients who have died of diabetes. The pressure of neighboring parts, and overgrowth of the interacinous connective and adipose tissue, may lead to atrophy of the gland-substance by compression. In simple atrophy the acini dwindle and in some places disappear entirely. The affected lobules may look quite normal in color, or they may be somewhat brown.

Fatty degeneration of the gland-cells is likewise met with, and is characterized by the yellowish-white tint it imparts to the parenchyma. It may begin as simple atrophy.

Lipomatosis or fatty infiltration of the gland as a whole is of a different nature. It is due to the transformation of the interacinous connective tissue into adipose tissue. It may be combined with a certain amount of glandular atrophy, so that in a sense the gland-cells may be said to be replaced by fat.

Amyloid degeneration of the vessels and connective tissue of the pancreas is not uncommon in association with amyloid disease in other organs. The gland-cells remain unaltered, or here and there undergo fatty degeneration.

Concretions are occasionally but not very often found in the pancreatic duct or its branches. They consist chiefly of calcium carbonate and phosphate. The smallest are as fine as grains of sand, the largest are about the size of a hazel-nut. They are usually round or ovoid, seldom angular or irregular in shape. The surface is sometimes smooth, sometimes uneven. Most of them are white or grayish-white, a few are distinctly gray or brown. They are commonly due to some interference with the free outflow of the secretion, and may occur in large numbers in the same patient. Inflammation is usually set up around them, and leads either to destruction of the gland-cells and induration of the connective tissue, or to suppuration and abscess.

When the pancreatic duct is occluded by concretions or inflammatory change or by a tumor, it becomes dilated behind the obstruction into a cylindrical, sacculate, or moniliform cyst or series of cysts: these have been described as **pancreatic ranulæ**, and sometimes reach a considerable size. The contents of the dilated duct are either pancreatic juice

with mucus, or pus, or a bloody liquid. In small cysts they now and then become inspissated and calcified. When indurative inflammation is set up around the cyst, the gland-cells often perish. Cystic dilatation of limited portions of the minor ducts is much less common : but it sometimes occurs at a number of points scattered through the gland.

On pancreatic concretions see VIRCHOW (*Verh. d. phys.-med. Gesell. zu Würzburg* II. 1852), FAUCONNEAU-DUFRESNE (*Traité de l'affection calculuse du foie et du pancréas* Paris 1851), CURNOW (*Trans. Path. Soc.* 1873), JOHNSTON (*American Journ. of med. sciences* 1883, an admirably summary with full references).

On pancreatic cysts see ROKITANSKY (*Lehrb. d. path. Anat.* III. 1861), VIRCHOW (*loc. cit.*), VON RECKLINGHAUSEN (*Virch. Arch.* vol. 30), WYSS (*ibid.* vol. 36), KLEBS (*Handb. d. path. Anat.* I.), PEPPER (*Centralb. f. d. med. Wiss.* 1871), HJELT (*Schmidt's Jahrb.* 157, 1373).

515. **Inflammation** of the pancreas (pancreatitis) is on the whole a rare condition. Primary and secondary forms are distinguished according to their mode of origin. The former are the rarer and the cause of them often remains undiscovered : the latter are due to the extension of an existing inflammation in contiguous parts, or to a so-called metastasis from some remoter organ.

The slightest degree of inflammation is represented by the swelling of the pancreas occasionally met with in cases of infective disease, and notably in typhoid fever. It is due to an infiltration of the connective tissues with liquid and leucocytes, and in part to cloudy swelling of the gland-cells. When the affection is recent the gland is red and injected ; in cases of some standing it is pale or even white.

In purulent or suppurative pancreatitis some portion, or the whole, of the interacinous (and often the peripancreatic) tissue is transformed into a dirty puriform mass. In later stages there are abscesses of various sizes. It is usually due to suppuration in some neighboring part, as in the lesser omental sac or in the common bile-duct : it is very rarely a primary affection.

Chronic indurative pancreatitis or **cirrhosis** is characterized by thickening and hardening of the connective tissue within the gland. The head of the pancreas is especially apt to be thus affected. When the gland-tissue is thereby destroyed and atrophied the organ as a whole becomes smaller. Indurative pancreatitis is most commonly secondary to inflammations of contiguous parts, such as the peritoneum, common bile-duct, or stomach (in gastric ulcer). In other cases the cause seems to be retention of the secretion or the presence of concretions in the duct. It is rare as a primary affection, though it is said to be sometimes a result of spirit-drinking (FRIEDREICH), and of syphilis congenital or acquired. In a few cases gummatous nodes have been observed.

Tuberculosis of the pancreas is very rare ; though in cases of the general affection caseous nodules are occasionally met with in the gland. Tuberculosis of the lymphatic glands embraced or overlaid by the pancreas is less common.

Carcinoma is the chief of the primary tumors found in the pancreas. It usually gives rise to hard dense nodes seated in the head of the gland. Soft medullary and colloid cancers are rare, as are all forms affecting the middle part or the tail. Sometimes however a cancer starting in the head invades the whole gland, transforming it into a single tumor which may reach a great size. The cancerous infiltration may extend into the surrounding tissues, invading thus the common duct, duodenum, stomach, gall-bladder, spine, lymphatic glands, peritoneum, liver, etc. Numerous metastatic growths are frequently formed in the parts named. When the common bile-duct is attacked, retention of bile and jaundice may result; and the closure of the canal of Wirsung may lead to cystic dilatation of the secretory ducts in the tail of the gland. The adjacent veins, such as the vena cava, portal vein, and superior mesenteric vein, are sometimes encircled and gripped by the cancerous growth; the result is thrombosis or other serious disorder of the circulation.

Primary sarcoma of the pancreas is extremely rare.

Of secondary growths carcinoma is again the only form that needs to be mentioned. Cancer of the stomach and of the duodenum are those which most frequently induce the like in the pancreas. Metastases derived from cancer in more remote organs are much less common.

On pancreatitis see CRUVEILHIER (*Anatomie path.* part xv. vol. i.), KLOB (*Oesterr. Zeitschr. f. pract. Heilk.* vi. 1860), BIRCH-HIRSCHFELD (*Arch. d. Heilk.* 1875), NATHAN (*Medical Times* 2, 1870), CHIARI (*Wien. med. Woch.* 1876, 1880, *Med. Times* 1, 1880), FRAENKEL (*Zeitschr. f. klin. Med.*, 1882). CHIARI observed in several cases complete necrosis and separation of the pancreas. In one case the pancreas was entirely broken down, and escaping by a perforation into the intestine was passed *per anum*. This patient (who recovered) was suffering at the time from gall-stones, so it is possible that the suppurative inflammation of the pancreas was secondary to inflammation of the bile-duct.

On cancer of the pancreas see FRÉRICHS (*Klinik d. Leberkrankh. Diseases of the liver* i., London 1860), E. WAGNER (*Arch. d. Heilk.* 1861), LÜCKE and KLEBS (*Virch. Arch.* vol. 41), DAVIDSOHN (*Ueb. Krebs d. Bauchspeicheldrüse* In. Diss. Berlin 1872), STRÜMPPELL (*Deutsch. Arch. f. klin. Med.* xxii.), MOORE (*St. Barth. Hosp. Rep.* 1881, 1882), LÖSCH (*St. Petersburg med. Woch.* 1883), WESENER (*Virch. Arch.* vol. 93), CHIARI (*Prag. med. Woch.* 1883, a case of secondary sarcoma).

INDEX OF AUTHORS CITED

(The numbers refer to the articles.)

- Ackermann 495, 497, 498
 Addison 261
 Affanasiew 490
 Alexander 479
 Amozan 397
 Arndt 316
 Arnold 296, 332, 342, 501
 Arnott 437
 Arnstein 262, 437, 438
 Assmus 271
 Auerbach 255
 Aufrecht 391, 459, 498
 Auspitz 388, 392

 Babesiu 399
 Balfour 348
 Bamberger 272, 279, 495
 v. Bärensprung 327, 383, 500
 Barker 315, 437, 438
 Barlow 327
 Barwell 308
 Basch 388
 Bateman 400
 Bauer 490
 Bäumler 327, 441
 Baumgarten 255, 295, 314, 342
 Bazin 412
 Behrend 359, 392, 412
 Beigel 397
 Bekmann 391
 Beloussow 498
 Beneke 272, 278, 286, 492, 510
 Bennett (Hughes) 260
 Bergmann 342, 479
 Besnier 322
 Bichat 266
 Bidder 485
 Bienstock 479
 Bierhoff 471
 Biermer 261
 Billard 433, 439
 Billroth 321, 324, 334, 344, 346, 438
 Binz 490
 Birch-Hirschfeld 262, 295, 320, 327, 328,
 358, 391, 457, 490, 495, 500, 502, 515
 Bizzozero 252, 260, 261, 263, 317, 319,
 400
 Block 504
 Boas 262
 Bochdalek 439
 Böck 400

 Böhm 457, 470
 Böhme 358
 Bohn, 383, 433, 434, 439
 Bollinger 262, 400, 433, 436
 Boström 262, 358, 397
 Böttcher 260, 460, 491
 Bouchard 302
 Bramwell (Byrom) 261
 Brault 490
 Brenner 460
 Betonneau 425
 Brieger 479, 498
 Bright 278, 383, 498
 Brinton 460
 Bristowe 295, 495
 Brodowski 391, 490
 Brookhouse 479
 Brücke 253, 453
 Bruns 399, 434
 Bückling 495
 Budd 453, 460, 498, 500
 Buhl 271, 272, 279, 436, 458
 Burckhardt 436
 Burger 362
 † 282
 Bu 402

 Cadet 261
 Caillé 500
 Carl 498
 Caspar 457
 Catiano 262
 Challand 513
 Charcot 260, 302, 303, 304, 383, 498
 Cheyne (Watson) 361
 Chiari 391, 396, 404, 415
 Christison 259
 Church 302, 358
 Chvostek 500
 Clarke 437
 Coats 474
 Cohnheim 261, 277, 279, 324, 328, 344,
 351, 425, 460, 484, 490
 Coleman 440
 Colin 262
 Colucci 492
 Coupland 261
 Cordua 349
 Cornil 258, 292, 296, 328, 332, 342, 344,
 391, 425, 471, 490, 491, 498, 500
 Couty 266

(The numbers refer to the articles)

- Creighton 495
 Crisp 471
 Crooke 474
 Cruveilhier 515
 Curnow 514
 Czerny 308, 399

 Damaschino 470
 Damsch 392
 Dättwyler 460
 Davidsohn 515
 Debove 537
 Demiéville 398
 Demme 261, 433, 454
 Dennis 439
 Désert 315
 Dessoir 437
 Dilg 271
 Dreschfeld 490
 Du Castel 272
 Duckworth (Dyce) 400
 Duhring 359, 367, 377, 392, 396, 399
 Durante 255

 Eberth 281, 282, 316, 326, 328, 332, 344,
 474, 492
 Ecker 408
 Ehrlich 260, 261, 262, 295
 Eichhorst 261, 274, 407
 Eichler 304
 Eichstedt 412
 Elsässer 453
 Eppinger 307, 490
 Erb 260
 Erman 490
 Esoff 397
 Eulenburg 397
 Eve 441
 Ewald 278, 453

 Fagge (Hilton) 277, 309, 399, 400
 Fauconneau-Dufrèsne 514
 Fehleisen 375
 Feltz 479
 Fenwick 453, 460
 Ferrein 511
 Feuerstack 261
 Fiedler 503
 Fiehne 262, 457
 Fischel 320
 Fleischer 260
 Fleischmann 377, 439
 Flournoy 266
 Foà 255, 261, 318, 498
 Förster 271, 404
 Fox (Tilbury) 385, 402
 Fox (Wilson) 460
 Fraenkel 490, 515
 Frankenhäuser 261
 Frerichs 490, 495, 498, 500, 504, 510, 515
 Freund 500
 Friedländer 295, 309, 391, 392, 474, 479
 Friedreich 320, 492, 513, 515

 Gaffky 474
 Gangee 258, 259
 Garrod 259
 Geber 377, 380, 397
 Gee 327
 Georjevic 315
 Gerhardt 327, 397, 460
 Gibler 384
 Gierke 434
 Gies 437
 Giovanni 292, 299
 Gombault 498
 Goodhart 302, 490
 Gosselin 438
 Gowers, 260, 295, 328
 Grawitz 279, 436
 Greenfield 271, 295, 328, 502
 Griesinger 502
 Gross 358
 Gruby 411
 Gubler 500
 Guillebeau 324
 Gull 279
 Günsburg 460
 Gussenbauer 513

 Habershon 498
 Haeckel 348
 Haight 371, 383
 Halford 262
 Hall 391
 Hamilton 255, 259, 266, 324, 498
 Hammerich 439
 Hanot 498
 Hardy 397
 v. Harlingen 367
 Hart 258
 Hauser 460
 Hayem 252, 260, 261, 498
 Hebra 359, 364, 377, 388, 392, 397, 400,
 406, 412
 Heinemann 495
 Heller 315, 396
 Hertwig 348
 Heschl 305, 491
 Heubner 295, 425, 444
 Hillis 392
 Hindenlang 268, 334
 Hintzen 500
 Hippocrates 433
 Hirsch 434, 495
 Hjelt 514
 Hlava 490
 Hobson 261
 Hodgkin 328, 344
 Hoffmann 492
 Holmes 308
 Hoppe-Seyler 258, 259, 262, 509
 Hubner 277, 295
 Hubl 358
 Hulke 437
 Humbert 343
 Humphry 253, 437
 Hutchinson 400, 402, 441

(The numbers refer to the articles)

- Immermann 261
 v. Ins 334
 Israel 279, 292, 299, 436
 Iwanowsky 277
- Jaccoud 292
 Jackson (Hughlings) 295
 Jacobson 266
 Jahn 292
 Jamieson 376
 Jarisch 392
 Johnson 279
 Johnston 514
 Jolly 266
 Junge 288
 Jürgensen 265, 453
- Kaposi 359, 364, 365, 366, 376, 377, 378,
 380, 383, 384, 392, 396, 397, 399, 400,
 402, 406, 407, 410, 411
 Kelsch 262, 334, 502
 Ker 479
 Key 460
 Kiener, 296, 502
 Klebs 260, 262, 281, 303, 314, 315, 343,
 391, 400, 437, 440, 448, 460, 490, 495,
 504, 513, 514, 515
 Klein 318, 320, 474
 Klenke 440
 Klob 515
 Koch 390, 473
 Kocher 466
 Korn 318
 Körte 460
 Kottmann 260
 Köster 292, 299, 316, 391
 Krafft 302
 Krauss 471
 Krieger 272
 Kundrat 453, 470
 Kunkel 268, 317
 Kussmaul 292, 453, 470
 Küssner 498
 Kyber 326, 397
- Laache 258, 261
 Labbé 399
 Laborde 266
 Laennec 498
 Lancereaux 277, 295, 304, 500
 Landau 458
 Landerer 454
 Lang 376, 392
 v. Langenbeck 295, 346, 435
 Langer 364, 396
 Langhans 287, 299, 328, 329, 343, 344,
 345, 399
 Lassar 407
 Laveran 277
 Leber 440
 Lebert 490, 495
 Léger 292
 Legg (Wickham) 490, 498
- Legross 399
 Leichtenstern 258, 469, 479
 Leitz 425
 Leloir 365, 397
 Lépine 261, 314
 Lesser 262, 315, 383, 457
 Letzerich 474
 Leube 260, 263, 453, 460, 470
 Lewaschew 299
 Lewin 367
 Lewinski 315
 Lewitzky 490
 Leyden 262, 281, 284, 288, 490
 Lichtheim 262
 Liebermeister 482, 498
 Limen 457
 Liouville 302
 Litten 261, 324, 484, 498
 Littré 465
 Lorenz 271
 Lösch 314, 515
 Lotzbeck 439
 Lücke 515
 Lyon 258
- Maas 258, 437, 438
 McConnell 495
 Mackenzie (Stephen) 361
 Magendie 266
 Magitot 441
 Maier 261, 271, 282, 292, 454, 455, 470
 Malassez 261
 Manfredi 400
 Mangelsdorf 498
 Mansell-Moullin 266
 Manson 315
 Marchand 262
 Martin 296
 Masius 261
 de Massy 358
 Matterstock 471
 Mauriac 437
 Mayer 453
 Meyer 288, 292, 297, 474
 Mayr 367
 Miller 440
 Moore 402
 Moore (Norman) 515
 Morison 400
 Mosler 260, 262, 322, 327, 328
 Mott (Valentine) 399
 Moxon 277, 297, 490, 500
 Mügge 296
 Müller 261, 272, 460
 Munk 262, 490
 Murchison 328, 343, 490, 495
 Muron 266
- Nathan 515
 Naunyn 453, 490, 504
 Nauwerck 281, 455
 Nedopil 437
 Neelsen 316, 358
 Neisser 262

(The numbers refer to the articles)

- Nelaton 399
 Neligan 437
 v. Nencki 479
 Neumann, 263, 297, 317, 359, 363, 364,
 376, 383, 397, 406, 409, 440
 Nicati 498
 Nieden 315
 Noman 490
 Nothnagel 470, 479

 Oeller 288
 Oertel 425
 Orth 271, 285, 292, 324, 334, 342, 482, 501
 Ossikovsky 490

 Pagenstecher 316
 Panum 460
 Payne 504
 Peacock 271, 272, 309
 Penzoldt 260, 261, 453, 454
 Pepper 514
 Perls 316, 400, 504
 Peters 333
 Peterssen-Borstel 510
 Petters 315
 Pfitzer 308
 Poensgen 453
 Ponfick 260, 261, 262, 266, 268, 302, 314,
 322, 328, 349, 436
 Popoff 498
 Posner 498
 Poster 437
 Potain 343
 Pouchet 261
 Poulin 292
 Prince 513
 Prior 472
 Pullar 359
 Putiata 346
 Putjatin 277
 Pütz 433
 Pye-Smith 261

 Quain 495
 Quincke 261, 268, 304, 315, 317, 350, 460,
 481
 Quinquaud 261

 Raab 255
 Ranvier 258, 261, 292, 328, 332, 425,
 500
 Rauchfuss 271
 Rauschenbach 252
 Rayer 383
 Rebsamen 334
 v. Recklinghausen 349, 392, 397, 398,
 399, 439, 453, 511, 514
 Reess 436
 Rehn 458
 Keil 271
 Reiss 490
 Reubold 436, 439
 Richaud 498
 Riedel 255
 Riess 263

 Rindfleisch 261, 296, 388, 502
 Roberts 513
 Robin 260
 Robinson 376
 Rokitansky 271, 514
 Rosenbach 262, 284, 453
 Ross 383
 Roth 302, 304, 305, 464, 510
 Rottenstein 440
 Rouis 495
 Roy 279, 318
 Ruboni 513
 Ruppert 266
 Russell 361

 Sabourin 498
 Salkowski 479, 490
 Salter 441
 Salvioli 260, 318, 498
 Samuelson 277
 Sanders 259
 Sanderson (Burdon) 328
 Sansom 282
 Schäfer 261
 Scheiber 367
 Scherer 259
 Schmidt 252, 261, 485, 498
 Schönlein 409
 Schreiner 260
 Schuberg 479
 v. Schulthess-Rechberg 277
 Schultz 255, 256, 308
 Schultze 252
 Schultzen 490
 Schulz 344, 358, 490
 Schüppel 342, 491, 500, 504, 510, 512
 Schütte 491
 Schwarck 470
 Schweigger 288
 Schweninger 425
 Schwimmer 437
 Scriba 266
 Seitz 472
 Senator 278
 Senftleben 255
 Simon 400
 Simons 498
 Slavjansky 266
 Socoloff 320
 Soyka 266, 334
 Spatz 272
 Spiegelberg 458
 Spilling 260
 Steffen 504
 Steiner 471
 Stilling 315
 Stöhr 442
 Stroganow 292, 380
 Strümpell 515
 Surre 498
 Sutton 279

 Talma 292
 Tappeiner 262
 Taruffi 271

(The numbers refer to the articles)

- Tautain 277
 Taylor 261, 457, 490
 Teppel 327
 Teuffel 498, 512
 Thierfelder 358, 490, 495, 498
 Thiersch 402
 Thin 367, 380, 392, 400, 402, 407
 Thoma 258, 261, 272, 288, 392, 467
 Thorspecken 453
 Tillmanns 285
 Tizzoni 261, 317, 492
 Touton 371
 Traube 279, 495
 Trélat 437
 Treves 342
 Trompetter 292
 Trousseau 261, 328, 344
 Turner 277, 315

 Unna 371, 385, 388, 404
 Uskoff 440
 Uskow 277

 Vaillard 346
 Vallat 332
 Vanlair 261
 Variot 437
 Verneuil 402
 Virchow 252, 260, 272, 287, 299, 305,
 314, 326, 328, 332, 334, 343, 344, 392,
 399, 400, 425, 437, 438, 439, 441, 457,
 460, 483, 495, 500, 514
 Vogel 437
 Voit 485, 490

 Wagner 316, 327, 358, 383, 425, 436, 470,
 491, 498, 500, 515
 v. Wahl 453
 Waldeyer 260, 316, 358, 490, 504
 Waldstein 261
 Wardell 322

 Warren 399, 402
 Weber 437, 428, 500
 Wedl 440
 Wegner 315, 437, 438, 490
 Weidner 383
 Weigert 288, 296, 314, 324, 371, 388,
 425, 504
 Weir 437
 Wernich 474
 Wesener 515
 Wever 327
 Weyl 400
 Whitehead 470
 Whitley 500
 Wiederhöfer 453, 458
 Wieger 332
 Wienkowski 315
 Wiktorowsky 460
 Wilks 261, 277, 297, 321, 328, 491, 500
 Wilson (Erasmus) 408
 v. Winiwarter 292, 343, 346, 438, 490
 Winkel 262
 Winogradow 318
 Winternitz 367
 Wölfler 471
 Woodhead (Sims) 436
 Woodward 470
 Wooldridge 252
 Wulff 504
 Wunderlich 343
 v. Wyss 383, 490, 498, 514

 Zaeslein 261
 Zahn 252, 261, 425, 482
 Zander 279
 Zenker 260, 261, 304, 449, 490, 498, 513
 Ziegler 255, 268, 277, 281, 288, 375, 376,
 388, 437, 444
 v. Ziemssen 449, 460
 Zunder 490

INDEX OF SUBJECTS

(The numbers refer to the articles)

- abnormalities of the heart 270 sqq
abscess, alveolar 440
 of liver 493 sqq
 of œsophagus 450
 of spleen 322, 324
 of stomach 457
 of tonsils 442
 tuberculous 428
absorption by peritoneum 349
 of serous effusion 352
acarus scabiei 413
achorion Schönleinii 410
achroma 365
acids, corrosion by 450, 457
acne 405
 albida 404
 mentagra 405
 rosacea 360
 sebacea 403
actinomycosis 436
Addison's disease 362
adenia 323, 344
adenocarcinoma 431, 462, 478, 512
adenoma, false 422
 of intestine 478
 of liver 502
 of mucous membrane 431
 of sweat-glands 402
adhesive inflammations 352
ægagropili 479
ague-cake 321
air in blood 265, 266
albinism 365
alimentary tract Sect. VII.
alkalies, corrosion by, 450, 457
alopecia 407
alveolar abscess 440
 colloid of liver 507
amyloid change of heart 275
 change of liver 491
 change of lymphatic glands
 332
 change of mucous membrane
 417
 change of spleen 325
 change of vessels 288
anæmia 258, 261
 of liver 483
anæmic necrosis from atheroma 300
anastomotic aneurysm 289, 301
anchylostoma duodenale 479
aneurysm ch. XVI.
 aneurysm, dissecting 309
 false 308
 of heart 284
 aneurysmal varix 301, 311
 angina 442
 Ludovici 447
 angioma 312
 of liver 504
 of mouth 438
 of skin 401
 anhydræmia 258
 anthrax, intestinal 477
 simplex 405
 specific 390
 anus, imperforate 464
 aorta, aneurysm of 303
 degeneration of 287
 inflammation of 292
 primitive 270
 aortic bulb 270, 271
 aortitis, acute 292
 aphthæ 433
 aphthous stomatitis 433
 apoplexy 304
 pancreatic 513
 archenteron 348
 area Celsi 407
 argyria 362
 arterial trunks, defects of 271
 hæmatoma 308
 arterio-capillary fibrosis 279
 arterioles, hyaline change in 288
 arteritis 291, 292
 deformans 299
 syphilitic 295
 ascaris lumbricoides 479
 mystax 479
 ascites 350, 497
 asteatosis 403
 atheroma causing aneurysm 302
 of endocardium 276
 of vessels 288, ch. XV.
 (sebaceous) 404
 atheromatous ulcer 297
 atresia ani 464
 of great vessels 271
 of intestine 468
 atrophic pigmentary induration of sto-
 mach 456
 cirrhosis of liver 498
 atrophy in mouth 437
 of heart 273

(The numbers refer to the articles)

- atrophy of intestine 468, 470
of liver 483, ch. LVIII.
of liver, acute yellow 489, 490
of lymphatic glands 331
of mucous membrane, 417
of stomach 455
of spleen 325
of vessels 288
- autochthonous thrombus 253
- bacilli in cholera 473
of anthrax 390
of typhoid 474
- bacillus of tubercle in glands 342
of tubercle in vessels 296
- bacon liver 491
spleen 325
- bacteria in catarrh 420 (see bacilli, micrococci)
in endocarditis 281
in erysipelas 375
in hepatic abscess 494
in intestine 479
in leprosy 392
in lymphatic glands 335
in pemphigus 384
in phlegmon 390
in purpura hæmorrhagica 36
in small-pox 388
in splenic abscess 322, 324
in stomach 453
in syphilis 391
- bacterium decalvans 407
- baldness 407
- barber's itch 411
- bedsores, gangrenous 390
- belladonna-rash 367
- bezoars 479
- bile in blood 259, 268
ducts, cancer of 503
ducts, inflammation etc. of ch. LXII.
new-formed 497
pigment 481
pigment in gall-stones 508, 509
- bilharzia in blood 265
- biliary abscess 493, 495
colic 510
concretions 508 sqq
hepatitis 498
- bilirubin 268
in gall-stones 508, 509
- biliverdin in gall-stones 508, 509
- blebs 370
- blisters 370, 371, 372, 381
- blood, a tissue 251
air in 265, 266
changes in ch. III.
coagulation of 252
composition of 251, 258
corpuscles, changes in ch. IV.
hyperplasia of 258
impurities in ch. v.
parasites in 265, 266
plates 252, 261, 263
- blood vessels, wounds of 256 (see vessels)
and lymph Sect. I.
and lymph, functions of 251
- bloody sweat 361
Blutplättchen 252, 261, 263
- body-cavity, development of 348
- boils 405
- bothriocephalus latus 479
- brain-disease, lymphatics in 269
- Bright's disease and cardiac hypertrophy 279
disease and vascular hypertrophy 289
- bronzed skin 562
- brown atrophy of heart 273
- bubo 391
hard syphilitic 342
suppurating 337
- burn, blisters from 370, 372, 381
- burns, effect on blood 262
- cadaveric poison 390
- calcareous deposits in bile-ducts 508 sqq
deposits in pancreatic ducts 514
deposits in vessels 288
- calcification of lymphatic glands 333
of thrombi 254
of vessels 288, 297
- ca culi, biliary 508 sqq
intestinal 479
pancreatic 514
- calculus, salivary 448
- callosities 394
- canal of Wirsung 513
- canalization of thrombus 255
- canals, biliary 480
- cancer, endothelial 316, 358 (see carcinoma)
of lymphatic glands 347
of serous cavities 358
of skin 402
- cancroid 402
dry 404
- cancrem oris 434
- canities 365
- cantharides, blisters from 381
gastric ulcer from 459
- capillary aneurysms 305
ectasis 305
- capsule of Glisson 480
- caput medusæ 497
- carbonic acid poisoning 259
oxide poisoning 259
- carbuncle 405
- carcinoma of intestine 478 (see cancer)
of liver 503
of mucous membrane 431
of œsophagus 451
of pancreas 515
of serous membrane 358
of skin 402
of stomach 461, 462
- cardiac ganglia, changes in 277

(The numbers refer to the articles)

- cardiac hypertrophy and renal disease 279
 hypoplasia 272
 malformations 271
 polypus 253, 277
 thrombosis 253
- caries of teeth 440
- caseation of lymphatic glands 332, 333, 342
- catarrh of intestine 470
 of mucous membrane 420, 421
 of œsophagus 450
 of stomach 456
- catarrhal stomatitis 433
- cavernous angioma of liver 504
- cellulitis 390
- central red atrophy of liver 483
- cercomonas intestinalis 479
- chancre (hard) 391
 (soft) or chancroid 391
- Charcot's crystals 260
- chicken-pox 388
- chilblains 367, 389
- chloasma 362
- chlorosis, anæmia of 258, 261
 hypoplasia in 272, 286
- cholecystitis 512
- cholera 473
 anhydræmia in 258
- cholesterin in gall-stones 508, 509
- chronic ulcer of stomach 459
 ulcer of duodenum 471
- chylous ascites 350
- ciatrix in blood-vessel 255, 256
 syphilitic, of liver 499
- cinnabar in blood 266, 267
- cirrhosis of liver 497 sqq
 of pancreas 515
- cirroid aneurysm 301
- clavities 407
- clavus 394
- clots, post-mortem 253
- cloudy swelling of heart 274
 swelling of liver 488
- coagulation, intravascular ch. II
- coal-dust in blood 265, 266, 267
- coeliac flux 472
- colic, biliary 510
- colitis 471
- colloid cancer of intestine 478
 cancer of stomach 462
 alveolar 507
- comedones 404
 of mouth 439
- composition of blood 251
- concentric hypertrophy 278
- concretio pericardii 353
- concretions, biliary 508
 intestinal 479
 pancreatic 514
 salivary 448
- condyloma acuminatum 394
 endocystic 400
 latum 379
- congenital hernia 465
 congenital syphilis of liver 500
 congestion of liver 483
 of spleen 319
 contraction of stomach 454, 460
 copaiba-rash 367
 cor villosum 352
 corns 394
 cornu cutaneum 394
 coronary embolism 271
 corpora Arantii, degeneration of 276
 corpuscles, changes in ch. IV.
 corrosion of œsophagus 450
 of stomach 457
 corrosive poisons on skin 389
 croupous inflammation of intestine 472
 inflammation of mucous membrane 423
 inflammation of œsophagus 450
 inflammation of stomach 457
- crural hernia 465
- crustæ 368, 373
- cuniculi in scabies 413
- cutis ænea 362
- cyanosis 271
- cyanotic atrophy of liver 483
- cylindrical aneurysm 301
- cystic hygroma 438, 439
 sarcoma 448
- cysticercus of heart 295
 of serous membranes 358
- cysts of intestine 464, 470
 of jaws 441
 biliary 511
 mucous 422, 439, 446
 pancreatic 514
 serous 358
- dandriff 403
- decubital necrosis of pharynx 450
 necrosis of skin 390
- defects of the heart 270
 of the vessels 271
- degenerations of heart ch. VIII.
 of liver ch. LVIII.
 of lymphatic glands ch. XXIV.
 of pancreas 514
 of spleen ch. XXI.
 of vessels ch. XII.
- demodex folliculorum 404
- dental osteoma 441
- dentigerous cysts 441
- dermatitis ch. XXXVIII.
 contusiformis 367
 exfoliative 377
- dermatolysis 399
- dermatomycosis 409
- dermoid tumors 358
- desquamation 373
- destruction of blood-corpuscles 262, 263, 318
- dexiocardia 272
- diabetes, lipæmia in 259
- diaphragmatic grooves on liver 482

(The numbers refer to the articles)

- diaphragmatic hernia 467
 diffuse aneurysm 301
 dilatation of bile-ducts 510, 511
 of capillaries 305
 of heart ch. IX.
 of intestine 468
 of œsophagus 449
 of pancreatic ducts 514
 of stomach 453, 454
 diphtheria 443, 444
 and myocarditis 284
 diphtheritic endocarditis 281, 282
 inflammation of intestine 470
 inflammation of mucous membrane 424, 425, 443
 inflammation of œsophagus 450
 inflammation of stomach 457
 discoloration of skin 362
 disintegration of blood-corpuscles 262, 268, 318
 dissecting-room warts 390
 diverticula of intestine 464, 468
 of œsophagus 449
 dochmius duodenalis 479
 dropsy of gall-bladder 511
 of serous cavities 350
 dry inflammation of serous membranes 352
 ductus arteriosus 271
 Botalli 271
 duodenitis 471
 duodenum, ulcer of 471
 dyschromatosis 362
 dysentery 421, 472
 hepatic abscess in 493

 ecchymoma 361
 ecchymoses 361
 echinococcus of heart 285
 of liver 507
 of serous membranes 358
 ectasis 305
 ecthyma 385
 ectopia cordis 272
 eczema 385
 marginatum 411
 efflorescence of skin-disease 368
 effusion in serous cavities 350, 354
 elephantiasis arabum 315, 395, 396
 congenital 399
 græcorum (see leprosy)
 of lymphatic glands 341
 embolic abscess 257, 267
 aneurysm 302
 embolus 257, 263, 267, 282
 of spleen 324
 empyema 354
 encephaloid (medullary) cancer of stomach 462
 enchondroma of skin 401
 endarteritis 293

 endocarditis ch. x.
 endocardium, degeneration of 275, 276
 endocystic condyloma 400
 endophlebitis 293
 endothelial cancer 316, 358
 endothelioma 316
 melanodes 504
 endothelium of serous cavities, its nature 348
 of vessels as impurity in blood 263
 of vessels in organization 255
 of vessels in thrombosis 253
 enlargement of heart 278
 of liver, 492, 498
 of lymphatic glands 338
 sq
 of spleen 321, 323, 327 etc.
 engorgement of liver 483
 of spleen 323
 enteric fever 474
 enteritis 470
 enterocystoma 464
 enteroliths 471, 479
 enteromycosis bacteritica 477
 eosinophilous cells 260
 ephelis 362, 398
 epidermal pearls 398
 epidermidophyton 376
 epithelial catarrh 420
 epithelioma (adenocarcinoma) 431
 (cancerous) 402
 molluscum 400
 of mouth 438
 epulis 438, 441
 erysipelas 375
 erysipelatos stomatitis 433
 erythema 360, 366
 multiforme 367
 nodosum 367
 essential anæmia 258
état mamelonné of stomach 456
 eustachian valve, development of 270
 exanthemata, rash in 367
 excentric hypertrophy 278
 exfoliative dermatitis 377
 extraneous matters in blood 265
 matters in lymphatic glands ch. XXVII.
 exudation from serous membranes 350, 354
 in skin-disease 368

 fæcal abscess 468, 471
 fæces, parasites in 479
 false adenoma 422
 aneurysm 308
 membranes in croupous inflammation 423
 membranes in serous inflammations 352
 fat in blood, 259, 264, 266

(The numbers refer to the articles)

- fatty degeneration of endocardium 275
 degeneration of heart 274
 degeneration of liver 488
 degeneration of lymphatic glands 332
 degeneration of pancreas 514
 degeneration of vessels 287
 enlargement of heart 279
 liver 489
- favus 410
- femoral hernia 465
- fenestration of valves 282
- ferro-albuminoids 268
- fibrin 252
- fibrinogen 252
- fibrinoplastin 252
- fibrinous blocks in spleen 324
 inflammation of serous surfaces 352
- fibroblastic cells in organization 255
 cells in arteritis 295
- fibroid induration of heart 277
 induration of liver 496 sqq
 induration of lymphatic glands 341
 induration of pancreas 515
 induration of spleen 321
 induration of stomach 445
- fibroma molluscum 399
- fibroneuroma 504
- fibrous hyperplasia of liver 496 sqq
 hyperplasia of lymphatic glands 341
 hyperplasia of mucous membranes 422
 hyperplasia of stomach 456
- filaria in blood 265, 395
- fistula in ano 471
 salivary 448
- floating liver 482
- foetal inclusions 358
- follicular ulceration 442
 ulcers 470
- folliculitis barbæ 405
- foot-and-mouth disease 433
- foramen ovale 270
- foreign bodies in lymphatic glands 334, 335
- freckles, 362, 398
- fungi in stomach 453
- fur of tongue 433, 437
- furfuraceous desquamation 373
- furunculi 405
- fusiform aneurysm 301
- gall-bladder, anomalies of 482
 bladder, dropsy of 511
 bladder, inflammation of 512
- gall-stones 508
- gangrene, hospital 390
- gangrenous bed-sores 390
 inflammation 426, 445
- gastradenitis 459
- gastric polypi 455 (see stomach)
 ulcer 459
- gastritis 456
- gastromalacia 453
- gelatinous cancer of stomach 462
- glanders of mucous membrane 430
- glossitis 434
- glossocele 437
- glossophytia 437
- glycocholic acid 481
- glycogen 481
- gonorrhœal endocarditis 281
- granular (cirrhotic) liver 497 sqq
- grayness of hair 365
- grutum 364, 404
- gum-bol 434, 440
- gummata of heart 285
 of liver 499, 500
 of spleen 327
 of throat 444
 of vessels 295
- gummatous hepatitis 500
 ulcer 391
- hæmatidrosis 361
- hæmatoblasts 252, 261, 263
- hæmatoidin 268
- hæmatoma 306, 361
 arterial 308
 of pancreas 513
- hæmoglobin, proportion in blood, 258, 261
 proportion in blood after removal of spleen 318
- hæmoglobinuria, after hæmorrhage 349
 epidemic 262
 intermittent 262, 268
- hæmophilia, hypoplasia in 272
- hæmorrhage, aneurysmal 304
 from mucous membranes 416
 from serous membranes 349
 of pancreas 513
 of stomach 458, 460
- hæmorrhages of skin 361
- hæmorrhagic erosion of stomach 458
 infiltration of liver 484
 inflammation of serous membranes 352
- næmorrhoids 306
- hair, disorders of 407, 408
 balls 479
- hairy men 408
 tongue, 437
- heart, abnormalities of 270 sqq
 aneurysm of 289
 atrophy of 273
 degeneration of ch. VIII.
 dilatation of ch. IX.
 hypertrophy of ch. IX.
 hypoplasia of 272
 inflammations of ch. X.
 malformations of ch. VII.
 misplaced 272
 parasites of 285

(The numbers refer to the articles)

- heart, rupture of 274, 277
 sclerosis of 277
 size of 272, 278
 tumors of 285
- heat, effect of, on skin 381
 effect of, on blood 262
- hepar mobile 482
- hepatic abscess 493, 494, 495
 artery, closure of 484
- hepatitis ch. LX.
 artificial 498
 biliary 498, 512
 gummatous 500
 indurative 496 sqq
 purulent 493 sqq
 sequestrans 498
 syphilitic 499, 500
 tuberculous 501
- hernia 464, 465
- hernial aneurysm 302, 303
- herpes circinatus 367, 383
 iris 367, 383
 simplex, labialis etc. 383
 tonsurans 383, 411
 zoster 371, 383
- hide-bound condition 396
- hirsuties 408
- hob-nailed liver 497, 498
- Hodgkin's disease 328, 344
- horns of the skin 394
- hospital gangrene 390
- Hunterian chancre 391
- hyaline change of heart 276
 change of lymphatic glands 332
 change of vessels 288
- hydatids of heart 285
 of liver 507
 of serous membranes 358
- hydræmia 258
- hydropericardium 350
- hydrothorax 350
- hygroma, cystic 438, 439
- hypalbuminosis 258
- hyperæmia of liver 483
 of mucous membranes 415
 of serous membranes 349
 of skin 360
 of spleen 319
 of spleen, passive 323
- hyperinosis 258
- hyperplasia of heart 278
 of liver 492
 of lymphatic glands 341
 of mucous membrane 418
 of skin 393
 of spleen 328
 of vessels 289
- hypertrichosis 408
- hypertrophic cirrhosis of liver 498
- hypertrophy of heart 278, 279
 of liver 492
 of stomach 455
 of tongue 437
 of vessels 289
- hyphomycetes in skin 409
- hyphomycetes in stomach 453
- hypoplasia of heart 272
 of spleen 321
 of vessels 286
- ichthyosis 397
 sebacea 403
- icterus 259, 471, 498, 512 (see jaundice)
 gravis 490
- idiopathic anæmia 258, 261
 skin-diseases 359
- ileitis 471
- imperforate anus 464
- impetigo 385
- impurities in blood ch. v.
- incarcerated hernia 466
- incompetence of the ostia venosa 270,
 283
- induced thrombus 253
- indurated chancre 391
- induration of heart 277, 284 (see fibroid)
 of lymphatic glands, 337,
 340
- indurative hepatitis 496 sqq
 pancreatitis 515
- infarction of spleen 324
- infective granulomata of mucous mem-
 brane ch. XLVII.
- inflammations of gall-bladder 512
 of heart ch. x.
 of intestine 470, 471, 473
 of liver ch. LX.
 of lymphatics 314
 of mouth 433
 of mucous membranes
 ch. LXVI.
 of œsophagus 450
 of pancreas 515
 of serous membranes
 ch. XXXII.
 of skin ch. XXXVIII.
 of spleen 320
 of stomach 456
 of throat ch. L.
 of vessels 290
- inguinal hernia 465
- initial sclerosis of syphilis 391
- injuries of liver 482
 of spleen 320, 326
 of vessels 256
- internal hernia 467
- interstitial hepatitis 496 sqq
- intestinal calculi 479
 mycosis 477
 obstruction 467
- intestine ch. LIV.
 anomalies of 464
 cancer of 478
 concretions of 479
 hernia of 465, 466
 inflammations of 470 sqq
 mycosis of 477
 parasites of 479
 syphilis of 476
 tuberculosis of 475

(The numbers refer to the articles)

- intestine, tumors of 478
 intima in thrombosis 253
 intussusception 469
 iron-compounds in blood 268
 compounds in liver 481
 compounds in lymphatic glands 334
 compounds in spleen 318
 ischiatic hernia 465
 itch, barber's 411
 common 413
 jaundice 259, 362, 512
 catarrhal 471
 from cirrhosis 498
 malignant 490
 keloid 399
 Addison's 399
 cicatrical 399
 keratoma 397
 Laennec's cirrhosis 498
 lardaceous liver 491 (see amyloid)
 spleen 325
 large-celled hyperplasia of lymphatic glands 340
 lenticular syphilide 379
 lentigo 362, 398
 leprosy 392
 Lombardian 367
 of mucous membrane 430
 leucin in acute atrophy of liver 489, 490
 in blood 259
 leucocythæmia 260
 leucocytosis 260
 leukæmia 260, 328, 343, 344
 leukæmic hyperplasia of spleen 328
 infiltration of liver 480
 leukoderma 365
 leukopathia 365
 leukoplakia 437
 lichen 406
 hæmorrhagicus 361
 pilaris 397
 syphiliticus 379
 urticatus 367
 lienal leukæmia 260, 328
 ligature, thrombosis from 275
 lineæ albicantes 364
 lingual psoriasis 437
 lipæmia 259
 lipoma of mouth 438
 of skin 401
 lipomatosis of heart 279
 of liver 478
 of pancreas 514
 Littré's hernia 465
 livedo 360
 liver Sect. VIII.
 amyloid 491
 anomalies of 482
 atrophy of ch. LVIII.
 degeneration of ch. LVIII.
 disorders of circulation in ch. LVII.
 liver, enlargement of 492
 floating 482
 gumma of 499, 500
 hydatid of 507
 hypertrophy of 492
 inflammations of ch. LX.
 leukæmic infiltration of 480
 metabolism in 481
 parasites of 507
 pigmentation of 480
 structure of 480
 syphilis of 499, 500
 tuberculosis of 501
 tumors of ch. LXI.
 wounds of 482
 livor 360
 Lombardian leprosy 367
 lupus erythematosus 380
 of mouth 435
 of mucous membrane 430
 of skin 392
 of throat 446
 lymph, changes in 269
 functions of 251, 269
 lymphadenitis ch. XXVIII.
 lymphadenoma 344, 345
 lymphangiectasis 315, 396
 lymphangioma, 316, 438, 504
 lymphangitis 314
 with chancroid 391
 lymphatic glands. Sect. III.
 glands, degenerations of ch. XXIV.
 glands, inflammations of ch. XXVIII.
 glands in leukæmia 260
 tumors of ch. XXIX.
 lymphatics in brain-disease 269
 morbid changes in ch. XVIII.
 radicles of 269
 lymphorrhagia 315, 396
 lymphosarcoma, 344, 345
 lymphoma 338, 343
 malignant 260, 343, 344
 macrocheilia, 315, 437
 macrocytes 261
 macroglossia 315, 437
 malaria, melanæmia in 262
 spleen-changes in 321
 malformations of the heart ch. VII.
 of vessels 2 6
 malignant adenoma (see adenocarcinoma)
 pustule 390
 malpighian follicles, new-formed 318
 follicles of spleen 317
 mal rosso (del sole) 367
 malum senile arteriarum 299
 marasmic thrombosis 253
 marrow in leukæmia 260
 measles 367
 meat-poisoning 477
 Meckel's diverticulum 464, 465
 mediastinal tumors 358

(The numbers refer to the articles)

- medullary cancer of stomach 462
 leukæmia 260
 melæna neonatorum 458
 melanæmia 262
 melanosarcoma of liver 504
 membranaceous desquamation 373
 mentagra, acne 405
 mesarteritis 293
 mesophlebitis 293
 methæmoglobin 259
 micrococci in acute yellow atrophy 490
 (see bacteria)
 in arteritis 291
 in diphtheria 444
 in dysentery 472
 in endocarditis 281
 in erysipelas 375
 in gangrene of skin 390
 in hepatic abscess 493, 494
 in lymphatics 269
 in phlebitis 291
 in purulent effusion 354
 in small-pox 388
 in softening of thrombi 254
 in syphilis 391
 microcytes 261
 microcythæmia 261
 microsporon furfur 412
 miliaria crystallina 382
 miliary aneurysms 303
 syphilide 379
 milium 364, 404
 of mouth 439
 milk-spot of pericardium 352
 mitral stenosis 283
 moles 362, 398
 sarcoma in 401
 molluscum bodies 400
 contagiosum 400
 elephantoid 399
 monads in intestine 479
 morbilli 367
 morbus maculosus Werlhofii 361
 morels (mushrooms) on blood 262
 mother's marks 398
 mouth ch. XLIX.
 mucoid change of heart 276
 mucous cysts 422
 membranes Sect. VI.
 membranes, atrophy of 417
 membranes, degeneration of 417
 membranes, hæmorrhage from 416
 membranes, hyperæmia of 415
 membranes, hyperplasia of 418
 membranes, hypertrophy of 418
 membranes, inflammations of ch. XLVI.
 membranes, structure and functions of 414
 patches 379
 mucus corpuscles 414
 muguet 436
 mumps 447
 mycoderma vini 436
 mycosis microsporina 412
 myelogenic leukæmia 260
 myocarditis ch. X.
 myomalacia cordis 277
 myxoma of skin 401
 nævus pigmentosus 362, 398
 nails, disorders of 407, 408
 neck of hernial sac 465
 necrobiosis of vessels 288
 necrogenic warts 390
 necrosis of lymphatic glands 333, 337
 of mucous membrane 417, 426
 of pharynx 450
 of skin 389
 of vessels 288, 291
 neurofibroma 399
 neuromata, false 399
 papillary 399
 neuropathic papilloma 397
 nitrite of amyl on blood 262
 nitrobenzol on blood 262
 noma 434
 nucleated red corpuscles 260, 261
 nutmeg-liver 483, 487
 obesity of heart 279
 obliterating thrombus 253
 obturator hernia 465
 occlusion of lymphatics 315
 of vessels 307
 of vessels in liver 484
 odontoma 441
 œdema of skin 360
 œsophagus ch. LII.
 oïdium albicans 436
 oligæmia 258
 oligocythæmia 258, 251
 omentum, hernia of 465 sqq
 tuberculosis of 356
 onychogryphosis 408
 onychomycosis 408
 favosa 410
 tonsurans 411
 organization of thrombi 255
 osteoma, dental 441
 ostia, defects at 270
 oxyuris vermicularis 479
 pachydermatocele 399
 pachydermia 395
 palate, soft ch. L.
 panaritium 390
 pancreas ch. LXIII.
 papilloma of mucous membrane 422, 446
 of stomach 455, 456
 papillomata, inflammatory, 394
 neuropathic 397
 papulæ 366
 papular syphilide 379
 paraglobulin 252
 paramœcium coli 479
 parasites in blood 265

(The numbers refer to the articles)

- parasites of intestine 479
of heart 285
of mouth 436
of liver 507
of skin ch. XLII.
- parchment-skin 364
- parietal thrombus 253
- paronychia 390, 408
- parotitis, epidemic 447
- paroxysmal hæmoglobinuria 262
- parulis, 434, 440
- pearls, epidermal 398
- peliosis rheumatica 361
- pellagra 367
- pemphigus 334
syphiliticus 386
- pentastoma in liver 507
in spleen 329
- perforating ulcer of stomach 459
ulcer of duodenum 471
- perforation of intestine 468
of œsophagus 449, 51
of stomach 460
of valves 282
- periarteritis 293
causing aneurysm 302
- pericarditis 352, 353, 354
tuberculous 357
- pericardium, development of 348
- perihepatitis, syphilitic 500
- perilymphangitis 314
- perineal hernia 465
- periphlebitis 293
- periproctitis 471
- perisplenitis 321
- peritoneal absorption 349
fascia of hernia 465
- peritoneum, development of 348
- peritonitis 352, 353, 354
deformans 353, 454
tuberculous 357
- perityphlitis 471
- perniones 367, 389
- petechiæ 361
- Peyer's patches 346
in typhoid 474
- pharyngitis 442
- pharyngocele 449
- pharynx ch. LII.
- phlebitis 291, 293
- phleboliths 254, 306
- phlegmonous inflammation of mucous
membranes 427
inflammation of œsopha-
gus 450
inflammation of skin 390
inflammation of stomach
457
inflammation of the throat
445
- phlyctænoses 368
- phosphorus-poisoning 434, 490
- phthisis, minute aneurysms in 303, 304
tuberculous pleurisy in 356, 357
- pigment in blood, 265 ch. v.
- pigment in brown atrophy 273
in lymphatic glands 334, 335
- pigmentary atrophy of liver 486
infiltration of liver 480
induration of stomach, 456
- pigmentation of skin 362
- piles 306
- pits of small-pox 374, 387
- pityriasis rosea 412
rubra 374, 377
- pityriasis tabescentium 364, 403
versicolor 412
- plaques opalines 435, 437
- plethora 258
- pleura, development of 348
- pleurisy 352, 353, 354
tuberculous 357
- poikilocytosis 261
- poliosis 365
- polyæmia 258
- polyposis ventriculi 456
- polypous growths of mucous mem-
brane 418
growths of intestine 470, 478
growths of the stomach 455,
456
- polypus of heart 253, 277
- polytrichia 408
- popliteal aneurysm 303
- porrigo decalvans 407
- portal vein, closure of 484
vein, engorgement of 497
- post-mortem clots 253
- potassium chlorate on blood 262
- proctitis 471
- primary thrombus 253
- prolapse 464
of bowel (anus) 469
of the tongue 437
- prurigo 377
- pseudo-diphtheritis 424
- pseudoleukæmia 260, 261, 323, 344.
- psoriasis 376
syphilitic 379, 435, 437
- puriform softening of thrombi 254
- purpura, blood-changes in 261, 268
hæmorrhagica 361
papulosa 361
rheumatica 361
scorbutica 361
senilis 361
simplex 361
variolosa 361, 387
- purulent arteritis 291
catarrh 420
hepatitis 493
myocarditis 284
phlebitis 291
- pustulæ 368, 372
- pustulation 372, 388
- pustule, malignant 390
- pyæmia, from thrombosis 291
spleen-change in 320, 322
- pylephlebitis 484
- pylorus, stenosis of, 453, 454, 460

(The numbers refer to the articles)

- pyrogallie acid on blood 262
- quinine-rash 367
- racemose aneurysm 289, 301
- ranula 439, 448
pancreatic, 514
- rash from medicaments 367
specific fevers 357
- ray-fungus 436
- rectum (see intestine)
syphilitic disease of 476
- red atrophy of liver, acute 489
atrophy of liver, central 483
corpuscles, genesis of 261, 318
corpuscles, nucleated 260, 261
corpuscles, destruction of 262, 268, 318
softening of thrombi 254
- regurgitation 279, 283
- renal disease and cardiac hypertrophy 279
- reticular induration of lymphatic glands 341
- retroperitoneal hernia 467
- rhagades 373
- rheumatic endocarditis 281
- rhinophyma 400
- rhythmic contraction of spleen 318
- rice-water stools 473
- ringworm, common 411
crusted 410
- rodent ulcer 402
- roseola 360, 367
furfuracea herpetiformis 412
- round ulcer of duodenum 471
ulcer of stomach 459
- rubeola 367
- rupia syphilitica 386, 391
- rupture of heart, 274, 277, 258
of œsophagus 449
of spleen 320, 326
of vessels 308
(hernial) 465
- sac of hernia 465
- saccharomyces albicans 436
- sacculated aneurysm 301
- sago spleen 325
- salivary calculus 448
fistula 448
glands ch. LI.
- saprophytes in mouth 436
- sarcoma of liver 504
of lymphatic glands 346
of mouth 438
of skin 401
- scabies 413
- scabs 373
- scales 373
- scar, syphilitic, of liver 499
- scarlatina 367
- scirrhous of stomach 462
- sclerema neonatorum 396
- scleroderma 396
- sclerosis of heart 277, 284
of vessels 293, ch. xv.
of vessels causing aneurysm 302
- scrofulous lymphadenitis 339
ulcer 391
- scurvy 361
blood-changes in 361
- scutula of favus 410
- scybala 471
- sebaceous cysts 404
disorders ch. XLI.
wart 400
- seborrhœa 403
- secondary thrombus 253
- senile atheroma 299
atrophy of skin 364
- septa of the heart, anomalies of 270
- serous cavities, development of ch. xxx.
cysts 358
membranes Sect. IV.
membranes, effusion from 350
membranes, hyperæmia of 349
membranes, inflammations of 351
membranes, parasites of ch. XXXIV.
membranes, tuberculosis in ch. XXXIII.
membranes, tumors of ch. XXXIV.
- serpent-venom on blood 262
- shellac-concretion in intestine 479
- shingles 383
- siderosis 263
- siliquose desquamation 373
- simple atrophy of liver 485
- situs transversus (heart) 272
transversus (liver) 482
- skin, atrophy of ch. XXXVII.
discoloration of ch. XXXVII.
diseases of Sect. V.
functions of 359
hyperæmia of 360
hyperplasia of 393, 397
inflammations of ch. XXXVIII.
inflammatory hypertrophy of ch. XXXIX.
parasites of ch. XLII.
tumors of 399 sqq
ulcers of 391
- skin-diseases, classification of 359
- small-pox, 361, 372, 374, 387
- softening of heart 277
of œsophagus 449
of stomach 453
of thrombus 254, 257
- spasm of œsophagus 449
- spleen, changes in Sect. III.
congestion of 319
degenerations of 325
engorgement of 323
enlargement of 321, 323, 327, etc.
granulomata of ch. XXII.
hyperplasia of 328

(The numbers refer to the articles)

- spleen in leukæmia 260, 328, 329
inflammation of 320
rupture of 320, 326
structure and functions 317, 318
suppuration of 322
tumors of 329
- splenic abscess 322
- spleniculus, 317
- splenitis 320
- spurious aneurysm 308
- squamæ 368
- starvation, liver in 485
- steatoma 404
- steatorrhœa 403
- steel-dust in blood 265, 268
- stenosis of the great vessels 271, 279
of the ostia venosa 270, 282
of intestine 468
of œsophagus 449
of pylorus 453, 454
- stomach ch. LIII.
anomalies of 454
cancer of 461
corrosion of 457
dilatation of 453, 454
erosion of 458
fermentation in 453
hæmorrhage of 458
hypertrophy and atrophy of 455
induration of 456
inflammations of 456, 457
polypi of 455, 456
softening of 453
tumors of 461
ulcer of 456, 459
- stomata of serous surfaces 348
- stomatitis 433
- strangulation of hernia 466
- stricture of œsophagus 449
of pylorus 453, 454
- sudamina 382
- sulphuretted hydrogen poisoning 259
- sulphuric acid on blood 262
- sun-burn 362
- sun-spots 362
- sun-stroke, anhydræmia in 258
- suppurating bubo 337
- suppuration of liver 493 sqq
of lymphatic glands 337
of mouth 434
of pancreas 515
of spleen 322
- “suppuration of the blood” 260
- suprarenals in Addison's disease 362
- sweat-glands, adenoma of 402
- sycosis nonparasitaria 405
parasitaria 405, 411
- symptomatic skin-diseases 359
- syphilides, papular 379, 391
pustular 386
- syphilis of intestine 486
of mouth 435
of mucous membranes 429
of throat 446
- syphilitic arteritis 295
bubo 342, 391
chancre 391
enlargement of spleen 327
hepatitis 499, 500
teeth 441
- syphiloma of heart 285
of liver 500
- tænia cucumerina 479
mediocanellata (saginata) 479
nana 479
solum 479
- tartar of teeth 440
- tattooing, 334, 362
- taurocholic acid 481
- teeth, changes in 440
syphilitic, 441
- telangiectasis 305
- teratoid tumors 358
- thoracic duct, closure of 315, 396
- throat ch. L.
- thrombophlebitis 254, 291
- thrombosis ch. II.
cardiac 253
factors in 253
from atheroma 300
in aneurysms 304
issues of 254, 255
marasmic 253, 256
of lymphatics 315
- thrombus 252
calcification of 254
mottled 252
organization of 255
red 252
softening of 254
white 252
- thrush 433, 436, 449, 479
- thymus gland, atrophy of 331
gland, lymphadenoma of 345
- Tierra del Fuego, natives of 472
- tight-lacing 482
- tinea favosa 410
furfuracea 403
sycosis 411
tonsurans 411
versicolor 412
- tonsils ch. L.
- trabecular induration of lymphatic glands 341
- trichina spiralis 479
- trichinæ in blood 265
in peritoneum 358
- trichocephalus dispar 479
- trichyphyton tonsurans 411
- tropical abscess of liver 493
- tubercle of heart 285
of liver 501
of spleen 327
in blood-vessels 264, 296
- tubercula 366, 368
- tuberculosis of intestine 475
of liver 501
of mouth 425

(The numbers refer to the articles)

- tuberculosis of mucous membranes ch. XLVII.
of pancreas 515
of serous membranes ch. XXXIII.
of throat 446
- tuberculous inflammation of vessels 296
inflammation of lymphatics 314
lymphadenitis 342
ulcer 391
- tumor-cells in blood-vessels 264, 312
in lymphatics 316
- tumors of heart 285
of intestine 478
of liver ch. LXI.
of lymphatic glands 343
of mouth 438
of mucous membranes 431
of œsophagus 451
of pancreas 515
of salivary glands 448
of serous membranes ch. XXXIV.
of spleen 329
of stomach 461
vascular 312, 504
- tylomata 394
typhlitis 471
typhoid fever 474
ulcer 474
- tyrosin in acute atrophy of liver 489, 490
in blood 259
- ulcer of the pharynx 450
of the skin 391
of the duodenum 471
of the intestine 470
of the stomach 456, 459
follicular 421, 470
rodent 402
tuberculous 428, 475
typhoid 474
- ulcerative endocarditis 282
stomatitis 434
- umbilical hernia 465
umbilication of pustules 388
- uræmia 259
uric acid in gout 259
urobilin 268
urobilinuria after hæmorrhage 349
- urticæ 366
urticaria simplex 367
tuberosa 367
- vaccinia 388
valves, deformity of 271
valvular aneurysm 282
thrombus 253
vegetations 280
- varicella 388
varicocele 306
varicose aneurysm 310
atrophy of liver 483
ulcer 306, 391
varicose ulcer of œsophagus 450
variola 387
hæmorrhagica 361, 387
pustule of 372
varix 306
aneurysmal 301, 311
false 308
vasa vasorum in organization 255
vascularization of thrombi 255
vascular mechanism Sect. II.
neoplasms 312, 504
vegetative endocarditis 280, 281
vein-stones 254, 306
venereal warts 394
venom of serpents on blood 262
venous engorgement of liver 483
engorgement of spleen 323
trunks, defects of 271
ventral hernia 465
vermiform appendage, inflammation of 471
appendage, cyst of 471
verruçæ (see warts)
vesicles 366, 370, 371
vesiculæ 368
vessels, air in 265, 266
changes in calibre of ch. XVI.
degenerations of ch. XII.
hypertrophy of 289
hypoplasia of 272, 286
inflammations of ch. XIV
rupture of ch. XVI
size of 286
wounds of 256
- vibices 361
vitiligo 365
volvulus of intestine 467
- warts, hyperplastic 398
inflammatory 394
necrogenic 390
sebaceous 400
venereal 394
warty endocarditis 280
water canker 434
waxy degeneration of heart 284
wens 399, 404
wheals 366
white blood 260
white hæmorrhage 260
whitlow 390
Wirsung, canal of 513
wounds of blood-vessels 256
- xanthelasma 401
xanthoma 401
xeroderma 364
- yellow atrophy of liver 489, 490
softening of thrombi 254
- zona 371, 383
zoster, herpes 371, 383

